

University of Groningen

Histopathology in primary Sjögren's syndrome

Haacke, Erlin

DOI:
[10.33612/diss.131461935](https://doi.org/10.33612/diss.131461935)

IMPORTANT NOTE: You are advised to consult the publisher's version (publisher's PDF) if you wish to cite from it. Please check the document version below.

Document Version
Publisher's PDF, also known as Version of record

Publication date:
2020

[Link to publication in University of Groningen/UMCG research database](#)

Citation for published version (APA):
Haacke, E. (2020). *Histopathology in primary Sjögren's syndrome: Diagnosis, clinical trials and new insights*. [Thesis fully internal (DIV), University of Groningen]. University of Groningen.
<https://doi.org/10.33612/diss.131461935>

Copyright

Other than for strictly personal use, it is not permitted to download or to forward/distribute the text or part of it without the consent of the author(s) and/or copyright holder(s), unless the work is under an open content license (like Creative Commons).

The publication may also be distributed here under the terms of Article 25fa of the Dutch Copyright Act, indicated by the "Taverne" license. More information can be found on the University of Groningen website: <https://www.rug.nl/library/open-access/self-archiving-pure/taverne-amendment>.

Take-down policy

If you believe that this document breaches copyright please contact us providing details, and we will remove access to the work immediately and investigate your claim.

Downloaded from the University of Groningen/UMCG research database (Pure): <http://www.rug.nl/research/portal>. For technical reasons the number of authors shown on this cover page is limited to 10 maximum.

**HISTOPATHOLOGY IN
PRIMARY SJÖGREN'S SYNDROME**
DIAGNOSIS, CLINICAL TRIALS
AND NEW INSIGHTS

For my beloved mother,
to cure autoimmunity

ISBN: 978-94-6416-014-7

Cover design and layout: © evelienjagtman.com

Printed by: Ridderprint

© E.A. Haacke, 2020

All rights reserved. No parts of this thesis may be reproduced, reported or transmitted, in any form or by any means, without permission of the author.



rijksuniversiteit
 groningen

HISTOPATHOLOGY IN PRIMARY SJÖGREN'S SYNDROME DIAGNOSIS, CLINICAL TRIALS AND NEW INSIGHTS

Proefschrift

ter verkrijging van de graad van doctor aan de
Rijksuniversiteit Groningen
op gezag van de
rector magnificus prof. dr. C. Wijmenga
en volgens besluit van het College voor Promoties.

De openbare verdediging zal plaatsvinden op
woensdag 9 september om 16.15 uur

door

Engel Astrid Haacke

geboren op 2 augustus 1983
te Almelo

Promotores

Prof. dr. F.G.M. Kroese

Prof. dr. H. Bootsma

Prof. dr. A. Vissink

Copromotor

Dr. B. van der Vegt

Beoordelingscommissie

Prof. dr. N.A. Bos

Prof. dr. N. de Vries

Prof. dr. C.J. van Noesel

Paranimfen

Drs. H.D. Hoving

Dr. P.M. Meiners

CONTENTS

Chapter 1: Introduction	11
<hr/>	
PART 1: Salivary gland histopathology	
Chapter 2: Parotid gland biopsy, the alternative way to diagnose Sjögren syndrome. <i>Dis Clin North Am 2016;42:485-99.</i>	27
Chapter 3: Identification of germinal centres in salivary gland biopsies	
3a: Need for consensus guidelines to standardise the assessment of germinal centres and other histopathological parameters in salivary gland tissue of patients with primary Sjögren's syndrome. <i>Ann Rheum Dis 2016;75:e32.</i>	47
3b: Standardisation of the detection of germinal centres in salivary gland biopsies of patients with primary Sjögren's syndrome is needed to assess their clinical relevance <i>Ann Rheum Dis 2018;77:e32.</i>	55
3c: Bcl6 for identification of germinal centres in salivary gland biopsies in primary Sjögren's syndrome. <i>Oral Dis. 2020;26;707-710.</i>	63
<hr/>	
PART 2: Germinal centres and MALT lymphoma in biopsies of primary Sjögren's syndrome patients	
Chapter 4: FcRL4 ⁺ B-cells in salivary glands of primary Sjögren's syndrome patients. <i>J Autoimmun 2017;81:90-98.</i>	77
Chapter 5: Presence of intraepithelial B-lymphocytes is associated with the formation of lymphoepithelial lesions in salivary glands of primary Sjögren's syndrome patients. <i>Clin Exp Rheumatol 2019;37 Suppl 118(3):42-48.</i>	101
Chapter 6: Germinal centres are not predictive for non-Hodgkin's lymphoma	
6a: Germinal centres in diagnostic labial gland biopsies of patients with primary Sjögren's syndrome are not predictive for parotid MALT lymphoma development. <i>Ann Rheum Dis 2017;76:1781-84.</i>	115
6b: Germinal centres in diagnostic biopsies of pSS patients are not a risk factor for non-Hodgkin's lymphoma but a reflection of high disease activity. <i>Arthritis Rheumatol 2019;71:170-71.</i>	129
<hr/>	

PART 3: Histopathological changes after biological treatment

Chapter 7:	Changes in parotid gland histopathology of pSS patients after rituximab treatment	
7a:	Towards personalized treatment in primary Sjögren's syndrome: baseline parotid histopathology predicts responsiveness to rituximab treatment. <i>Ann Rheum Dis 2016;75:1933-38.</i>	137
7b:	In primary Sjögren's syndrome high absolute numbers and proportions of B-cells in parotid glands predict responsiveness to rituximab as defined by ESSDAI, but not by SSRI. <i>Ann Rheum Dis 2016;75:e34.</i>	155
Chapter 8:	Abatacept treatment in primary Sjögren's syndrome results in a decrease of germinal centres in salivary gland tissue. <i>Clin Exp Rheumatol 2017;35:317-20.</i>	163
Chapter 9:	General discussion	
	Modified version of the review: "The role of salivary gland histopathology in primary Sjögren's syndrome: promises and pitfalls" <i>Clin Exp Rheumatol 2018;36 Suppl 112(3):222-33.</i>	177
Chapter 10:	Summary	207
Appendix:		
	Nederlandse samenvatting	217
	Dankwoord	227
	Curriculum vitae	233
	List of publications	237



CHAPTER 1

Introduction

INTRODUCTION

Primary Sjögren's syndrome (pSS) is a systemic autoimmune disease predominantly affecting adult women with a male to female ratio of 1:9. In the general population, the incidence of pSS is estimated at 3-11 per 100.000 individuals and the prevalence at 0.01% - 0.72%¹⁻⁴ The disease is characterized by chronic lymphocytic inflammation of the exocrine glands, particularly the salivary and lacrimal glands. This chronic inflammation with concomitant destruction and loss of functional glandular tissue leads to sicca complaints pSS patients most present with. Besides these characteristic dryness complaints of the eyes and mouth, pSS regularly affects other organ systems leading to a diversity of other signs and symptoms. Fatigue is one of the most important disabling complaint affecting the majority (70%) of pSS patients.^{5,6} Primary Sjögren differs from secondary Sjögren (sSS). In sSS another autoimmune disease is present, most commonly rheumatoid arthritis or systemic lupus erythematosus.⁷

Histopathology

Histopathologically, the chronic inflammation is seen as a focal lymphocytic sialadenitis. This pattern involves foci (clusters of ≥ 50 lymphocytes, Figure 1A) which are predominantly located around the striated ducts. A salivary gland biopsy is considered positive for pSS if the focus score (FS), calculated by the number of foci per 4mm² glandular parenchyma, is equal to or greater than 1.^{8,9} The strong association of the lymphocytes with the ductal epithelium is further emphasized by the formation of lymphoepithelial lesions (LELs). LELs are currently defined as a cross section of a striated duct with infiltration of lymphocytes within the contour of the basement membrane with additional hyperplasia of the epithelial cell lining (Figure 1B).¹⁰ These LELs are a characteristic feature in the salivary gland biopsies of pSS patients.^{9,11}

Besides foci and LELs, a relative increase in IgG expressing plasma cells and thus a relative decrease in IgA expressing plasma cells is a distinctive feature of pSS related histopathology. The relative decrease of IgA expressing plasma cells is due to the influx or local production of mainly IgG and to a lesser extend IgM expressing plasma cells (Figure 1C).^{12,13} The threshold value for pSS was set by Bodeutsch et al.¹⁴ at $\leq 70\%$ IgA expressing plasma cells in labial gland biopsies. This relative decrease in IgA expressing plasma cells appeared to be more sensitive and more disease specific than the FS in labial gland biopsies.¹⁴⁻¹⁶ In parotid gland biopsies, routinely taken at the University Medical Center Groningen (UMCG), the percentages of IgA, IgG and IgM expressing plasma cells are examined (besides FS and LELs) as well. Although not validated yet, the same threshold value of $\leq 70\%$ IgA expressing plasma cells is used for parotid gland biopsies.

Another histopathological feature which can be found in about a quarter of the salivary gland biopsies of pSS patients are germinal centers (GCs), developing within the lymphoid infiltrates.¹⁷ Although GCs are not considered a diagnostic feature,⁹ pSS patients who exhibit GCs in their labial salivary gland biopsy are characterized by a more active disease as reflected by higher FS, more frequent expression of auto-antibodies and the presence of higher levels of pro-inflammatory cytokines and chemokines.¹⁷

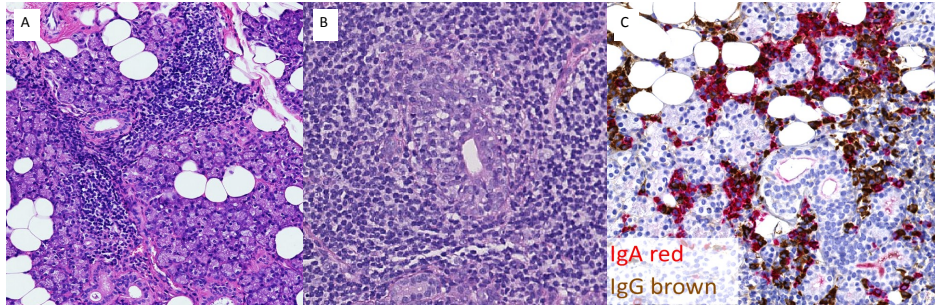


Figure 1: Histopathological changes in parotid gland biopsies of pSS patients.

The examples are all from parotid gland tissue. A) Periductal focus surrounded by unaffected parenchyma. B) Centrally located duct forming a lymphoepithelial lesion (LEL) within a focus. C) Dual staining for IgA and IgG expressing plasma cells, showing a decrease of <70% IgA expressing plasma cells. Figure from Kroese, Haacke et al.⁹

B-cell hyperactivity

The immunopathogenesis of pSS is complex and not fully elucidated. The assumption is that (T-cell dependent) B-cell hyperactivity plays a major role in pSS development. This B-cell hyperactivity is amongst others reflected in pSS by elevated serum levels of IgG, the presence of autoantibodies (SSA/Ro, SSB/La, rheumatoid factor) and increased levels of B-cell associated cytokines and chemokines.¹⁸ The many pathways involved in B-cell hyperactivity of pSS patients are all possible targets for treatment.

The initial trigger for the auto-immune inflammatory response seen in pSS is not known, although it is presumed that activation of the ductal epithelial cells (through Toll-like receptors, by virus particles¹⁹) leads to the production of type I interferons (IFN), IL6, BAFF and pro-inflammatory cytokines and chemokines, eventually leading to B-cell activation and proliferation.^{20,21}

The inflammation of salivary glands starts with an influx of (predominantly activated CD4⁺) T-cells. The cells are mainly attracted through their CXCR3 receptor towards the glands by the chemokine CXCL10. The expression of CXCL10 by the epithelial cells, fibroblasts and monocytes is driven by IFN.²² Indeed, early pSS patients show the highest levels of CXCL10 in their saliva.²³ As (activated and memory) B-cells and plasma cells also

can express CXCR3, a portion of B-cells can be attracted towards the salivary gland by this pathway.²⁴ At later stages, other (non-CXCR3-expressing) B-cells are also recruited to the salivary glands of pSS patients by the chemokine CXCL13 through binding to their chemokine receptor CXCR5. Also this chemokine is increased in the salivary glands, saliva and tears of pSS patients.²⁵ In addition to T- and B-cells, also non-lymphoid cells (myeloid and plasmacytoid dendritic cells and FDCs) are found in the glandular infiltrates. Thus, all components for the formation of ectopic lymphoid tissue are present.

MALT lymphoma

The B-cell hyperactivity is further illustrated by the presence of clonally expanded B-cells and plasma cells within the salivary glands of pSS patients.^{26,27} Neoplastic transformation of these clonal B-cells can occur, leading to malignant non-Hodgkin's lymphomas (NHL). This serious complication of pSS develops in 5-10% of pSS patients. The lymphomas that develop are predominantly of the mucosa-associated lymphoid tissue (MALT) type.^{18,28-30} The preferential location of these lymphomas is the parotid gland. These parotid MALT lymphomas are considered to be indolent neoplasia, but progression to an aggressive diffuse large B-cell lymphoma (DLBCL) may occur.³¹ Clinical and laboratory markers to identify pSS patients at risk for lymphoma development are, amongst others, high disease activity, purpura, lymphadenopathy, persistent parotid enlargement, Raynaud phenomenon, low C4, anti-SSA and/or rheumatoid factor positivity and the presence of cryoglobulin and aberrant free κ/λ light chain ratio's.³²⁻³⁷ Nevertheless, a substantial portion (31%) of the pSS associated MALT lymphomas is detected by a parotid gland biopsy during the standard diagnostic work-up for pSS at the UMCG, without any clinical suspicion.³⁸ Currently, there are discrepant data whether GCs in labial gland biopsies are also a risk factor for non-Hodgkin's lymphoma (NHL) development in pSS patients.^{9,39,40}

Diagnosis of pSS

The most common and classic complaints in pSS are keratoconjunctivitis and xerostomia.⁴¹ In about half of the pSS patients extra glandular manifestations are also present, which can affect most organ systems.⁴² Disease activity of pSS patients can be assessed by the EULAR-Sjögren's Syndrome Disease Activity Index (ESSDAI). The ESSDAI encompasses 12 domains (cutaneous, respiratory, renal, articular, muscular, peripheral nervous system, central nervous system, hematological, glandular, constitutional, lymphadenopathic, biological) which are scored separately. The sum of this score distinguishes pSS patients with a low disease activity (ESSDAI<5), moderate disease activity (5≤ESSDAI≤13) and a high disease activity (ESSDAI≥14).^{43,44}

Furthermore, the majority of pSS patients experience fatigue besides sicca complaints, which reduces their quality of life.^{45,46} The wide variety of complaints in pSS patients makes the diagnosis of pSS challenging. For classifying patients as pSS or non-pSS, the American

College of Rheumatology/European League Against Rheumatology (ACR-EULAR) criteria are currently leading (Table 1).⁴⁷ In these classification criteria, the presence of auto-antibodies against SSA and/or a positive salivary gland biopsy (FS \geq 1) are major items. The prominent position of the salivary gland biopsy makes uniform and precise histopathological evaluation crucial. Without a positive biopsy or auto-antibodies against SSA, a patient cannot be classified as pSS. One should keep in mind that these criteria are *classification* criteria and that each individual patient should be carefully and thoroughly examined by an experienced rheumatologist and other specialists such as ophthalmologists, specialists in oral medicine, and oral and maxillofacial surgeons to give a correct *diagnosis* of pSS. In other words, a patient cannot match classification criteria, but can clinically still be diagnosed as suffering from pSS. The diversity of the symptoms in pSS patients combined with the slow onset of complaints may cause delay in the diagnosis of pSS. An early diagnosis is important for pSS patients to start early treatment to prevent complications of the disease.⁴⁸

Treatment of pSS

Until recently, therapy with traditional disease-modifying anti-rheumatic drugs (DMARDs) showed limited results and treatment of pSS patients was mainly focused upon reducing dryness complaints.^{49,50} With the progress of knowledge of the immunopathogenesis of pSS, new targets for treatment and intervention have emerged. Today, there are many specific drugs influencing the pathogenesis of pSS and most (experimental) medications target the B-cells or signaling pathways involved in the formation, activation and expansion of (auto-reactive) B-cells. Various biological DMARDs are currently tested and numerous trials are running.⁵¹ For the primary endpoints of these biological therapeutics in pSS patients, the ESSDAI or the Sjögren's Syndrome Response Index (SSRI) are frequently used.⁵²⁻⁵⁵

An open label study with Epratuzumab (anti-CD22) showed an improvement in fatigue VAS, Schirmer test and stimulated whole saliva flow.⁵⁶ CD22 is a receptor on B-cells, and binding of Epratuzumab to these receptors could lead to less B-cell activation and downregulation of the B-cell receptor. Belimumab targets the B-cells by binding to soluble BAFF (BLyS) preventing the interaction of BAFF to its receptors on B-cells. In this manner the survival of B-cells, their maturation and differentiation towards immunoglobulin secreting plasma is hindered.^{57,58} BAFF is amongst others expressed by salivary gland ductal cells, B- and T-cells, dendritic cells and levels of BAFF in serum of pSS patients correlate with auto-antibody production.⁵⁹⁻⁶² Treatment of patients with anti-BAFF (BELISS open-label phase II study) showed a response in 60% (18/30) of pSS patients based upon the SSRI-30 (Sjögren's Syndrome Responder Index-30) and 15/30 (50%) upon ESSDAI \geq 3 points at week 28.⁶³ Directly targeting B-cells and as a consequence B-cell hyperactivity is rituximab (anti-CD20). Rituximab binds to CD20⁺ pre- and mature B-cells resulting in depletion of B-cells. Plasma cells are not targeted due to their lack of CD20 expression.⁶⁴ In pSS patients treatment with rituximab showed variability in efficacy. Although minor

trials were successful,^{65,66} two major placebo-controlled randomized controlled trials (RCT) with rituximab did not meet their primary endpoint.^{67,68} However, these negative results cannot disregard that treatment with rituximab showed beneficial effects on B-cell activity, fatigue, extra glandular symptoms and restoration of the glandular epithelium in the parotid glands.^{69,70}

Table 1: ACR-EULAR classification criteria for pSS

American College of Rheumatology/European League Against Rheumatism (ACR-EULAR) classification criteria for primary Sjögren's syndrome: The classification of primary Sjögren's syndrome (SS) applies to any individual who meets the inclusion criteria,* does not have any of the conditions listed as exclusion criteria,† and has a score of ≥ 4 when the weights from the five criteria items below are summed. *From the publication of Shiboski et al.⁴⁷*

Item	Weight /score
Labial salivary gland with focal lymphocytic sialadenitis and focus score of ≥ 1 foci/4 mm [‡]	3
Anti-SSA/Ro-positive	3
Ocular Staining Score ≥ 5 (or van Bijsterveld score ≥ 4) in at least one eye§¶	1
Schirmer's test ≤ 5 mm/5 min in at least one eye§	1
Unstimulated whole saliva flow rate ≤ 0.1 mL/min§**	1

*These inclusion criteria are applicable to any patient with at least one symptom of ocular or oral dryness, defined as a positive response to at least one of the following questions:

- 1) Have you had daily, persistent, troublesome dry eyes for more than 3 months?
- 2) Do you have a recurrent sensation of sand or gravel in the eyes?
- 3) Do you use tear substitutes more than three times a day?
- 4) Have you had a daily feeling of dry mouth for more than 3 months?
- 5) Do you frequently drink liquids to aid in swallowing dry food?

Or in whom there is suspicion of Sjögren's syndrome (SS) from the European League Against Rheumatism SS Disease Activity Index (ESSDAI) questionnaire (at least one domain with a positive item).

†Exclusion criteria include prior diagnosis of any of the following conditions, which would exclude diagnosis of SS and participation in SS studies or therapeutic trials because of overlapping clinical features or interference with criteria tests:

- 1) History of head and neck radiation treatment,
- 2) Active hepatitis C infection (with confirmation by PCR),
- 3) AIDS,
- 4) Sarcoidosis,
- 5) Amyloidosis,
- 6) Graft-versus-host disease,
- 7) IgG4-related disease.

‡The histopathologic examination should be performed by a pathologist with expertise in the diagnosis of focal lymphocytic sialadenitis and focus score count, using the protocol described by Daniels et al.⁷⁴

§Patients who are normally taking anticholinergic drugs should be evaluated for objective signs of salivary hypofunction and ocular dryness after a sufficient interval without these medications in order for these components to be a valid measure of oral and ocular dryness.

¶Ocular Staining Score described by Whitcher et al.⁷⁵ van Bijsterveld score described by van Bijsterveld.⁷⁶

**Unstimulated whole saliva flow rate measurement described by Navazesh and Kumar.⁷⁷

Another biological DMARD is abatacept, which blocks CD28-mediated co-stimulation of T-cells. In a phase II open label trial of 15 pSS patients, abatacept showed clinical efficacy based upon decline in ESSDAI of 3 or more points.⁶⁶ Machado et al.⁷¹ confirmed a decline in ESSDAI after 24 months of abatacept treatment in a prospective observational study. Unfortunately, a placebo-controlled RCT showed no significant change in ESSDAI was seen after 24 weeks of treatment, although a significant change in ESSDAI was present at week 12 (van Nimwegen et al., manuscript accepted for publication in Rheumatology). A second multicenter trial showed similar results, no significant decrease was seen in ESSDAI at day 169 (± 24 weeks).⁷²

Although B-cell hyperactivity is a hallmark in pSS pathogenesis, the described B-cell targeted therapies do not fully resolve pSS related complaints in all pSS patients. The population of pSS patients is diverse and within clinical trials subgroups of pSS do benefit from the given therapy. The focus should therefore not be solely on pSS patients in general, but more on personalized medicine: which pSS patients benefit from which specific treatment options.

Regardless whether the primary endpoint of a clinical trial is reached, pre-, and post-treatment salivary gland biopsies may provide insight in the pathogenesis of pSS. Furthermore, standardized histopathological evaluation of biopsies may provide rationale for effectiveness based treatment decisions, which may eventually lead to personalized treatment of pSS patients.

Scope of the thesis

The overall theme of this thesis is salivary gland histopathology in pSS patients.

Part 1: Salivary gland histopathology

To diagnose pSS, a salivary gland biopsy is routinely taken. Traditionally a labial gland biopsy is performed and this is still common practice in most hospitals these days. In **chapter 2** we present the parotid gland biopsy as an alternative to the labial gland biopsy. The histopathological evaluation is the same for the labial and parotid gland biopsy. For both these biopsies, there is disagreement in the literature on how to detect glandular GCs. In **chapters 3a, 3b and 3c** the optimal method for GC detection is assessed. The recognition of GCs can be difficult on general HE-stained sections. GCs can be easily overlooked and occluded LELs can be mistaken for GCs. We investigated whether additional immunohistochemical markers, such as BCL6, can aid in the correct detection of GCs. Furthermore, it is advocated in these chapters that uniformity of the detection of GCs is needed to assess their clinical relevance.

Part 2: Germinal centers and MALT lymphoma in biopsies of primary Sjögren's syndrome patients

Patients with pSS are at risk for developing NHL, especially low grade MALT lymphomas located within the parotid glands. Falini et al.⁷³ demonstrated that marginal zone lymphomas and a subset of DLBCL express FcRL4. In **chapter 4** we investigated whether also pSS associated parotid MALT lymphomas express FcRL4. The expression of FcRL4 within the salivary gland tissue (parotid and labial) of non-lymphomas pSS patients was further examined and the hypothesis that FcRL4⁺ B-cells play a major part in pSS lymphomagenesis is discussed.

In **chapter 5** the association of intra-epithelial B-lymphocytes in the formation of LELs is explored. In this study the number of B-cells and B-cell/T-cell ratio in the striated ducts of labial and parotid gland biopsies taken from pSS and non-pSS sicca patients is scored and correlated with the severity of the LELs.

The predictive value of GCs in labial gland biopsies, specifically for parotid MALT lymphoma development, is examined in **chapter 6a**. In this study the presence of GCs in diagnostic biopsies taken prior to lymphoma development are compared with the presence of GCs in a matched control cohort with a long lymphoma free follow-up. In **chapter 6b** the occurrence of GCs in biopsies taken prior to NHL in general, including MALT lymphomas is further explored in relation to disease activity of pSS patients.

Part 3: Histopathological changes after biological treatment

Treatment of pSS patients with biological DMARDs shows promising clinical effects. As the salivary glands are the prime targets of the autoimmune inflammatory process, the changes within the glandular tissue are important in assessing the results of these treatment options. In **chapter 7a** the effect of rituximab treatment on the glandular tissue of the parotid gland is analyzed, and possible histopathological markers to predict responsiveness to rituximab treatment are presented. In **chapter 7b** the use of different clinical outcome measures (ESSDAI vs SSRI) and different methods of histopathological assessment in clinical trials with rituximab in pSS patients are analyzed. In **chapter 8**, the effect of blocking T-cell dependent B-cell activation by abatacept treatment on the parotid gland histopathology in pSS patients is assessed.

General discussion

The importance of salivary gland histopathology in pSS patients is discussed in **chapter 9**. This chapter describes the role of histopathology as a diagnostic tool, the role of histopathology as predictor of disease severity and lymphomagenesis with special emphasis on GCs, and the role of histopathology in evaluating clinical trials.

REFERENCES

1. Kvarnström M, Ottosson V, Nordmark B, et al. Incident cases of primary Sjögren's syndrome during a 5-year period in Stockholm County: a descriptive study of the patients and their characteristics. *Scand J Rheumatol* 2015;44:135-42.
2. Weng M-Y, Huang Y-T, Liu M-F, et al. Incidence and mortality of treated primary Sjögren's syndrome in Taiwan: a population-based study. *J Rheumatol* 2011;38:706-08.
3. Maldini C, Seror R, Fain O, et al. Epidemiology of primary Sjögren's syndrome in a French multiracial/multiethnic area. *Arthritis Care Res (Hoboken)* 2014;66:454-63.
4. Kabasakal Y, Kitapcioglu G, Turk T, et al. The prevalence of Sjögren's syndrome in adult women. *Scand J Rheumatol*. 2006;35(5):379-83.
5. Ng W-F, Bowman SJ. Primary Sjögren's syndrome: too dry and too tired. *Rheumatology (Oxford)* 2010;49:844-53.
6. Miyamoto ST, Lendrem DW, Ng W-F, et al. Managing fatigue in patients with primary Sjögren's syndrome: challenges and solutions. *Open Access Rheumatol Res Rev* 2019; 11:77-88.
7. Stefanski A-L, Tomiak C, Pleyer U, et al. The Diagnosis and Treatment of Sjögren's Syndrome. *Dtsch Arzteblatt Online* 2017;114:354-61.
8. Chisholm DM, Mason DK. Labial salivary gland biopsy in Sjögren's disease. *J Clin Pathol* 1968;21:656-60.
9. Kroese FGM, Haacke EA, Bombardieri M. The role of salivary gland histopathology in primary Sjögren's syndrome: promises and pitfalls. *Clin Exp Rheumatol* 2018;36:222-33.
10. van Ginkel MS, Haacke EA, Bootsma H, et al. Presence of intraepithelial B-lymphocytes is associated with the formation of lymphoepithelial lesions in salivary glands of primary Sjögren's syndrome patients. *Clin Exp Rheumatol* 2019;37:42-48.
11. Ihrler S, Zietz C, Sendelhofert A, et al. Lymphoepithelial duct lesions in Sjögren-type sialadenitis. *Virchows Arch* 1999;434:315-23.
12. Szyszko EA, Brokstad KA, Øijordsbakken G, et al. Salivary glands of primary Sjögren's syndrome patients express factors vital for plasma cell survival. *Arthritis Res Ther* 2011;13:R2.
13. de Wilde PC, Vooy's GP, Baak JP, et al. Quantitative immunohistologic and histomorphometric diagnostic criteria for Sjögren's syndrome. *Pathol Res Pract* 1989;185:778-80.
14. Bodeutsch C, Kater L, Kruize AA. Quantitative immunohistologic criteria are superior to the lymphocytic focus score criterion for the diagnosis of Sjögren's syndrome. *Arthritis Rheum* 1992;35:1075-87.
15. Zandbelt MM, Wentink JRM, de Wilde PCM, et al. The synergistic value of focus score and IgA% score of sublabial salivary gland biopsy for the accuracy of the diagnosis of Sjögren's syndrome: a 10-year comparison. *Rheumatology (Oxford)* 2002;41:819-23.
16. Salomonsson S, Rozell BL, Heimbürger M, et al. Minor salivary gland immunohistology in the diagnosis of primary Sjögren's syndrome. *J Oral Pathol Med* 2009;38:282-88.
17. Risselada AP, Looije MF, Kruize AA, et al. The role of ectopic germinal centers in the immunopathology of primary Sjögren's syndrome: a systematic review. *Semin Arthritis Rheum* 2013;42:368-76.
18. Kroese FGM, Abdulahad WH, Haacke E, et al. B-cell hyperactivity in primary Sjögren's syndrome. *Expert Rev Clin Immunol* 2014;10:483-99.
19. Kivity S, Arango MT, Ehrenfeld M, et al. Infection and autoimmunity in Sjögren's syndrome: A clinical study and comprehensive review. *J Autoimmun* 2014;51:17-22.
20. Pollard RPE, Abdulahad WH, Bootsma H, et al. Predominantly proinflammatory cytokines decrease after B cell depletion therapy in patients with primary Sjögren's syndrome. *Ann Rheum Dis* 2013;72:2048-50.
21. Kroese FGM, Verstappen GM, de Leeuw K, et al. Sjögren's syndrome, should we sign? *Expert Rev Clin Immunol* 2016;12:365-67.
22. Ogawa N, Ping L, Zhenjun L, et al. Involvement of

- the interferon-gamma-induced T cell-attracting chemokines, interferon-gamma-inducible 10-kd protein (CXCL10) and monokine induced by interferon-gamma (CXCL9), in the salivary gland lesions of patients with Sjögren's syndrome. *Arthritis Rheum* 2002;46:2730-41.
23. Hernández-Molina G, Michel-Peregrina M, Hernández-Ramírez DF, et al. Chemokine saliva levels in patients with primary Sjögren's syndrome, associated Sjögren's syndrome, pre-clinical Sjögren's syndrome and systemic autoimmune diseases. *Rheumatology (Oxford)* 2011;50:1288-92.
 24. Muehlinghaus G, Cigliano L, Huehn S, et al. Regulation of CXCR3 and CXCR4 expression during terminal differentiation of memory B cells into plasma cells. *Blood* 2005;105:3965-71.
 25. Ambrus JL, Suresh L, Peck A, et al. Multiple Roles for B-Lymphocytes in Sjogren's Syndrome. *J Clin Med* 2016;5:e87.
 26. Visser A, Doorenspleet ME, de Vries N, et al. Acquisition of N-Glycosylation Sites in Immunoglobulin Heavy Chain Genes During Local Expansion in Parotid Salivary Glands of Primary Sjögren Patients. *Front Immunol* 2018;9 :491.
 27. Quartuccio L, Salvin S, Fabris M, et al. BLYS upregulation in Sjogren's syndrome associated with lymphoproliferative disorders, higher ESSDAI score and B-cell clonal expansion in the salivary glands. *Rheumatology* 2013;52:276-81.
 28. Giannouli S, Voulgarelis M. Predicting progression to lymphoma in Sjögren's syndrome patients. *Expert Rev Clin Immunol* 2014;10:501-12.
 29. Voulgarelis M, Ziakas PD, Papageorgiou A, et al. Prognosis and outcome of non-Hodgkin lymphoma in primary Sjögren syndrome. *Medicine (Baltimore)* 2012;91:1-9.
 30. Nocturne G, Boudaoud S, Miceli-Richard C, et al. Germline and somatic genetic variations of TNFAIP3 in lymphoma complicating primary Sjogren's syndrome. *Blood* 2013;122:4068-76.
 31. Isaacson PG, Norton AJ. *Extranodal Lymphomas*. Churchill Livingstone; 1994.
 32. Fragkioudaki S, Mavragani CP, Moutsopoulos HM. Predicting the risk for lymphoma development in Sjogren syndrome: An easy tool for clinical use. *Medicine (Baltimore)* 2016;95:e3766.
 33. Baimpa E, Dahabreh IJ, Voulgarelis M, et al. Hematologic manifestations and predictors of lymphoma development in primary Sjögren syndrome: clinical and pathophysiologic aspects. *Medicine (Baltimore)* 2009;88:284-93.
 34. Nocturne G, Virone A, Ng W-F, et al. Rheumatoid Factor and Disease Activity Are Independent Predictors of Lymphoma in Primary Sjögren's Syndrome. *Arthritis Rheumatol (Hoboken, NJ)* 2016;68:977-85.
 35. Verstappen GMP, Moerman R V, van Nimwegen JF, et al. Serum immunoglobulin free light chains are sensitive biomarkers for monitoring disease activity and treatment response in primary Sjögren's syndrome. *Rheumatology* 2018;57:1812-21.
 36. Nishishinya MB, Pereda CA, Muñoz-Fernández S, et al. Identification of lymphoma predictors in patients with primary Sjögren's syndrome: a systematic literature review and meta-analysis. *Rheumatol Int* 2015;35:17-26.
 37. Delli K, Villa A, Farah CS, et al. World Workshop on Oral Medicine VII: Biomarkers predicting lymphoma in the salivary glands of patients with Sjögren's syndrome-A systematic review. *Oral Dis* 2019;25:49-63.
 38. Pollard RPE, Pijpe J, Bootsma H, et al. Treatment of mucosa-associated lymphoid tissue lymphoma in Sjogren's syndrome: a retrospective clinical study. *J Rheumatol* 2011;38:2198-2208.
 39. Haacke EA, van der Vegt B, Vissink A, et al. Germinal centres in diagnostic labial gland biopsies of patients with primary Sjögren's syndrome are not predictive for parotid MALT lymphoma development. *Ann Rheum Dis* 2017;76:1781-84.
 40. Theander E, Vasaitis L, Baecklund E, et al. Lymphoid organisation in labial salivary gland biopsies is a possible predictor for the development of malignant lymphoma in primary Sjögren ' s syndrome. *Ann Rheum Dis* 2011;161:1363-68.
 41. Fox RI. Sjögren's syndrome. *Lancet (London, England)* 2005;366:321-31.
 42. Flores-Chávez A, Kostov B, Solans R, et al. Severe,

- life-threatening phenotype of primary Sjögren's syndrome: clinical characterisation and outcomes in 1580 patients (GEAS-SS Registry). *Clin Exp Rheumatol* 2018;112:121-29.
43. Seror R, Bootsma H, Saraux A, et al. Defining disease activity states and clinically meaningful improvement in primary Sjögren's syndrome with EULAR primary Sjögren's syndrome disease activity (ESSDAI) and patient-reported indexes (ESSPRI). *Ann Rheum Dis* 2016;75:382-89.
 44. Seror R, Bowman SJ, Brito-Zeron P, et al. EULAR Sjögren's syndrome disease activity index (ESSDAI): a user guide. *RMD Open* 2015;1:e000022.
 45. Meijer JM, Meiners PM, Huddleston Slater JJR, et al. Health-related quality of life, employment and disability in patients with Sjögren's syndrome. *Rheumatology* 2009;48:1077-82.
 46. Lackner A, Ficjan A, Stradner MH, et al. It's more than dryness and fatigue: The patient perspective on health-related quality of life in Primary Sjögren's Syndrome - A qualitative study. O'Connor B, ed. *PLoS One*. 2017;12:e0172056.
 47. Shiboski CH, Shiboski SC, Seror R, et al. 2016 American College of Rheumatology/European League Against Rheumatism classification criteria for primary Sjögren's syndrome. *Ann Rheum Dis* 2017;76:9-16.
 48. Kassan SS, Moutsopoulos HM. Clinical Manifestations and Early Diagnosis of Sjögren Syndrome. *Arch Intern Med*. 2004;164:1275.
 49. Verstappen GM, Kroese FG, Vissink A, et al. Pharmacotherapy for managing extraglandular symptoms of primary Sjögren's syndrome. *Expert Opin Orphan Drugs* 2015;3:125-39.
 50. Ramos-Casals M, Brito-Zerón P, Bombardieri S, et al. EULAR recommendations for the management of Sjögren's syndrome with topical and systemic therapies. *Ann Rheum Dis* 2020;79:3-18.
 51. Nocturne G, Cornec D, Seror R, et al. Use of Biologics in Sjögren's Syndrome. *Rheum Dis Clin North Am* 2016;42:407-17.
 52. Seror R, Theander E, Brun JG, et al. Validation of EULAR primary Sjögren's syndrome disease activity (ESSDAI) and patient indexes (ESSPRI). *Ann Rheum Dis* 2015;74:859-66.
 53. Seror R, Bootsma H, Saraux A, et al. Defining disease activity states and clinically meaningful improvement in primary Sjögren's syndrome with EULAR primary Sjögren's syndrome disease activity (ESSDAI) and patient-reported indexes (ESSPRI). *Ann Rheum Dis*.2016;75:382-89.
 54. Cornec D, Devauchelle-Pensec V, Mariette X, et al. Development of the Sjögren's Syndrome Responder Index, a data-driven composite endpoint for assessing treatment efficacy. *Rheumatology (Oxford)* 2015;54:1699-1708.
 55. Seror R, Meiners P, Baron G, et al. Development of the ClinESSDAI: a clinical score without biological domain. A tool for biological studies. *Ann Rheum Dis* 2016;75:1945-50.
 56. Steinfeld SD, Tant L, Burmester GR, et al. Epratuzumab (humanised anti-CD22 antibody) in primary Sjögren's syndrome: an open-label phase I/II study. *Arthritis Res Ther* 2006;8:R129.
 57. Groom J, Kalled SL, Cutler AH, et al. Association of BAFF/BLyS overexpression and altered B cell differentiation with Sjögren's syndrome. *J Clin Invest* 2002;109:59-68.
 58. Schneider P, MacKay F, Steiner V, et al. BAFF, a novel ligand of the tumor necrosis factor family, stimulates B cell growth. *J Exp Med* 1999;189:1747-56.
 59. Kalled SL. The role of BAFF in immune function and implications for autoimmunity. *Immunol Rev* 2005;204:43-54.
 60. Ittah M, Miceli-Richard C, Eric Gottenberg J, et al. B cell-activating factor of the tumor necrosis factor family (BAFF) is expressed under stimulation by interferon in salivary gland epithelial cells in primary Sjögren's syndrome. *Arthritis Res Ther*. 2006;8:R51.
 61. Mariette X, Roux S, Zhang J, et al. The level of BLyS (BAFF) correlates with the titre of autoantibodies in human Sjögren's syndrome. *Ann Rheum Dis* 2003;62:168-71.
 62. Thompson N, Isenberg DA, Jury EC, et al. Exploring BAFF: its expression, receptors and contribution to the immunopathogenesis of Sjögren's syndrome. *Rheumatology* 2016;55:1548-55.
 63. Mariette X, Seror R, Quartuccio L, et al. Efficacy and safety of belimumab in primary Sjögren's

- syndrome: results of the BELISS open-label phase II study. *Ann Rheum Dis* 2015;74:526-31.
64. Schioppo T, Ingegnoli F. Current perspective on rituximab in rheumatic diseases. *Drug Des Devel Ther.* 2017; 11:2891-04.
 65. Adler S, Korner M, Forger F, et al. Evaluation of histological, serological and clinical changes in response to abatacept treatment of primary Sjögren's syndrome: A pilot study. *Arthritis Care Res (Hoboken)* 2013;65:1862-68.
 66. Meiners PM, Vissink A, Kroese FGM, et al. Abatacept treatment reduces disease activity in early primary Sjögren's syndrome (open-label proof of concept ASAP study). *Ann Rheum Dis* 2014;73:1393-96.
 67. Devauchelle-Pensec V, Mariette X, Jousse-Joulin S, et al. Treatment of Primary Sjögren Syndrome With Rituximab. *Ann Intern Med* 2014;160:233-42.
 68. Bowman SJ, Everett CC, O'Dwyer JL, et al. Randomized Controlled Trial of Rituximab and Cost-Effectiveness Analysis in Treating Fatigue and Oral Dryness in Primary Sjögren's Syndrome. *Arthritis Rheumatol* 2017;69:1440-50.
 69. Verstappen GM, van Nimwegen JF, Vissink A, et al. The value of rituximab treatment in primary Sjögren's syndrome. *Clin Immunol* 2017;182:62-71.
 70. Pijpe J, Meijer JM, Bootsma H, et al. Clinical and histologic evidence of salivary gland restoration supports the efficacy of rituximab treatment in Sjögren's syndrome. *Arthritis Rheum* 2009;60:3251-56.
 71. Machado AC, Dos Santos LC, Fidelix T, et al. Effectiveness and safety of abatacept for the treatment of patients with primary Sjögren's syndrome. *Clin Rheumatol* 2020;39:243-48.
 72. Baer AN, Gottenberg J-E, St Clair EW, et al. Efficacy and safety of abatacept in active primary Sjögren's syndrome: results of a randomised placebo-controlled phase III trial. *Ann Rheum Dis* 2019;78:89-90.
 73. Falini B, Agostinelli C, Bigerna B, et al. IRTA1 is selectively expressed in nodal and extranodal marginal zone lymphomas. *Histopathology* 2012;61:930-41.
 74. Daniels TE, Cox D, Shiboski CH, et al. Associations between salivary gland histopathologic diagnoses and phenotypic features of Sjögren's syndrome among 1,726 registry participants. *Arthritis Rheum* 2011;63:2021-30.
 75. Whitcher JP, Shiboski CH, Shiboski SC, et al. A simplified quantitative method for assessing keratoconjunctivitis sicca from the Sjögren's Syndrome International Registry. *Am J Ophthalmol.* 2010;149:405-15.
 76. van Bijsterveld OP. Diagnostic tests in the Sicca syndrome. *Arch Ophthalmol (Chicago, Ill 1960)* 1969;82:10-14.
 77. Navazesh M, Kumar SKS, University of Southern California School of Dentistry. Measuring salivary flow: challenges and opportunities. *J Am Dent Assoc* 2008;139:355-405.





PART 1

Salivary gland
histopathology



CHAPTER 2

Parotid gland biopsy, the alternative way to diagnose Sjögren syndrome

Fred KL Spijkervet¹
Erlin A Haacke^{2,3}
Frans GM Kroese²
Hendrika Bootsma²
Arjan Vissink¹

Department of ¹Oral and Maxillofacial Surgery, ²Rheumatology & Clinical Immunology,
³Pathology and Medical Biology, University of Groningen, University Medical Center
Groningen, the Netherlands

Modified version of: Rheum Dis Clin North Am 2016;42:485-99.

SYNOPSIS

Salivary gland biopsy is a technique broadly applied for the diagnosis of Sjögren's syndrome (SS), lymphoma in SS, and connective tissue disorders (sarcoidosis, amyloidosis). In SS characteristic histology findings are found including lymphocytic infiltration surrounding the excretory ducts in combination with destruction of acinar tissue. In this article the main techniques are described for taking labial and parotid salivary gland biopsies with respect to their advantages, postoperative complications and usefulness for diagnostic procedures, monitoring disease progression and evaluation of treatment.

KEY POINTS

- In Sjögren's diagnostics, parotid gland incision biopsies can overcome most disadvantages of minor salivary gland excision biopsies.
- Sensitivity and specificity of parotid and minor salivary gland biopsies for diagnosing Sjögren's syndrome are comparable.
- Lymphoepithelial lesions and early stage lymphomas are easier to detect in parotid gland tissue of patients with Sjögren's syndrome.
- In contrast to minor salivary glands, repeated biopsies of the same parotid gland are possible, which is an important asset in monitoring disease progression as well as in studying the efficacy of treatment at a glandular tissue level.
- Histopathologic results from the parotid gland can be compared with other diagnostic results derived from the same gland (sialometry sialochemistry, sialography, scintigraphy, ultrasound, CT, MRI).

INTRODUCTION

Salivary gland biopsy is a technique broadly applied in the diagnostic work-up of Sjögren's syndrome (SS) as well as lymphoma accompanying SS, sarcoidosis, amyloidosis and other connective tissue disorders. A focus score ≥ 1 per 4 mm² labial salivary gland tissue is considered as one of the four objective European-American Consensus Group classification criteria (AECG)¹ and one of the three objective American College of Rheumatology provisional classification criteria (ACR)² for SS. The focus scores reflects the number of infiltrates of ≥ 50 mononuclear inflammatory cells, predominantly lymphocytes, in a perivascular or periductal location, typically adjacent to normal acini, per 4 mm² salivary gland tissue.^{3,4} Also in the under construction consensus classification criteria of European League against Rheumatism (EULAR) and ACR, a labial focus score ≥ 1 will be maintained as a leading classification criterion.⁵

Moreover, there are views that besides being of diagnostic value, labial salivary gland biopsies also may play a role in predicting lymphoma development⁶ as well as in monitoring disease and treatment efficacy.⁷⁻⁹ Recently, Fisher et al¹⁰ reviewed the labial salivary gland pathology that characterizes SS. They concluded that labial salivary gland biopsies offer a distinct potential as a biomarker in primary SS (pSS), particularly relevant to glandular involvement, and offer additional prognostic, stratification and mechanistic insights. They also added that precise value of a labial salivary gland biopsy is yet hard to determine in the absence of proven immunomodulatory therapies in pSS as well as that further work on validation and understanding the natural history is needed.

In their review, Fisher et al¹⁰ briefly mentioned parotid biopsies as an alternative to labial salivary gland biopsies, but did not further state the advantages and disadvantages of parotid biopsies compared to labial salivary biopsies (Table 1).^{11,12} In this contribution we discuss the potential of parotid salivary gland biopsies as an alternative way to diagnose SS and also with emphasis of its added value in lymphoma diagnostics and rating disease progression and treatment efficacy.

Table 1. Techniques to perform a labial or parotid salivary gland biopsy (modified after Delli et al 2014).

Technique	
Labial gland	
Chisholm and Mason, ³ 1968	Ellipse of oral mucous membrane down to the muscle layer. Harvest of 6-8 glands. Wound closure with 04 gauge silk sutures, which must be removed after four-five days.
Greenspan et al, ¹³ 1974	1.5-2 cm linear incision of mucosa, parallel to the vermillion border and lateral to the midline
Marx et al, ¹⁸ 1988	Mucosal incision of 3x0.75 cm
Delgado and Moscuada, ¹⁹ 1989	Longitudinal incision of 1 cm in the labial mucosa in front of the mandibular cuspids
Guevara-Gutierrez et al, ⁵⁸ 2001	Punch biopsy
Mahlsted et al, ²⁰ 2002	1-1.5 cm wedge-shaped incision between the midline and commissure
Gorson and Ropper, ⁵⁹ 2003	1 cm vertical incision just behind the wet line through the mucosa and submucosa
Berquin et al, ²¹ 2006	Oblique incision, starting 1.5 cm from the midline and proceeding latero-inferiorly, avoiding the glandular free zone in the center of the lower lip
Caporali et al, ²² 2007	Small incision of 2-3 mm on the inner surface of the lower lip
Parotid gland	
Kraaijenhagen, ²⁵ 1975	1-2 cm incision just below and behind the earlobe near the posterior angle of the mandible. The skin is incised and the parotid capsule is exposed by blunt dissection. The capsule of the gland is opened and adequate amount of superficial parotid tissue is removed, approximately 5 x 5 mm. The procedure is completed with a 2 to 3-layered closure
Markx et al, ¹⁸ 1988	
McGuirt et al, ⁶⁰ 2002	
Baurmash et al, ⁶¹ 2005	
Pijpe et al, ¹¹ 2007	
Adam et al, ⁶² 1992	Mucosal incision 1 cm anterolaterally from the Whartonian duct to 1 cm anteroposteriorly. Blunt dissection and harvest of 0.5 cm ³ of glandular tissue. The wound edges are joined with 1-2 resorbable stitches
Berquin et al, ²¹ 2006	

Advantages	Complications
<ul style="list-style-type: none">• Widely distributed glands• Easily accessible glands• Minimal chance of bleeding• Germinal center like structures can be identified	<ul style="list-style-type: none">• Localized, 6 – 10 % permanent, sensory alteration of the lips and skin in the mental region• Internal scarring and cheloid formation• Suture failing
<ul style="list-style-type: none">• Presence of germinal centers• Presence of LELs• (Early) identification of MALT• The same gland can be repeatable harvested• Direct comparison with other diagnostic results derived from the same gland (e.g., secretory function, sialography, scintigraphy, ultrasound)	<ul style="list-style-type: none">• Temporary change in sensory sensation of the skin in the area of the incision• More demanding surgical expertise

MINOR SALIVARY GLAND BIOPSY

Minor salivary glands are widely distributed in the labial, buccal and palatal mucosa of the oral cavity. Since pathognomonic changes are seen in minor salivary glands, labial salivary gland biopsy is largely used for assisting the diagnosis of SS.^{4,13,14}

Surgical considerations

Minor salivary glands, and labial salivary glands in particular, are easily accessible. The labial salivary glands lie above the muscle layer and branches of the mental nerve (labial sensory nerves), and are separated from the oral mucous membrane by a thin layer of fibrous connective tissue. Although the chance of excessive bleeding is minimal, since the arterial supply to the lip lies deep, there is a serious hazard of sensory nerve injury, as the labial sensory nerves are closely associated to the minor salivary glands (Figure 1).

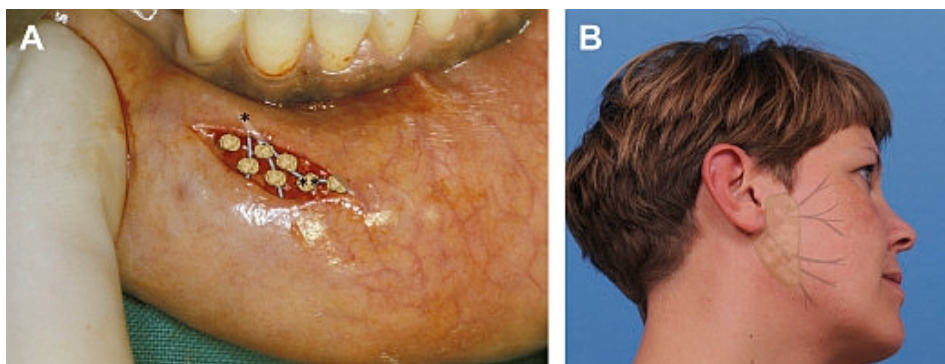


Figure 1: Association of the labial and parotid salivary glands with, respectively, the mental and facial nerve (after Delli et al 2015).

A) The mental nerve has three branches: one branch supplying the skin of the chin and two branches supplying the skin and mucous membrane of the lower lip. The branch that supplies the mucous membrane usually has two sub-branches of which the vertical one has an ascending course toward the vermillion border and is in close relation to the labial salivary glands. **B)** The facial nerve enters the parotid gland forming a characteristic branching pattern that resembles a goose foot and is known as the pes anserinus. The parotid gland is divided into a superficial and deep lobe based on the course of the facial nerve as it passes through. In the area of the incisional biopsy of the parotid gland the distance between the surface of the parotid gland and the facial nerve is approximately 1.5 – 2 cm.

Labial salivary gland biopsies in the diagnosis of SS were introduced by Chisholm and Mason.³ The biopsies involve oral preparation of the patient with local anesthetic infiltration followed by excising an ellipse of oral mucous membrane down to the muscle layer. The wound was closed with 4-0 gauge silk sutures, which were removed after 4-5 days. Ideally 6 to 8 minor glands are harvested and sent for histopathologic examination.

Several clinicians have revised the Chisholm and Mason technique. Currently, the approach of Greenspan et al¹³ and Daniels¹⁴ is mostly applied (Figure 2). This approach is described in detail on the SICCA website.¹⁵ In short, the biopsy has to be performed through the mucosa of the lower lip that appears normal clinically. After applying local anesthetics, the lip is everted to expose the mucosa. Next, a 1.0-1.5 cm horizontal incision will be made to the right or left of the midline, approximately halfway between the vestibule and the vermilion border and halfway between the midline and the labial commissure. The lamina propria is bluntly dissected to release the minor salivary glands from lamina propria beyond the incision and to bring them into the operating field. Approximately 7 minor salivary glands should be removed to provide a minimum gland section area of 8-12 mm² for microscopic focus scoring.¹⁰ Finally, the mucosal incision margins are repositioned and sutured with 5-0 rapid absorbable (polyglactin/L-lactide acid) sutures (Figure 2).

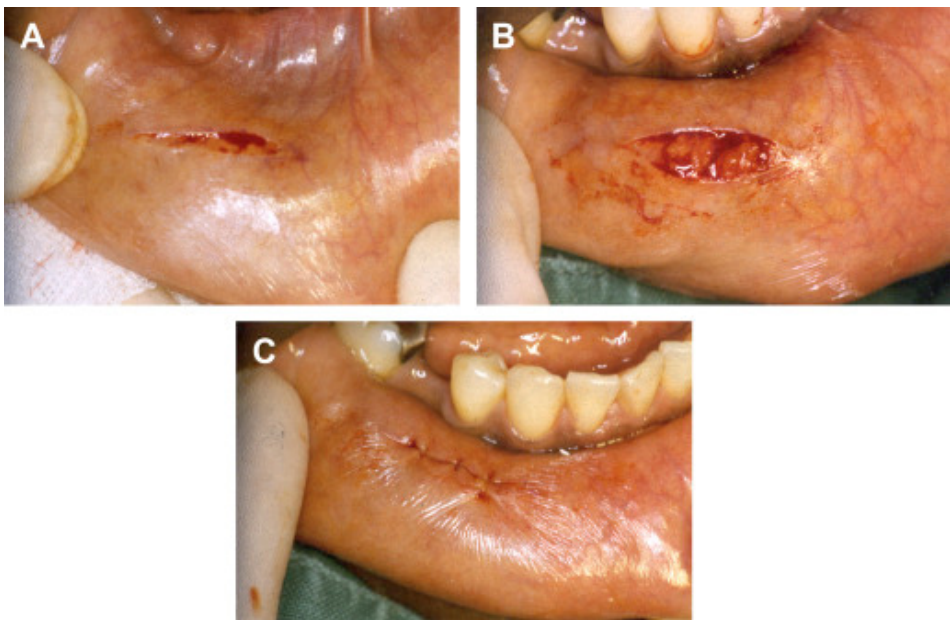


Figure 2: Technique for harvesting labial salivary glands after infiltration of local anesthesia.

A) A horizontal incision of approximately 1.0-1.5 cm is made on the mucosal site of the lip. Just the epithelium is incised. **B)** About 6-8 labial salivary glands are harvested avoiding damage to the branches of the mental nerve. **C)** Wound closure with 5-0 rapid absorbable (polyglactin/L-lactide acid) sutures; inverted buried notches.

Histologic grading

The first grading system for salivary gland biopsies was employed by Chisholm and Mason³ in an attempt to standardize the examined area and record the degree of histopathological change. At present, according to the revised AECG and provisional ACR classification criteria for SS (and also in the recent ACR-EULAR classification under construction), a labial salivary gland biopsy is considered positive if the glands (obtained through normal appearing mucosa) demonstrate focal lymphocytic sialadenitis, evaluated by an expert histopathologist, with a focus score ≥ 1 (Figure 3). Diagnosis of nonspecific chronic sialadenitis, sclerosing chronic sialadenitis and granulomatous inflammation need to be excluded. A sufficient area of labial salivary gland tissue has to be examined as El-Hashimi et al¹⁶ showed that focus score might differ on multiple sections taken from the same labial glands specimen.

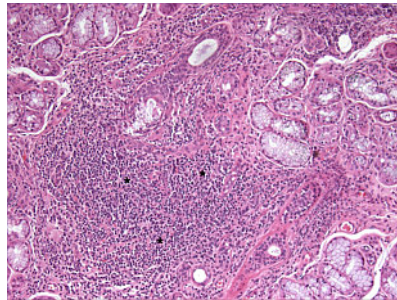


Figure 3: Histopathology of the labial salivary glands of a patient with Sjögren's syndrome which is characterized by lymphocytic infiltration (*) of the excretory ducts and destruction of the acini, and fulfilling the criterion of a focus score ≥ 1 .

Complications

Complications of labial salivary gland biopsies include localized (permanent) sensory alteration of the lip, external haematoma, local swelling, formation of granulomas, internal scarring and cheloid formation, failing sutures and local pain.^{11,13,14,17-24} The localized sensory alterations are frequently described with the terms anesthesia, reduced or partial loss of sensation, transitory numbness and hypoesthesia. These localized sensory alterations of the vermillion border of the lower lip mucosa may last for a few months, but can be permanent in up to 10 %, which should be considered as relatively high for a diagnostic procedure.^{11,18}

PAROTID GLAND BIOPSY

The parotid gland is divided into a superficial and deep lobe based on the course of the facial nerve as it passes through (Figure 1). The technique of the parotid gland biopsy was initially described by Kraaijenhagen²⁵ and modified by Pijpe et al¹¹ (Figure 4). The parotid biopsy is performed in the superficial lobe area where the facial nerve is 1.5-2 cm below the surface of the gland.

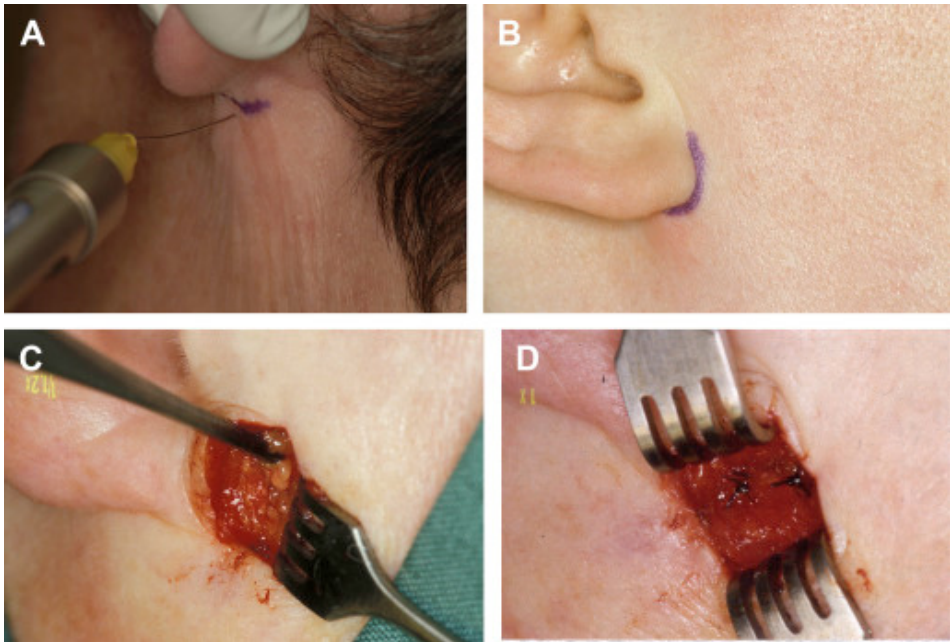


Figure 4: Technique of a parotid biopsy.

A) The skin below the ear lobe is infiltrated with local anesthesia. **B)** With a No 15 blade a small 1-2 cm incision is made just below and behind the earlobe near the posterior border of the ascending ramus of the mandible. **C)** The parotid capsule is exposed by blunt dissection after the skin incision. The capsule of the gland is carefully opened and a small amount of 5 x 5 x 5 mm superficial parotid tissue is removed. **D)** The procedure is completed with a 2 to 3-layered closure with 4-0 gauge absorbable sutures (polyglycolic acid), while the skin layer is closed with 5-0 nylon sutures.

Surgical considerations

In short, the area in the region of the earlobe is anesthetized (auriculotemporal nerve) with 0.5 ml local infiltration anesthesia followed by skin disinfection and standard preparation. With a No 15 knife-blade, a small 1-2 cm incision is made just below the earlobe near the posterior border of the mandible. The skin is incised and after blunt dissection of the subdermal tissue the parotid capsule is exposed, followed by carefully opening of

the capsule and excision of the required amount of superficial parotid gland tissue for histopathologic review. The capsule of the parotid gland and subcutaneous layer is closed with 5-0 absorbable (polyglycolic acid) sutures, whereas the skin is closed with 5-0 nylon sutures (Figure 4). With this surgical approach there are no reports on development on sialoceles or fistula. For details see the instructional film.

Histologic grading

Pijpe et al¹¹ established a new set of validated histopathological criteria for diagnosing Sjögren's syndrome in accordance with the AECG classification criteria based on biopsy of the parotid gland (Figure 5). A parotid biopsy is considered positive when it has a focus score of ≥ 1 , defined as the number of lymphocytic foci (which are adjacent to normal-appearing acini and contain >50 lymphocytes) per 4 mm² of glandular parotid tissue (including fat tissue; Figure 5A), irrespective of the presence of benign lymphoepithelial lesions (LEL; Figure 5B). LELs are a characteristic histological feature of the salivary, predominantly parotid, glands of SS patients. LELs form through basal cell hyperplasia forming a multi-layered epithelium. Between these reactive ductal epithelial cells, lymphocytes are present.

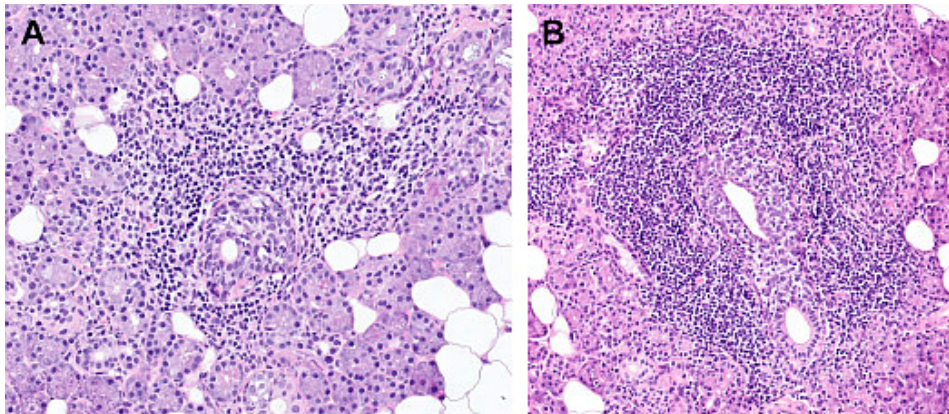


Figure 5: Histopathology of the parotid salivary glands of a patient with Sjögren's syndrome.

A) Focus **B)** Lymphoepithelial lesion

Complications

Potential complications of parotid salivary gland biopsies include the development of sialoceles and salivary fistulae, and a temporary change in sensation in the skin area of the incision,^{11,18} which are obvious due to the surgical opening of the skin and superficial gland area. As mentioned before, development on sialoceles or fistula has not yet been observed by us and is neither reported in the literature. The often mentioned potential risk of facial nerve damage is based on lack knowledge of anatomic and surgical skills as this nerve,

as also mentioned before, is 1.5-2 cm below the surface of the gland. The only reported complications are a temporary change in sensation in the skin area of the incision. No permanent complications are, however, documented in the literature.^{11,18,26} The level of post-operative pain accompanying a parotid gland biopsy is comparable to a lip biopsy.¹¹

SUITABILITY OF SALIVARY GLAND BIOPSIES

Diagnostic

As mentioned before, a labial salivary gland biopsy is considered as positive for SS when focal lymphocytic sialadenitis with a focus score ≥ 1 per 4 mm² glandular tissue is present (Figure 3). However, for proper interpretation of the biopsy specimens broad experience is needed as focal lymphocytic sialadenitis may occur in conjunction with other autoimmune diseases and even in healthy subjects, in particular in the elderly.²⁷ Typically for pSS, the lymphocytic foci have to be adjacent to normal-appearing mucous acini and contain no more than a minority proportion of plasma cells. Furthermore, above a focus score of 10, foci are typical confluent and an arbitrary score of 12 is often applied for such biopsies.^{13,14} Other difficulties that may interfere with the interpretation of the biopsies are features more usually associated with non-specific chronic sialadenitis, such as acinar atrophy, interstitial fibrosis and duct dilatation. These features are relatively common and increase with age and may also coexist with pSS related focal lymphocytic sialadenitis.^{10,28} Replacement of glandular tissue with fibrotic tissue as a result of age and chronic salivary gland inflammation may lower the focus score and lead to a 'burnt-out' appearance.^{10,29} Moreover, it may be difficult to harvest a sufficient number of labial salivary glands in atrophic submucosa of patients with longstanding SS.³⁰

In contrast to labial glands, parotid salivary biopsies allow the clinician to monitor disease progression and to assess the effect of an intervention treatment in SS. This is feasible due to the fact that parotid tissue can be harvested relative easily, repeated biopsies from the same parotid gland are possible, and the histopathological results can be compared with other diagnostic results derived from the same gland (e.g., secretory function, sialographic appearance, scintigraphy, ultrasound, CT, MRI).³¹ Additionally, by performing parotid biopsies as a routine diagnostic procedure for SS, LELs and lymphomas located in the parotid gland can be identified (see section on lymphoma).^{18,32} So, the question remains as to what biopsy should be preferred for diagnostics and/or monitoring disease progression and treatment efficacy.

Disease progression

There are only few studies that compared the diagnostic characteristics of major and minor salivary gland biopsies and even none that compared the ability of both biopsy types to monitor disease progression and treatment efficacy. Pijpe et al¹¹ compared the

diagnostic ability of labial and parotid salivary gland biopsies in diagnosing pSS as well as compared their morbidity. They showed that the diagnostic sensitivity and specificity were identical. Moreover, the presence of characteristic benign LELs in the parotid gland can aid the diagnosis of SS. The observation that LELs are commonly present in parotid biopsies and are virtually absent in labial salivary gland biopsies was earlier confirmed by Pennec et al³³ and Carbone et al.³⁴ The incidence of germinal centers in the major and minor salivary gland biopsies is comparable.¹¹ There is a need for larger studies comparing the diagnostic utility of labial and parotid salivary gland biopsies in the diagnostic work-up of SS emphasizing whether these procedures are exchangeable or that a specific biopsy type is preferred for a specific diagnostic issue regarding SS or SS-associated diseases.

Treatment evaluation purposes

EULAR has developed a disease activity index (ESSDAI) and a patient reported index (ESSPRI) as validated outcome measures for SS.³⁵⁻³⁸ Although the development is an important advantage, ESSDAI focuses on systemic disease features and is so less relevant to patients with predominantly glandular features. The ESSPRI addresses the symptomatic components of dryness, pain and fatigue. The latter has an important impact on the quality of life, but might be susceptible to placebo effects or the impact of concomitant disorders leading to important implications for sample size. Thus, as posed by Fisher et al,¹⁰ an objective biomarker of glandular inflammation would therefore be desirable, and salivary gland biopsy has added advantage that it may offer insights into the mechanism of action of a novel agent, or more importantly, reasons for failure in a negative study.

When comparing the potential application of labial and parotid salivary gland biopsies with regard to disease activity and progression, studies involving repeated labial salivary gland biopsies revealed that in patients presenting with sicca symptoms, a focus score ≥ 1 was associated with antibodies to Ro and La, rheumatoid factor, antinuclear antibody and a lower unstimulated whole salivary flow rate.^{4,39,40} It also was shown that a higher focus score is accompanied by a larger decrease in unstimulated⁴¹ and stimulated⁴² whole salivary flow rate over time. Repeated labial salivary gland biopsies might have some value in assessing the effect of biologicals on the glandular level as labial salivary gland biopsies seems to be of added value in rating the efficacy of treatment with rituximab⁷, abatacept⁸ or belimumab.⁹ It has to be mentioned, however, that not the same labial salivary glands are examined as a function of time, but a new sample of glands collected from the same patient bringing the hazard of the reproducibility of, e.g., a focus score in repeated sections from even the same labial salivary glands into mind.¹⁶ However, Kapsogeorgou et al⁴³ showed that the infiltration grade and prevalence of the major infiltrating cell types (T and B cells, macrophages, dendritic cells, natural killer cells) remained largely unchanged

during a median 55 month biopsy time interval follow-up (quartiles 42-81) indicating that the labial salivary gland histopathology is rather stable with time and probably does not readily reflect disease progression and/or disease activity.

In contrast to labial salivary glands, repeated biopsies from the same parotid gland are possible, which is probably an important asset in studies assessing the efficacy of a treatment in SS patients or monitoring disease progression. Another important advantage is that the histopathological results can be compared with other diagnostic results derived from the same gland (secretory function, sialographic appearance, scintigraphy, ultrasound, CT, MRI). Moreover, as mentioned before, LELs are often observed in parotid gland tissue of SS patients and rarely in labial salivary gland tissue. These LELs, a characteristic histological feature of the major salivary glands in SS⁴⁴, develop as a result of basal cell hyperplasia forming a multi-layered epithelium. Between these reactive ductal epithelial cells, lymphocytes are present.⁴⁴

While features of labial salivary gland pathology have been associated with a variety of serological, clinical and imaging parameters, features of parotid salivary gland tissue are not yet associated with such parameters. However, currently a number of studies is underway assessing whether histopathologic features reflect changes in whole and glandular salivary flow, serum and salivary gland ultrasonography. First results will become available shortly indicating whether disease progression and disease activity are indeed accompanied by characteristic features at the level of parotid gland histopathology. With regard of parotid salivary gland tissue as a monitor of treatment efficacy more progress has been made. Pijpe et al³¹ showed in an open label trial that sequential parotid biopsy specimens obtained from patients with pSS before and after rituximab treatment demonstrated histopathologic evidence of reduced glandular inflammation and redifferentiation of lymphoepithelial duct lesions to regular striated ducts as a putative morphologic correlate of increased parotid flow and normalization of the salivary sodium content. Next, Delli et al⁴⁵ assessed the prognostic value of parotid gland immunopathology with regard to responsiveness of patients with pSS to rituximab treatment in a randomized placebo controlled study. These investigators found a significant reduction in the number of CD20+ B-cells/mm² parenchyma, while no reduction was observed in placebo-treated patients. Furthermore, the relative number and severity of LELs and germinal centers significantly reduced after rituximab treatment. Moreover, when comparing the baseline characteristics of clinical responders with non-responders to rituximab treatment, number of CD20+ B-cells/mm² parenchyma was significantly higher in responders, which might predict the responsiveness of pSS patients to rituximab treatment. In addition, an open label study with abatacept⁴⁶ showed that treatment did not affect focus score, area of lymphocytic infiltrate, and number of LELs, infiltrating B- and T-cells. Abatacept reduced, however, the presence of germinal centers (GC), which was associated with an improvement in the glandular domain (reduction in swelling) of the ESSDAI. Thus, abatacept appears to

inhibit local T-cell dependent B-cell activation in parotid gland tissue of pSS patients as witnessed by the decline in GC/mm² after treatment. Furthermore the presence of GC at baseline predicts response in ESSDAI glandular domain after abatacept treatment. These observations have to be confirmed in a placebo controlled study, a study that is currently in progress.

SALIVARY GLAND BIOPSIES AND LYMPHOMAS

Five to ten per cent of patients with SS develop malignant B cell lymphoma,⁴⁷⁻⁴⁹ 48%–75% of which are of the MALT-type. These MALT B cell lymphomas are most frequently located in the parotid gland.⁵⁰⁻⁵² Theander et al⁶ suggested that the presence of GC-like structures in pSS diagnostic labial salivary biopsies is highly predictive and easy-to-obtain marker for non-Hodgkin lymphoma development. They even posed that presence of these GC-like structures allows for risk stratification of patients and the possibility to initiate preventive B-cell-directed therapy. Later on, however, Johnsen et al⁵³ were unable to detect a clear association between cellular infiltrates, B cell clonality, and lymphoma development in labial salivary gland biopsies. Our recent data indicate that presence of germinal centers in diagnostic (labial) biopsies is not a risk factor for the development of MALT lymphoma in the parotid glands.⁵⁴ Since lymphomas in pSS patients mainly develop in parotid glands, taking parotid gland biopsies may be a great asset in both diagnosing pSS associated lymphomas as well as in titrating which therapy is needed.³² Quintana et al⁵⁵ and De Vita et al⁵⁶ mentioned that LELs and reactive lymphoid follicles, features that are common place in parotid salivary gland pathology of pSS patients, are indicative of malignant lymphoma, and thus benign LELs must be discriminated from (pre)malignant lesions. Haacke et al⁵⁴ looked with more detail into salivary gland biopsies of pSS patients with regard to LELs and observed that FcRL4⁺ B cells are in close association with LELs and that these FcRL4⁺ B cells are significantly increased when comparing the parotid gland to the labial gland. As MALT lymphomas, and a small subset of diffuse B cell lymphomas, express FcRL4,⁵⁷ this observation might explain why lymphomas in pSS patients commonly develop in parotid and not in minor salivary glands and thus favors taking a parotid and not a labial salivary gland biopsy in the diagnostic work-up of SS patients, at least in patients with a suspect of lymphoma development.

SUMMARY

Early diagnosis and objective treatment evaluation of costly therapies based on biologicals are of high importance in SS. Unfortunately, so far there is not a single test capable of confirming the diagnosis of SS. A positive salivary gland biopsy is strong evidence, which in correlation with additional diagnostic tests can establish a definite conclusion. Parotid gland biopsy is a relatively simple technique with no permanent morbidity reported compared to a relative high morbidity rate of labial salivary gland biopsies due to the rather high hazard of permanent damage to the sensory nerve supply of the lower lip in the latter biopsies. Parotid biopsies are able to overcome most of these disadvantages.

REFERENCES

1. Vitali C, Bombardieri S, Jonsson R et al. Classification criteria for Sjögren's syndrome: a revised version of the European criteria proposed by the American-European Consensus Group. *Ann Rheum Dis* 2002;61:554-58.
2. Shiboski SC, Shiboski CH, Criswell L et al. American College of Rheumatology classification criteria for Sjögren's syndrome: a data-driven, expert consensus approach in the Sjögren's International Collaborative Clinical Alliance cohort. *Arthritis Care Res (Hoboken)* 2012;64:475-87.
3. Chisholm DM, Mason DK. Labial salivary gland biopsy in Sjögren's disease. *J Clin Pathol* 1968;21:656-60.
4. Daniels TE, Cox D, Shiboski CH et al. Associations between salivary gland histopathologic diagnoses and phenotypic features of Sjögren's syndrome among 1,726 registry participants. *Arthritis Rheum* 2011;63:2021-30.
5. Shiboski C, Shiboski S. Proposed ACR-EULAR Classification Criteria for Sjögren's Syndrome: Development and Validation. *Scand J Immunol* 2015;81:330.
6. Theander E, Vasaitis L, Baecklund E et al. Lymphoid organisation in labial salivary gland biopsies is a possible predictor for the development of malignant lymphoma in primary Sjögren's syndrome. *Ann Rheum Dis* 2011;70:1363-68.
7. Carubbi F, Cipriani P, Marrelli A et al. Efficacy and safety of rituximab treatment in early primary Sjögren's syndrome: a prospective, multi-center, follow-up study. *Arthritis Res Ther* 2013;15:R172.
8. Adler S, Korner M, Forger F et al. Evaluation of histologic, serologic, and clinical changes in response to abatacept treatment of primary Sjögren's syndrome: a pilot study. *Arthritis Care Res (Hoboken)* 2013;65:1862-68.
9. De Vita S, Quartuccio L, Seror R et al. Efficacy and safety of belimumab given for 12 months in primary Sjögren's syndrome: the BELISS open-label phase II study. *Rheumatology (Oxford)* 2015;54:2249-56.
10. Fisher BA, Brown RM, Bowman SJ et al. A review of salivary gland histopathology in primary Sjögren's syndrome with a focus on its potential as a clinical trials biomarker. *Ann Rheum Dis* 2015;74:1645-50.
11. Pijpe J, Kalk WW, van der Wal JE et al. Parotid gland biopsy compared with labial biopsy in the diagnosis of patients with primary Sjögren's syndrome. *Rheumatology (Oxford)* 2007;46:335-41.
12. Vissink A, Bootsma H, Kroese FG et al. How to assess treatment efficacy in Sjögren's syndrome? *Curr Opin Rheumatol* 2012;24:281-89.
13. Greenspan JS, Daniels TE, Talal N et al. The histopathology of Sjögren's syndrome in labial salivary gland biopsies. *Oral Surg Oral Med Oral Pathol* 1974;37:217-29.
14. Daniels TE. Labial salivary gland biopsy in Sjögren's syndrome. Assessment as a diagnostic criterion in 362 suspected cases. *Arthritis Rheum* 1984;27:147-56.
15. Labial Salivary Glands Biopsy Histopathology SOP for SICCA Research Groups. 2010. Available at: https://sicca-online.ucsf.edu/documents/LSG_bx_Grading_SOP.pdf.
16. Al-Hashimi I, Wright JM, Cooley CA et al. Reproducibility of biopsy grade in Sjögren's syndrome. *J Oral Pathol Med* 2001;30:408-12.
17. Friedman H, Kilmar V, Galletta VP et al. Lip biopsy in connective tissue diseases. A review and study of seventy cases. *Oral Surg Oral Med Oral Pathol* 1979;47:256-62.
18. Marx RE, Hartman KS, Rethman KV. A prospective study comparing incisional labial to incisional parotid biopsies in the detection and confirmation of sarcoidosis, Sjögren's disease, sialosis and lymphoma. *J Rheumatol* 1988;15:621-29.
19. Delgado WA, Mosqueda A. A highly sensitive method for diagnosis of secondary amyloidosis by labial salivary gland biopsy. *J Oral Pathol Med* 1989;18:310-14.
20. Mahlstedt K, Ussmuller J, Donath K. Value of minor salivary gland biopsy in diagnosing Sjögren's syndrome. *J Otolaryngol* 2002;31:299-03.

21. Berquin K, Mahy P, Weynand B et al. Accessory or sublingual salivary gland biopsy to assess systemic disease: a comparative retrospective study. *Eur Arch Otorhinolaryngol* 2006;263:233-36.
22. Caporali R, Bonacci E, Epis O et al. Comment on: parotid gland biopsy compared with labial biopsy in the diagnosis of patients with primary Sjögren's Syndrome. *Rheumatology (Oxford)* 2007;46:1625; author reply 1625-6.
23. Teppo H, Revonta M. A follow-up study of minimally invasive lip biopsy in the diagnosis of Sjögren's syndrome. *Clin Rheumatol* 2007;26:1099-03.
24. Richards A, Mutlu S, Scully C et al. Complications associated with labial salivary gland biopsy in the investigation of connective tissue disorders. *Ann Rheum Dis* 1992;51:996-97.
25. Kraaijenhagen HA. Letter: Technique for parotid biopsy. *J Oral Surg* 1975;33:328.
26. Delli K, Vissink A, Spijkervet FK. Salivary gland biopsy for Sjögren's syndrome. *Oral Maxillofac Surg Clin North Am* 2014;26:23-33.
27. Radfar L, Kleiner DE, Fox PC et al. Prevalence and clinical significance of lymphocytic foci in minor salivary glands of healthy volunteers. *Arthritis Rheum* 2002;47:520-24.
28. Scott J. Qualitative and quantitative observations on the histology of human labial salivary glands obtained post mortem. *J Biol Buccale* 1980;8:187-00.
29. Bookman AA, Shen H, Cook RJ et al. Whole stimulated salivary flow: correlation with the pathology of inflammation and damage in minor salivary gland biopsy specimens from patients with primary Sjögren's syndrome but not patients with sicca. *Arthritis Rheum* 2011;63:2014-20.
30. Vitali C, Tavoni A, Simi U et al. Parotid sialography and minor salivary gland biopsy in the diagnosis of Sjögren's syndrome. A comparative study of 84 patients. *J Rheumatol* 1988;15:262-67.
31. Pijpe J, Meijer JM, Bootsma H et al. Clinical and histologic evidence of salivary gland restoration supports the efficacy of rituximab treatment in Sjögren's syndrome. *Arthritis Rheum* 2009;60:3251-56.
32. Pollard RP, Pijpe J, Bootsma H et al. Treatment of mucosa-associated lymphoid tissue lymphoma in Sjögren's syndrome: a retrospective clinical study. *J Rheumatol* 2011;38:2198-08.
33. Pennec YL, Leroy JP, Jouquan J et al. Comparison of labial and sublingual salivary gland biopsies in the diagnosis of Sjögren's syndrome. *Ann Rheum Dis* 1990;49:37-39.
34. Carbone A, Gloghini A, Ferlito A. Pathological features of lymphoid proliferations of the salivary glands: lymphoepithelial sialadenitis versus low-grade B-cell lymphoma of the malt type. *Ann Otol Rhinol Laryngol* 2000;109:1170-75.
35. Seror R, Ravaud P, Bowman SJ et al. EULAR Sjögren's syndrome disease activity index: development of a consensus systemic disease activity index for primary Sjögren's syndrome. *Ann Rheum Dis* 2010;69:1103-09.
36. Seror R, Ravaud P, Mariette X et al. EULAR Sjögren's Syndrome Patient Reported Index (ESSPRI): development of a consensus patient index for primary Sjögren's syndrome. *Ann Rheum Dis* 2011;70:968-72.
37. Seror R, Bootsma H, Saraux A et al. Defining disease activity states and clinically meaningful improvement in primary Sjögren's syndrome with EULAR primary Sjögren's syndrome disease activity (ESSDAI) and patient-reported indexes (ESSPRI). *Ann Rheum Dis* 2016;75:382-89.
38. Seror R, Theander E, Brun JG et al. Validation of EULAR primary Sjögren's syndrome disease activity (ESSDAI) and patient indexes (ESSPRI). *Ann Rheum Dis* 2015;74:859-66.
39. Dinerman H, Goldenberg DL, Felson DT. A prospective evaluation of 118 patients with the fibromyalgia syndrome: prevalence of Raynaud's phenomenon, sicca symptoms, ANA, low complement, and Ig deposition at the dermal-epidermal junction. *J Rheumatol* 1986;13:368-73.
40. Rhodus NL, Friction J, Carlson P et al. Oral symptoms associated with fibromyalgia syndrome. *J Rheumatol* 2003;30:1841-45.
41. Haldorsen K, Moen K, Jacobsen H et al. Exocrine function in primary Sjögren syndrome: natural course and prognostic factors. *Ann Rheum Dis* 2008;67:949-54.
42. Jonsson R, Kroneld U, Backman K et al. Progression

- of sialadenitis in Sjögren's syndrome. *Br J Rheumatol* 1993;32:578-81.
43. Kapsogeorgou EK, Christodoulou MI, Panagiotakos DB et al. Minor salivary gland inflammatory lesions in Sjögren syndrome: do they evolve? *J Rheumatol* 2013;40:1566-71.
 44. Ihrler S, Zietz C, Sendelhofert A et al. Lymphoepithelial duct lesions in Sjögren-type sialadenitis. *Virchows Arch* 1999;434:315-23.
 45. Delli K, Haacke EA, Pollard RP et al. Baseline characteristics of parotid gland histopathology predict responsiveness of patients with primary Sjögren's syndrome to rituximab treatment. *Scand J Immunol* 2015;81:434-35.
 46. Haacke EA, van der Vegt B, Meiners PM et al. Germinal centers disappear in parotid gland tissue after treatment of primary Sjögren's syndrome with Abatacept. *Scand J Immunol* 2015;81:437-38.
 47. Sutcliffe N, Inanc M, Speight P et al. Predictors of lymphoma development in primary Sjögren's syndrome. *Semin Arthritis Rheum* 1998;28:80-87.
 48. Theander E, Henriksson G, Ljungberg O et al. Lymphoma and other malignancies in primary Sjögren's syndrome: a cohort study on cancer incidence and lymphoma predictors. *Ann Rheum Dis* 2006;65:796-03.
 49. Nocturne G, Mariette X. Sjögren Syndrome-associated lymphomas: an update on pathogenesis and management. *Br J Haematol* 2015;168:317-27.
 50. Kassan SS, Thomas TL, Moutsopoulos HM et al. Increased risk of lymphoma in sicca syndrome. *Ann Intern Med* 1978;89:888-92.
 51. Tzioufas AG, Boumba DS, Skopouli FN et al. Mixed monoclonal cryoglobulinemia and monoclonal rheumatoid factor cross-reactive idiotypes as predictive factors for the development of lymphoma in primary Sjögren's syndrome. *Arthritis Rheum* 1996;39:767-72.
 52. Voulgarelis M, Dafni UG, Isenberg DA et al. Malignant lymphoma in primary Sjögren's syndrome: a multicenter, retrospective, clinical study by the European Concerted Action on Sjögren's Syndrome. *Arthritis Rheum* 1999;42:1765-72.
 53. Johnsen SJ, Berget E, Jonsson MV et al. Evaluation of germinal center-like structures and B cell clonality in patients with primary Sjögren syndrome with and without lymphoma. *J Rheumatol* 2014;41:2214-22.
 54. Haacke EA, Kluin PM, Vissink A et al. Salivary gland FcRL4(+) B-cells are a potential source of progenitor cells for MALT lymphoma in primary Sjögren's syndrome. *Scand J Immunol* 2015;81:380-81.
 55. Quintana PG, Kapadia SB, Bahler DW et al. Salivary gland lymphoid infiltrates associated with lymphoepithelial lesions: a clinicopathologic, immunophenotypic, and genotypic study. *Hum Pathol* 1997;28:850-61.
 56. De Vita S, De Marchi G, Sacco S et al. Preliminary classification of nonmalignant B cell proliferation in Sjögren's syndrome: perspectives on pathobiology and treatment based on an integrated clinico-pathologic and molecular study approach. *Blood Cells Mol Dis* 2001;27:757-66.
 57. Falini B, Agostinelli C, Bigerna B et al. IRTA1 is selectively expressed in nodal and extranodal marginal zone lymphomas. *Histopathology* 2012;61:930-41.
 58. Guevara-Gutierrez E, Tlacuilo-Parra A, Minjares-Padilla LM. Minor salivary gland punch biopsy for evaluation of Sjögren's syndrome. *J Clin Rheumatol* 2001;7:401-02.
 59. Gorson KC, Ropper AH. Positive salivary gland biopsy, Sjögren syndrome, and neuropathy: clinical implications. *Muscle Nerve* 2003;28:553-60.
 60. McGuirt WF Jr, Whang C, Moreland W. The role of parotid biopsy in the diagnosis of pediatric Sjögren syndrome. *Arch Otolaryngol Head Neck Surg* 2002;128:1279-81.
 61. Baumrath H. Parotid biopsy technique. *J Oral Maxillofac Surg* 2005;63:1556-57.
 62. Adam P, Haroun A, Billet J et al. Biopsy of the salivary glands. The importance and technic of biopsy of the sublingual gland on its antero-lateral side. *Rev Stomatol Chir Maxillofac* 1992;93:337-40.



CHAPTER 3a

Need for consensus guidelines to standardise the assessment of germinal centres and other histopathological parameters in salivary gland tissue of patients with primary Sjögren's syndrome.

Konstantina Delli¹
Erlin A Haacke^{2,3}
Stephan Ihrler⁴
Bert van der Vegt³

Arjan Vissink¹
Hendrika Bootsma²
Frederik KL Spijkervet¹
Frans GM Kroese²

Department of ¹Oral and Maxillofacial Surgery, ²Rheumatology & Clinical Immunology, ³Pathology and Medical Biology, University of Groningen, University Medical Center Groningen, the Netherlands and ⁴Laboratory for Dermatohistology & Oral Pathology, Munich, Germany

Modified version of Ann Rheum Dis. 2016 Jun;75(6):e32

We have read with great interest the letter to the editor by van Roon et al.¹ commenting to our paper 'Towards personalised treatment in primary Sjögren's syndrome: baseline parotid histopathology predicts responsiveness to rituximab treatment'.² The authors argue that there is a need for standardisation of the histopathological characteristics of salivary gland tissue of patients with primary Sjögren's syndrome (pSS), in general, and of the presence of germinal centres (GCs), in particular.

We fully agree with van Roon et al.¹ and other authors about the need for consensus guidelines to standardise the histopathological evaluation of salivary gland biopsies in patients with pSS.³ A standardised scoring system may facilitate prognostication and stratification of patients with pSS and is needed for a valid evaluation of various clinical trials.³ In particular, histological definition of GCs in salivary gland tissue is warranted, since these structures can be difficult to detect in diagnostic H&E-stained tissue sections. Detection of GCs in the periductal lymphoid infiltrates of the salivary glands is clinically relevant, because the presence of these structures is associated with more severe disease.⁴ Importantly, the presence of GCs in minor salivary gland biopsies has been postulated to be a predictor of patients who are at risk of lymphoma development.^{5,6} It has to be mentioned, however, that recently, we were not able to confirm these findings for a larger number of mucosa-associated lymphoid tissue (MALT) lymphomas in parotid glands of patients with pSS (Haacke et al., unpublished data).

In our study, we defined GCs in H&E stained sections as lighter areas within the lymphoid infiltrate composed of both lymphoid cells (centrocytes, centroblasts) and cells with a non-lymphoid nature (macrophages and follicular dendritic cells (FDCs)) (Figure 1a).¹ Furthermore, the GCs were scored independently by two experienced pathologists. For the inexperienced eye, GCs may be overlooked, because of their small size, or lighter areas within the infiltrate may erroneously be scored as GCs, while in fact they represent lymphoepithelial lesions. For proper and easy detection of GCs, also by less-trained persons, additional immunohistochemical staining might be helpful. Therefore, we propose to stain for B-cell lymphoma 6 (Bcl-6) to define and identify GCs. Bcl-6 is a transcription factor expressed at high levels by GC B-cells. Like GCs in peripheral lymphoid organs, GCs in salivary glands of patients with pSS are also consistently positive for Bcl-6.⁵ As shown in Figure 1b, staining for Bcl-6 allows the easy and unequivocal detection and scoring of GCs in salivary gland biopsies, both in minor and major (parotid) salivary glands. Implementation of Bcl-6 staining is relatively easy, since it is routinely used in pathology laboratories worldwide for the diagnosis of lymphomas.⁷ Other markers, as proposed by Fisher et al.³ and van Roon et al.,¹ are less specific and less suitable to detect GCs in routine diagnostics. For example, activation-induced deaminase, an enzyme essential for the function of GCs B-cells, is expressed only by a minority of GCs B-cells in minor salivary glands of patients with pSS,⁵ which may make GCs harder to detect. The long isoform of CD21 (CD21L) has also been suggested for detection of GCs. CD21L is expressed by

follicular dendritic cells (FDCs). However, although FDCs are a prerequisite for GC function and development, the presence of these cells does not necessarily imply that GCs are present. Indeed, ectopic lymphoid infiltrates in salivary gland tissue of patients with pSS can contain FDC networks in the absence of GCs.^{8,9} Staining for the CD21L may therefore result in an overestimation of the number of GCs present in salivary gland tissue.

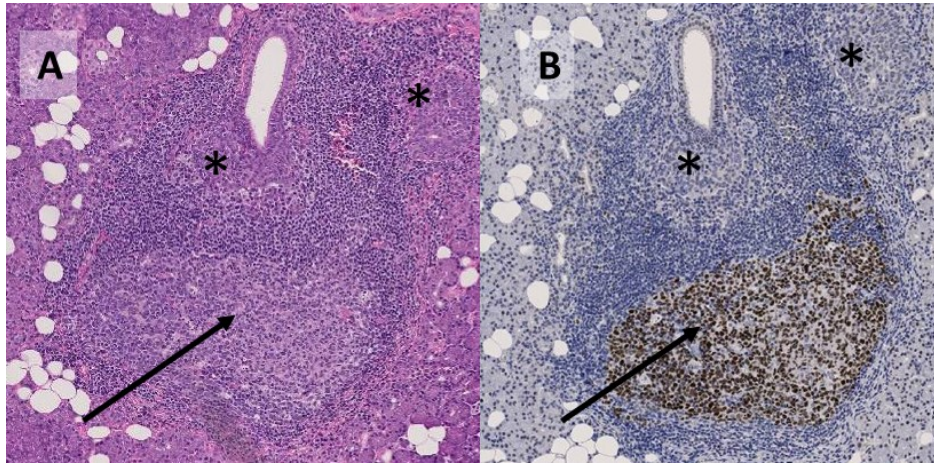


Figure 1: Images showing serial paraffin sections of a parotid gland biopsy of a patient with primary Sjögren's syndrome (pSS) stained with **A)** H&E and **B)** for Bcl-6. A clearly visible germinal centre (GC) (indicated with an arrow) is seen in the periductal infiltrate. Asterisks indicate lymphoepithelial lesions.

In our study we observed that a relative high proportion of the parotid salivary gland biopsies presented with GCs at baseline; 67% and 68% of patients in the placebo-treated and rituximab-treated groups, respectively.² These are relatively high percentages compared with the general pSS population, in which approximately one-quarter of the minor salivary gland biopsies exhibit GCs.⁴ The reason for this high baseline characteristic can be attributed to the inclusion criteria of our study. In our study the patients with pSS were all positive for anti-SSA antibodies and had high systemic activity, as indicated by the relatively high European League against Rheumatism Sjögren's Syndrome Disease Activity Index scores.¹⁰ Indeed, presence of GCs in minor salivary glands has been associated with more severe disease, including systemic proinflammatory mediators and anti-SSA antibodies.⁴ A second explanation for the high number of GCs at baseline might be related to histopathological differences between minor and parotid salivary gland biopsies. Although a previous study in a small cohort of patients with pSS (n=30) did not report a difference in numbers of GCs,¹¹ it remains possible that there are more and/or larger GCs in parotid gland biopsies compared to minor salivary glands. Apparently, there is a

petition for larger studies focusing on the inherent differences in the histopathological characteristics of parotid and minor salivary gland tissue in both pSS patients and healthy controls.

In summary, in agreement with van Roon et al.¹ we would also like to emphasise that there is a need for consensus guidelines to standardise the evaluation of ectopic lymphoid infiltrates and GCs in salivary gland tissue of patients with pSS. The various methods used for automated analysis of several parameters should also be taken into account.¹² Consensus guidelines will assist the pathologist to correctly identify and quantify histopathological parameters in pSS and contribute to a more accurate prediction of disease progression and personalised treatment, as well as allowing the comparison between study cohorts and different clinical trials.

3a

REFERENCES

1. Van Roon JA, Hillen MR, Barone F, et al. Towards standardization of histopathologic assessments of germinal centres and lymphoid structures in primary Sjögren's syndrome. *Ann Rheum Dis* 2016;75:e32.
2. Delli K, Haacke EA, Kroese FG, et al. Towards personalised treatment in primary Sjögren's syndrome: baseline parotid histopathology predicts responsiveness to rituximab treatment. *Ann Rheum Dis* 2016;75:1933-38.
3. Fisher BA, Brown RM, Bowman SJ, et al. A review of salivary gland histopathology in primary Sjögren's syndrome with a focus on its potential as a clinical trials biomarker. *Ann Rheum Dis* 2015;74:1645-50.
4. Risselada AP, Looije MF, Kruize AA, et al. The role of ectopic germinal centers in the immunopathology of primary Sjögren's syndrome: a systematic review. *Semin Arthritis Rheum* 2013;42:368-76.
5. Bombardieri M, Barone F, Humby F, et al. Activation-induced cytidine deaminase expression in follicular dendritic cell networks and interfollicular large B cells supports functionality of ectopic lymphoid neogenesis in autoimmune sialoadenitis and MALT lymphoma in Sjögren's syndrome. *J Immunol* 2007;179:4929-38.
6. Theander E, Vasaitis L, Baecklund E, et al. Lymphoid organisation in labial salivary gland biopsies is a possible predictor for the development of malignant lymphoma in primary Sjögren's syndrome. *Ann Rheum Dis* 2011;70:1363-68.
7. Tan LH. A practical approach to the understanding and diagnosis of lymphoma: an assessment of the WHO classification based on immunoarchitecture and immuno-ontogenic principles. *Pathology* 2009;41:305-26.
8. Gommerman JL, Browning JL. Lymphotoxin/light, lymphoid microenvironments and autoimmune disease. *Nat Rev Immunol* 2003;3:642-55.
9. Jonsson MV, Skarsteine K. Follicular dendritic cells confirm lymphoid organization in the minor salivary glands of primary Sjögren's syndrome. *J Oral Pathol Med* 2008;37:515-52.
10. Moerman RV, Arends S, Meiners PM, et al. EULAR Sjögren's Syndrome Disease Activity Index (ESSDAI) is sensitive to show efficacy of rituximab treatment in a randomised controlled trial. *Ann Rheum Dis* 2014;73:472-74.
11. Pijpe J, Kalk WWI, Wal JE van der, et al. Parotid gland biopsy compared with labial biopsy in the diagnosis of patients with primary Sjögren's syndrome. *Rheumatology* 2007;46:335-41.
12. Delli K, Haacke EA, Kroese FG, et al. In primary Sjögren's syndrome high absolute numbers and proportions of B cells in parotid glands predict responsiveness to rituximab as defined by ESSDAI, but not by SSRI. *Ann Rheum Dis* 2016;75:e34.



CHAPTER 3b

Standardisation of the detection of germinal centres in salivary gland biopsies of patients with primary Sjögren's syndrome is needed to assess their clinical relevance

Erlin A Haacke^{1,2}
Bert van der Vegt²
Arjan Vissink³

Frederik KL Spijkervet³
Hendrika Bootsma¹
Frans GM Kroese¹

Department of ¹Rheumatology & Clinical Immunology, ²Pathology and Medical Biology, ³Oral and Maxillofacial Surgery, University of Groningen, University Medical Center Groningen, the Netherlands

Modified version of Ann Rheum Dis. 2018;77:e32

We thank Alunno et al.¹ for their comments, as a response to our recent publication² in which we describe that, in contrast to the prevailing view, germinal centres in diagnostic labial gland biopsies are not predictive for the development of mucosa-associated lymphoid tissue (MALT) lymphoma in parotid salivary glands in patients with (primary) Sjögren's syndrome (pSS). As we² and others also noted before,³⁻⁶ Alunno et al.¹ underpin in their comments the need for standardisation of the detection method of germinal centres in salivary gland biopsies in patients with pSS. Germinal centres are structures that arise in B-cell follicles of secondary lymphoid organs as a response to antigenic stimulation. In these structures, high-affinity memory B-cells are generated, as a consequence of an intimate interplay between B-cells, follicular helper T cells (T_{FH}) and immune-complex presenting follicular dendritic cells (FDCs). Germinal centres can also be found within B-cell areas of ectopic (tertiary) lymphoid tissue that develops in target tissues of various rheumatic autoimmune diseases, including pSS.⁷ While detection in secondary lymphoid tissue is usually relatively simple, recognition of these structures in salivary gland biopsies of patients with pSS is generally more difficult. In particular in H&E stained sections, striated ducts infiltrated with lymphocytes (lymphoepithelial lesions), can erroneously be mistaken for germinal centres (see Figure 1). As discussed before,⁵ we proposed for this reason to use staining for transcription factor B-cell lymphoma (Bcl)-6 to identify germinal centres (Figure 1). Bcl-6 is consistently expressed at high levels by germinal centre B-cells and is commonly applied by pathology laboratories for lymphoma subtyping. In our study² we observed slightly more germinal centres in Bcl-6 stained sections of pSS salivary gland biopsies compared with H&E stained sections, which was due to the fact that also small germinal centres (defined as clusters of ≥ 5 Bcl-6⁺ B-cells) could easily be detected. Larger cohorts of salivary gland biopsies are obviously needed to establish the higher sensitivity and specificity of Bcl-6 stained sections, compared to H&E salivary gland stained sections.

FDCs are not only essential for the generation and function of germinal centres but are, as CXCL13 producing cells, also critically involved in the maintenance of the spatial organisation of the ectopic lymphoid tissue into segregated B-cell and T-cell areas.⁸ Indeed, the mere presence of FDC networks, as revealed by CD21 staining, in salivary gland lymphoid tissue of patients with pSS does not imply that germinal centres are also present.⁹ Staining for (the long isoform of) CD21 is thus not appropriate for identification of germinal centres. Nevertheless, CD21 staining may be useful to discriminate unorganised infiltrates from organised ectopic lymphoid tissue. Besides proper detection of structures, we like to stress here that the proper nomenclature should be used in all histopathological studies and that ectopic lymphoid tissue is not equivalent with ectopic germinal centres. We propose the following levels of organisation of the infiltrating lymphoid cells: (1) unorganised lymphocytic focus (CD21-Bcl-6-),

(2) organised lymphocytic focus (ectopic lymphoid tissue) without germinal centres (CD21+Bcl-6-) and (3) organised lymphocytic focus (ectopic lymphoid tissue) with germinal centres (CD21+Bcl-6+).

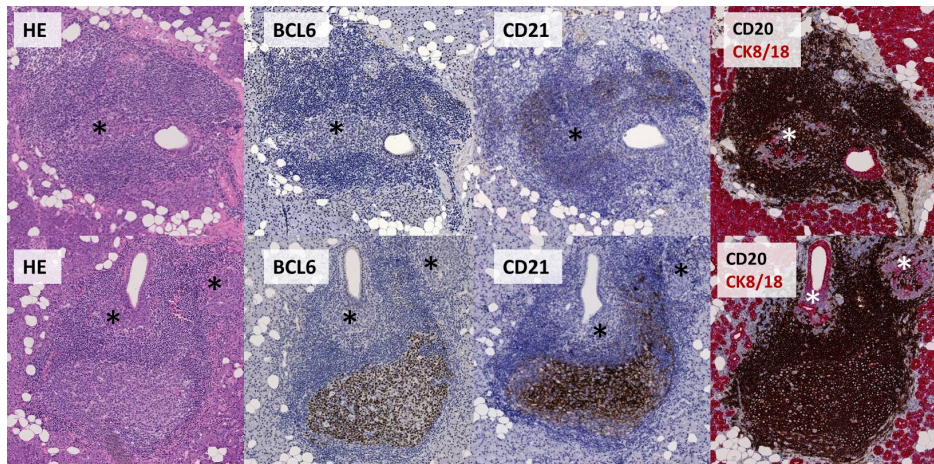


Figure 1: Histopathological evaluation of germinal centers in parotid salivary glands of pSS patients.

Consecutive formalin fixed-paraffin embedded parotid gland sections from two pSS patients were stained for H&E, Bcl-6, CD21 and for CD20 (brown) plus cytokeratin (CK) 8+18 (red). The CK staining was used to identify epithelial cells. Lymphoepithelial lesions (composed of epithelial cells and lymphoid cells) are marked by an * and can be mistaken for germinal centers in H&E stained sections. The H&E stained and the Bcl6 stained micrographs of the lower panels are from our reference.⁵

An important question is whether identification of germinal centres is clinically relevant and has an additional value over the already collected serological and clinical data. Germinal centres are observed in diagnostic (minor) salivary gland biopsies of approximately 25% of the patients with pSS.¹⁰ Patients with germinal centres in their diagnostic biopsies seem to have more severe disease as witnessed by the presence of autoantibodies (rheumatoid factor, anti-SSA, anti-SSB), hypergammaglobulinaemia, increased levels of local and systemic proinflammatory cytokines and extraglandular manifestations.^{10,11} Presence of germinal centres has also been associated with a higher risk of non-Hodgkin's lymphoma development.¹² This latter association has been used frequently to justify the evaluation of germinal centres in minor salivary gland biopsies. However, importantly, only one of the seven non-Hodgkin lymphomas observed in the pSS cohort of the study of Theander et al.¹² was a parotid MALT lymphoma, that is. the type of lymphoma that is characteristically associated with pSS. In our retrospective study² we could not demonstrate that the presence of well-defined germinal centres in diagnostic minor salivary gland biopsies (both H&E and Bcl-6-defined) was also predictive for the development of parotid MALT

lymphoma. We agree with Alunno et al.¹ that histopathological analysis of salivary gland biopsies from larger cohorts of patients scored using standardised protocols and with well-defined definitions are needed to assess the clinical relevance of the presence of germinal centres in salivary gland biopsies of patients with pSS.

3b

REFERENCES

1. Alunno A, Carubbi F, Giacomelli R, et al. The challenge to interpret conflicting results and the need of a univocal definition for germinal centres in primary Sjögren's syndrome. *Ann Rheum Dis* 2018;77:e31.
2. Haacke EA, van der Vegt B, Vissink A, et al. Germinal centres in diagnostic labial gland biopsies of patients with primary Sjögren's syndrome are not predictive for parotid MALT lymphoma development. *Ann Rheum Dis* 2017;76:1781-84.
3. Fisher BA, Brown RM, Bowman SJ, et al. A review of salivary gland histopathology in primary Sjögren's syndrome with a focus on its potential as a clinical trials biomarker. *Ann Rheum Dis* 2015;74:1645-50.
4. Fisher BA, Jonsson R, Daniels T, et al. Standardisation of labial salivary gland histopathology in clinical trials in primary Sjögren's syndrome. *Ann Rheum Dis* 2017;76:1161-68.
5. Delli K, Haacke EA, Ihrler S, et al. Need for consensus guidelines to standardise the assessment of germinal centres and other histopathological parameters in salivary gland tissue of patients with primary Sjögren's syndrome. *Ann Rheum Dis* 2016;75:e32.
6. Hillen MR, Barone F, Radstake TR, et al. Towards standardisation of histopathological assessments of germinal centres and lymphoid structures in primary Sjögren's syndrome. *Ann Rheum Dis* 2016;75:e31.
7. Bombardieri M, Lewis M, Pitzalis C. Ectopic lymphoid neogenesis in rheumatic autoimmune diseases. *Nat Rev Rheumatol* 2017;13:141-54.
8. Ansel KM, Ngo VN, Hyman PL, et al. A chemokine-driven positive feedback loop organizes lymphoid follicles. *Nature* 2000;406:309-14.
9. Jonsson M V, Skarstein K. Follicular dendritic cells confirm lymphoid organization in the minor salivary glands of primary Sjögren's syndrome. *J Oral Pathol Med* 2008;37:515-21.
10. Risselada AP, Looije MF, Kruize AA, et al. The role of ectopic germinal centers in the immunopathology of primary Sjögren's syndrome: a systematic review. *Semin Arthritis Rheum* 2013;42:368-76.
11. Carubbi F, Alunno A, Cipriani P, et al. Is minor salivary gland biopsy more than a diagnostic tool in primary Sjögren's syndrome? Association between clinical, histopathological, and molecular features: A retrospective study. *Semin Arthritis Rheum* 2014;44:314-24.
12. Theander E, Vasaitis L, Baecklund E, et al. Lymphoid organisation in labial salivary gland biopsies is a possible predictor for the development of malignant lymphoma in primary Sjögren's syndrome. *Ann Rheum Dis* 2011;70:1363-68.

3b



CHAPTER 3c

Bcl6 for identification of germinal centres in salivary gland biopsies in primary Sjögren's syndrome

Uzma Nakshbandi^{1,2}
Erlin A Haacke^{1,3}
Hendrika Bootsma¹
Arjan Vissink²

Fred KL Spijkervet²
Bert van der Vegt³
Frans GM Kroese¹

Department of ¹Rheumatology & Clinical Immunology, ²Oral and Maxillofacial Surgery, ³Pathology and Medical Biology, University of Groningen, University Medical Center Groningen, the Netherlands

Modified version of Oral Dis. 2020;26;707-710.

INTRODUCTION

Histopathological assessment of salivary gland biopsies is an important element of the diagnostic work-up of Sjögren's syndrome (SS).^{1,2} Microscopic evaluation of salivary glands of primary SS (pSS) patients reveals characteristic periductal lymphocytic infiltrates (foci), which mainly consist of T- and B-lymphocytes, as well as a variety of non-lymphoid cells, including dendritic cells and macrophages. Over time, these infiltrates may become organised to ectopic lymphoid tissue with T/B cell compartmentalisation, presence of CD21⁺ follicular dendritic cell (FDC) networks and high endothelial venules.²⁻⁵ Germinal centres (GCs) are present within this ectopic lymphoid tissue in roughly one-quarter of the salivary gland biopsies of pSS patients and their presence is associated with more severe disease compared to GC-negative pSS patients.⁶ These glandular ectopic GCs express mRNA encoding for activation-induced deaminase, an enzyme critical for the induction of somatic hypermutation and essential for the main function of GCs, the generation of high-affinity memory B-cells.⁷⁻⁹

Presence of GCs in biopsies taken for the diagnosis of pSS has been suggested to be a risk factor for lymphoma development,¹⁰⁻¹² a finding recently disputed by us.^{13,14} Detection of GCs in routine haematoxylin and eosin (H&E) stained sections can be challenging because small GCs may be overlooked and distinction between GCs and lymphoepithelial lesions may be difficult.^{3,15} Therefore, immunohistochemical identification using antibodies directed against CD21, expressed by FDCs (but also by B-cells) or Bcl6, a transcription factor highly expressed by GC-B cells, have been used,^{7,15,16} but consensus criteria regarding identification of GCs are lacking.¹⁷ Hence, the aim of this study was to assess which staining is most suitable to unequivocally identify GCs in diagnostic salivary gland biopsies of pSS patients by comparing H&E, CD21 and Bcl6 stainings.

In our study we restricted ourselves to these three markers, which can be easily applied in an automated fashion in diagnostic pathology laboratories. For this reason, we did not consider staining for other GC-associated markers, such as activation-induced deaminase, as potential candidates for identification of GCs in biopsies.

MATERIALS AND METHODS

Patients and evaluation of salivary gland biopsies

From 42 pSS patients, classified according to American College of Rheumatology (ACR)-European League Against Rheumatism (EULAR) classification criteria,¹⁸ both a labial and a parotid salivary gland biopsy were obtained (see Table 1). Four µm thick serial sections of salivary gland biopsies were stained with H&E and immunohistochemically for CD21 and Bcl6. For detailed ethical approval information, staining characteristics and statistical analysis see supplementary methods.

Table 1: Demographic, clinical and histological parameters of patients with primary Sjögren's syndrome.

	pSS patients (n=42)
Demographic characteristics	
Age, years	52 ± 13
Female, n (%)	41 (97.6)
Caucasian, n (%)	41 (97.6)
Serological parameters	
RF positive, n (%)	25 (59.5)
ANA positive, n (%)	10 (23.8)
Anti-SSA positive, n (%)	32 (76.2)
Anti-SSB positive, n (%)	15 (35.7)
IgG	15.4 [11.7-19.4]
ESR	23.0 [9.8-45.5]
CRP	2.8 [1.0-5.5]
Clinical parameters	
ESSDAI score	3.5 [2.0-9.0]
Schirmer, mm/5 min	2.5 [0.0-5.0]
UWS, ml/min	0.1 [0.0-0.2]
Histopathological parameters of the labial gland	
Focus score	1.3 [1.0-2.4]
≤70% IgA plasma cells, n (%)	19 (45.2)
Lymphoepithelial lesions, n (%)	16 (38.1)
Relative area of CD45 ⁺ infiltrate*	9.1 [6.1-19.8]
Histopathologic parameters of the parotid gland	
Focus score	1.0 [0.0-1.7]
≤70% IgA plasma cells, n (%)	12 (28.6)
Lymphoepithelial lesions, n (%)	18 (42.9)
Relative area of CD45 ⁺ infiltrate*	4.5 [1.4-17.0]

Note: Patients were classified according to the ACR-EULAR criteria. Data are represented as mean ± SD, median [95% CI] or number (%). * % of area of lymphocytic infiltrate in salivary gland parenchyma (Aperio ImageScope v12.0). Abbreviations: ANA, antinuclear antibodies; CRP, C-reactive protein; ESR, erythrocyte sedimentation rate; ESSDAI, European League Against Rheumatism SS Disease Activity Index; n, number of patients; pSS, primary Sjögren's syndrome; RF, rheumatoid factor; SSA, Sjögren's syndrome antigen A; SSB, Sjögren's syndrome antigen B; UWS, unstimulated whole saliva.

In H&E stained sections, a GC was defined as a clearly visible lighter area in a lymphocytic infiltrate containing centrocytes, centroblasts, FDCs and macrophages. In CD21-stained sections, a network of positive staining within a focus was classified as a FDC-network. In Bcl6-stained sections a cluster of ≥5 adjacent positive cells within a focus was classified as a GC.¹⁵ Even though Bcl6 is also expressed by follicular helper T-cells, this expression does not interfere with detection of GCs as these cells are not organised in clusters as GCs, but lie scattered throughout the tissue (Figure 1).

RESULTS

Six labial and eleven parotid salivary gland biopsies did not contain any H&E defined periductal foci. For the remaining biopsies, 36 labial and 31 parotid glands, all individual H&E-defined foci (210 labial, 141 parotid) were analysed on serial sections. This staining revealed that 1% (3/210) of labial gland foci and 6% (9/141) of parotid gland foci contained H&E-defined GCs. Immunohistochemical staining for CD21, revealed that 24% (50/210) of the foci in the labial gland and 49% (69/141) of the foci in the parotid gland contained CD21⁺FDC-networks (Table 2). Importantly, after staining for Bcl6, we showed that only 18% (9/50) of the labial gland foci with CD21⁺FDC-networks and 32% (22/69) of the parotid gland foci with CD21⁺FDC-networks also comprised Bcl6⁺GCs. Apparently, not all foci contain CD21⁺FDC-networks and not all foci with CD21⁺FDC-networks also harbour Bcl6⁺GCs. This was confirmed by dual CD21/Bcl6 staining (Figure 1A). Consequently, the number of CD21⁺FDC-networks/mm² was significantly higher than the number of H&E⁺- and Bcl6⁺-defined GCs/mm² in both labial and parotid salivary glands (Figures 1B and 1C). We observed a significant correlation between CD21⁺FDC-networks/mm² in parotid and labial salivary gland biopsies (Figure 1D, $r=0.60$, $p=0.001$), indicating comparability in lymphoid organisation at these two anatomical sites. Such a correlation was not seen for the presence of H&E- or Bcl6-defined GCs.

3c

Table 2: Comparison between the number of germinal centres in labial and parotid salivary gland biopsies of primary Sjögren's syndrome patients.

	Labial salivary gland	Parotid salivary gland
Number of biopsies with foci	36	31
Number of foci	210	141
% H&E ⁺ GCs	1.4 (3/210)	6.4 (9/141)
% Bcl6 ⁺ GCs	4.3(9/210)	15.6 (22/141)
% CD21 ⁺ FDC networks	23.8 (50/210)	48.9 (69/141)

Note FDC, follicular dendritic cell; GCs, germinal centres; H&E, haematoxylin & eosin.

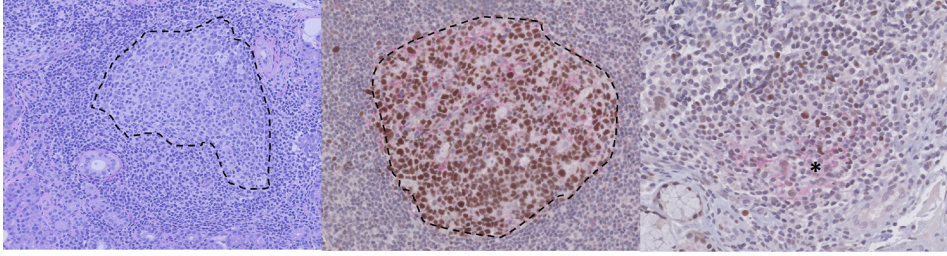
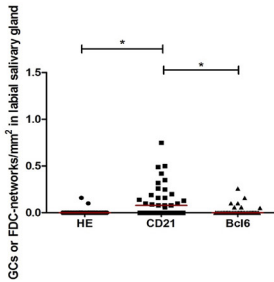
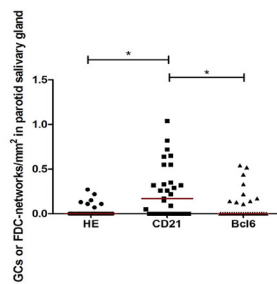
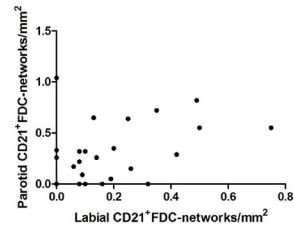
A**B****C****D**

Figure 1: Presence of germinal centres and follicular dendritic cell networks in salivary gland biopsies of patients with primary Sjögren's syndrome.

A) Histopathological identification of germinal centres. Paraffin embedded parotid gland biopsy of a patient with primary Sjögren's syndrome stained with H&E (left panel) and by double immunohistochemistry for CD21 (red) and Bcl6 (brown) (middle and right panel). The left panel shows a periductal focus with a H&E stained GC, (indicated by a dotted line, magnification 10x); the middle panel a CD21⁺FDC-network with a Bcl6⁺GC (indicated by a dotted line, magnification 20x), and the right panel a CD21⁺FDC-network (indicated by an asterisk, magnification 20x) without a GC. **B)** Number of GCs or FDC-networks/mm² in labial (n=36) salivary gland tissue after staining with H&E and immunohistochemically for Bcl6 or CD21. **C)** Number of GCs or FDC-networks/mm² parotid (n=31) salivary gland tissue after staining with H&E and immunohistochemically for Bcl6 or CD21. **D)** Spearman's rank order correlation revealed a significant positive association between CD21⁺FDC-networks/mm² in parotid and labial salivary gland biopsies (Figure 1D $r=0.60$, $p=0.001$). Red lines indicate median values, * $p<0.05$.

DISCUSSION

In a recent study Carubbi et al. analysed the usage of CD3/CD20 as well as CD21 and Bcl6 as markers for the detection of GCs.¹⁶ While they conclude that combination of CD3/CD20 and CD21 should be recommended for assessment of GCs, we clearly show here that usage of CD21 as surrogate marker for GCs significantly overestimates GC counts. The reason for this is that formation of B-cell follicles and presence of CD21⁺FDC-networks (which are also present in primary B-cell follicles), does not imply also presence of GCs.¹⁹ On the other hand, staining with H&E revealed fewer GCs compared to staining for Bcl6, most likely because small GCs can easily be overlooked on H&E.

Although staining for CD21 is thus less appropriate for detection of GCs, staining for CD21 is still valuable. FDCs play an essential role in the spatial orientation and B/T-cell compartmentalisation in ectopic lymphoid tissues due to their CXCL13 producing property. Presence of FDC-networks suggests a more advanced stage of ectopic lymphoid development and may therefore be a useful marker for classification of the organisation of glandular tissue.²⁰

3c

CONCLUSION

In conclusion, we propose to use Bcl6 as a simple, sensitive and specific marker for unequivocal identification of GCs in salivary gland biopsies of (suspected) pSS patients. Large prospective studies are now needed to evaluate whether presence of GCs in diagnostic salivary gland biopsies for pSS is a risk factor for non-Hodgkin lymphomas or not, and whether it can be used for stratification of pSS patients for personalised medicine.^{2,21}

ACKNOWLEDGEMENTS

Funding: This study was financially supported by a grant from the National Institutes of Dental and Craniofacial Research (U01 DE017593 Salivary Biomarkers for Sjögren's Syndrome Detection-Definitive Validation) and by a grant from the Dutch Arthritis Foundation (Grant 2013-2-066). There was no involvement of these funding sources in study design, data collection, analysis, and interpretation and writing of this report.

REFERENCES

1. Fox RI. Standardisation of labial salivary gland biopsies in Sjogren's syndrome: importance for the practicing rheumatologist. *Ann Rheum Dis* 2017;76:1159-60.
2. Kroese FGM, Haacke EA, Bombardieri M. The role of salivary gland histopathology in primary Sjögren's syndrome: promises and pitfalls. *Clin Exp Rheumatol* 2018;36:222-33.
3. Fisher BA, Jonsson R, Daniels T, et al. Standardisation of labial salivary gland histopathology in clinical trials in primary Sjögren's syndrome. *Ann Rheum Dis* 2017;76:1161-68.
4. Kroese FGM, Abdulahad WH, Haacke E, et al. B-cell hyperactivity in primary Sjögren's syndrome. *Expert Rev Clin Immunol* 2014;10:483-99.
5. Salomonsson S, Jonsson M V, Skarstein K, et al. Cellular basis of ectopic germinal center formation and autoantibody production in the target organ of patients with Sjögren's syndrome. *Arthritis Rheum* 2003;48:3187-01.
6. Risselada AP, Looije MF, Kruize AA, et al. The role of ectopic germinal centers in the immunopathology of primary Sjögren's syndrome: a systematic review. *Semin Arthritis Rheum* 2013;42:368-76.
7. Bombardieri M, Barone F, Humby F, et al. Activation-Induced Cytidine Deaminase Expression in Follicular Dendritic Cell Networks and Interfollicular Large B Cells Supports Functionality of Ectopic Lymphoid Neogenesis in Autoimmune Sialoadenitis and MALT Lymphoma in Sjogren's Syndrome. *J Immunol* 2007;179:4929-38.
8. Le Pottier L, Devauchelle V, Fautrel A, et al. Ectopic germinal centers are rare in Sjogren's syndrome salivary glands and do not exclude autoreactive B cells. *J Immunol* 2009;182:3540-47.
9. Muramatsu M, Kinoshita K, Fagarasan S, et al. Class switch recombination and hypermutation require activation-induced cytidine deaminase (AID), a potential RNA editing enzyme. *Cell* 2000;102:553-63.
10. Nishishinya MB, Pereda CA, Muñoz-Fernández S, et al. Identification of lymphoma predictors in patients with primary Sjögren's syndrome: a systematic literature review and meta-analysis. *Rheumatol Int* 2015;35:17-26.
11. Sène D, Ismael S, Forien M, et al. Ectopic germinal centre-like structures in minor salivary gland biopsy predict lymphoma occurrence in patients with primary Sjögren syndrome. *Arthritis Rheumatol* 2018;70:1481-88.
12. Theander E, Vasaitis L, Baecklund E, et al. Lymphoid organisation in labial salivary gland biopsies is a possible predictor for the development of malignant lymphoma in primary Sjögren ' s syndrome. *Ann Rheum Dis* 2011;161:1363-68.
13. Haacke EA, van der Vegt B, Vissink A, et al. Germinal centres in diagnostic labial gland biopsies of patients with primary Sjögren's syndrome are not predictive for parotid MALT lymphoma development. *Ann Rheum Dis* 2017;76:1781-84.
14. Haacke EA, van der Vegt B, Vissink A, et al. Germinal centres in diagnostic biopsies of patients with primary Sjögren's syndrome are not a risk factor for non-Hodgkin's lymphoma but a reflection of high disease activity: comment on the article by Sène et al. *Arthritis Rheumatol (Hoboken, NJ)* 2019;71:170-71.
15. Haacke EA, Van Der Vegt B, Vissink A, et al. Standardisation of the detection of germinal centres in salivary gland biopsies of patients with primary Sjögren's syndrome is needed to assess their clinical relevance. *Ann Rheum Dis* 2018;77(6):e32.
16. Carubbi F, Alunno A, Cipriani P, et al. Different operators and histologic techniques in the assessment of germinal center-like structures in primary Sjögren's syndrome minor salivary glands. *PLoS One* 2019;14:e0211142.
17. Delli K, Haacke EA, Ihrler S, et al. Need for consensus guidelines to standardise the assessment of germinal centres and other histopathological parameters in salivary gland tissue of patients with primary Sjögren's

- syndrome. *Ann Rheum Dis* 2016;75:e32.
18. Shiboski CH, Shiboski SC, Seror R, et al. 2016 American College of Rheumatology/European League Against Rheumatism Classification Criteria for Primary Sjögren's Syndrome: A Consensus and Data-Driven Methodology Involving Three International Patient Cohorts. *Arthritis Rheumatol* 2017;69:35-45.
 19. MacLennan IC. Germinal centers. *Annu Rev Immunol* 1994;12:117-39.
 20. Jonsson MV, Skarstein K. Follicular dendritic cells confirm lymphoid organization in the minor salivary glands of primary Sjögren's syndrome. *J Oral Pathol Med* 2008;37:515-21.
 21. Delli K, Villa A, Farah CS, et al. World Workshop on Oral Medicine VII: Biomarkers predicting lymphoma in the salivary glands of patients with Sjögren's syndrome-A systematic review. *Oral Dis* 2019;25:49-63.

SUPPLEMENTARY MATERIALS

Study information: Biopsies for this retrospective observational study were collected from 2014 until 2016. Inclusion and exclusion criteria are shown in supplementary table 1. All labial and parotid salivary gland biopsies were performed by one Oral and Maxillofacial surgeon (FKLS) at the University Medical Center Groningen.

Ethical approval information: The study was approved by the Medical Research Ethics Committee of the UMCG, the Netherlands (METc2013.066). All participants gave consent according to the declaration of Helsinki.

Immunohistological staining and histopathological assessment

CD21 staining: Sections were deparaffinised and antigen retrieval was performed (EDTA, pH 8). Endogenous peroxidase activity was blocked using H_2O_2 and PBS. Slides were incubated with CD21 antibodies (2G9; Cell Marque Corporation, USA) for 75 min. After rinsing, sections were treated with horse radish peroxidase (HRP) polymer (goat anti-mouse IgG) for 40 min. Staining was visualised with DAB and the sections were counterstained with haematoxylin. This staining procedure was optimized for the detection of FDC networks.

Bcl6 staining and CD21/Bcl6 double staining: Bcl-6 (Gl19E/A8; Ventana Medical systems, USA, pre-diluted by supplier) staining and CD21/Bcl6 double staining was performed after deparaffinisation, pre-treatment with Ultra CC1 (Ventana Medical Systems, USA), antigen retrieval and endogenous peroxidase blocking using the Benchmark automated staining platform (Ventana Medical Systems, USA). The double staining was performed serially.

All foci in labial and parotid salivary gland parenchyma were analysed for the presence of CD21⁺FDC-networks and for H&E⁺ or Bcl6⁺GCs by a trained researcher (UN), an experienced pathology resident (EH) and a head and neck pathologist (BvdV). Discrepancies between observers were resolved in a consensus meeting.

Statistical analysis

Data were analysed using SPSS version 23 statistical software (SPSS Inc., Chicago, IL). Differences between groups were tested with Mann-Whitney U test. Correlation analysis was performed using the Spearman's rank order correlation. *P*-values <0.05 were considered statistically significant.

Supplementary Table 1: Inclusion and exclusion criteria

Inclusion criteria	Exclusion criteria
<ul style="list-style-type: none">▪ Ability to give informed consent.▪ Male or female patients 18 years of age or older.▪ Patients, classified according to ACR-EULAR classification criteria.▪ Must be willing to have a standard physical exam as part of standard clinical care and a complete diagnostic work-up according to the ACR criteria for ocular staining, labial salivary gland biopsy and serology.▪ Must be willing to have a standard physical exam and complete AECG diagnostic tests as part of standard clinical care (including eye exam, oral exam, salivary gland exam and biopsy).▪ Must be willing to donate 1ml of stimulated, whole saliva in 30 minutes or less. If a participant cannot produce 1ml during a 30 min collection period, subject will be unavailable and will be considered a screen failure and withdrawn from the study.▪ Subjects must be willing have a labial salivary gland biopsy in addition to a parotid biopsy.▪ Must be willing and able to give approximately 8 ml of blood.	<ul style="list-style-type: none">▪ Previous radiation to the head and neck.▪ Confirmed hepatitis C virus infection, which may cause SS-like signs and symptoms.▪ Known HIV infection, which can cause salivary gland infiltrates and enlargements similar to SS.▪ Sarcoidosis, which may causes-like signs and symptoms.▪ Graft-versus-host disease, which may cause SS-like signs and symptoms.▪ Oral cancer or history of oral cancer.▪ Presence of MALT lymphoma.▪ Pregnancy based on self-report.▪ Previously confirmed diagnosis of autoimmune disease known to be associated with sSS (RA, SLE, CREST, scleroderma, mixed connective tissue disease, polymyositis).▪ Insufficient biopsy material harvested from either labial or parotid salivary gland.▪ Absence of any focus in the labial and parotid gland.

Note: Abbreviations: ACR, American College of Rheumatology; AECG, American-European Consensus Group; EULAR, European League Against Rheumatism; CREST, Calcinosis, Raynaud's syndrome, Esophageal dysmotility, Sclerodactyl, Telangiectasia; MALT, Mucosa associated lymphoid tissue; RA, Rheumatoid arthritis; SLE, Systemic Lupus Erythematosus; sSS, secondary Sjögren's syndrome.





PART 2

Germinal centres and MALT
lymphoma in biopsies of
primary Sjögren's syndrome



CHAPTER 4

FcRL4+ B-cells in salivary glands of primary Sjögren's syndrome patients

Erlin A Haacke^{1,2}
Hendrika Bootsma¹
Fred KL Spijkervet³
Annie Visser¹

Arjan Vissink³
Philip M Kluin²
Frans GM Kroese¹

Department of ¹Rheumatology & Clinical Immunology, ²Pathology and Medical Biology, ³Oral and Maxillofacial Surgery, University of Groningen, University Medical Center Groningen, the Netherlands

Modified version of: J Autoimmun. 2017;81:90-98

ABSTRACT

Fc receptor-like protein 4 (FcRL4) is normally expressed on a small subset of mucosa-associated B-cells, as well as on mucosa-associated lymphoid tissue (MALT) lymphoma B-cells. Primary Sjögren's syndrome (pSS) patients have an increased risk of developing MALT lymphomas, preferentially in the parotid glands. For this reason we studied here by immunohistochemistry and mRNA analysis whether FcRL4 expressing B-cells are present in salivary gland tissue (labial and parotid) of pSS patients (n=54) and non-pSS sicca patients (n=16) and whether parotid gland MALT lymphomas in pSS patients (n=49) also express this receptor. We also studied the effect of treatment (rituximab and abatacept) on the presence of FcRL4⁺ B-cells, and whether numbers in labial gland biopsies at time of diagnosis of pSS can predict whether patients are at risk for MALT lymphoma development. We demonstrate that FcRL4⁺ cells are present in salivary gland tissue of pSS patients where they are closely associated with ductal epithelial cells forming lymphoepithelial lesions. The glandular FcRL4⁺ cells are highly proliferative, genuine PAX5⁺ B-cells. These FcRL4⁺ B-cells are far more frequent in parotid gland than in labial gland tissue (p=0.003). We further show that expression of FcRL4 is present in pSS-related parotid MALT lymphomas. The FcRL4 mRNA expression level in parotid MALT lymphoma is increased compared to parotid gland tissue of pSS patients without lymphoma (p=0.017). However, numbers of FcRL4⁺ B-cells in labial gland biopsies taken at the time of pSS diagnosis, are not predictive for later development of MALT lymphoma. Reduction of parotid gland FcRL4⁺ B-cells by rituximab, but not abatacept is accompanied by restoration of the glandular epithelium, illustrating the crosstalk between these B-cells with the ductal cells.

In conclusion, intraepithelial FcRL4⁺ B-cells are present in the salivary glands of pSS patients. These cells are likely involved in the epithelial changes seen in pSS. Their enrichment in parotid glands may explain why MALT lymphomas in pSS patients preferentially develop at this specific location.

HIGHLIGHTS

- Highly proliferative FcRL4⁺ B-cells are present in salivary glands of pSS patients
- FcRL4⁺ B-cells are associated with salivary gland ductal epithelium and are enriched in parotid glands
- FcRL4⁺ B-cells can effectively be targeted by rituximab
- FcRL4 expression is preserved in pSS associated parotid MALT lymphomas

INTRODUCTION

Primary Sjögren's syndrome (pSS) is an autoimmune disease affecting exocrine glands leading to dryness of mouth and eyes.¹ Histologically, salivary glands of pSS patients harbor lymphocytic infiltrates that are arranged around striated ducts. The interaction of lymphocytes and the ductal epithelial cells is further emphasized by the formation of lymphoepithelial lesions (LELs), formerly called epimyoeplithelial islands. These LELs are composed of proliferative metaplastic epithelial cells and intraepithelial lymphocytes. Interestingly, LELs are more pronounced in parotid glands than in labial glands.²⁻⁴

A hallmark of pSS pathogenesis is hyperactivity of B-cells, which is amongst others reflected by the elevated risk of non-Hodgkin lymphoma development. This serious complication occurs in 5-10% of pSS patients.^{5,6} These lymphomas are almost exclusively B-cell lymphomas, mostly of the mucosa-associated lymphoid tissue (MALT) type (>60%) and preferentially develop in the parotid gland.⁶⁻⁸ It is not clear why MALT lymphomas arise predominantly at this location, since all minor and major salivary glands are affected in pSS.

Parotid MALT lymphomas often contain distinct LELs that are infiltrated and surrounded by neoplastic B-cells with a centrocyte-like or monocytoid appearance, sometimes admixed with neoplastic plasma cells.^{9,10} Falini et al. demonstrated that exclusively marginal zone lymphomas, including major salivary gland MALT lymphomas and a subset of DLBCL (diffuse large B-cell lymphoma) express the inhibitory Fc receptor-like protein 4 (FcRL4/IRTA1/CD307d).¹¹ DLBCL can develop, occasionally as transformation from MALT lymphoma in pSS patients as well.^{9,12} In healthy individuals, FcRL4 is expressed on a small subset of highly proliferative memory B-cells in mucosal tissues (tonsils, Peyer's patches), where they are concentrated near and within the epithelial surfaces. FcRL4⁺ B-cells are rarely found in blood, spleen and peripheral lymph nodes.^{13,14} This association with the epithelium at mucosal sites is in concordance with the notion that FcRL4 is a receptor for IgA and strongly argues that FcRL4⁺ B-cells exert an important role in mucosal immune responses.¹⁵ In response to chronic antigen stimulation FcRL4 dampens activation by the B-cell receptor (BCR) and enhances innate Toll-like receptor (TLR) activation.^{15,16} Upon differentiation from FcRL4⁺ B-cells towards plasma cells, FcRL4 expression is lost. An increased number of FcRL4⁺ B-cells is found in reactive lymphadenitis caused amongst others by toxoplasmosis, HIV and mononucleosis.^{13,14} In the autoimmune disease rheumatoid arthritis, FcRL4⁺ B-cells are found in synovial fluid and synovial tissue, where they are located beneath the synovial lining and around blood vessels.¹⁷ In this study we assessed the presence and localization of FcRL4⁺ B-cells in salivary gland tissue of pSS and control patients as well as in pSS-associated MALT lymphomas.

MATERIAL AND METHODS

Patients

Salivary gland biopsies were collected from 54 patients diagnosed with pSS. All patients fulfilled the American-European Consensus Group (AECG) criteria for pSS and were selected because they had not developed a malignant lymphoma during follow up (median 9.2 year, IQR 4.4–12.6 year). Thirty biopsies were taken from the parotid gland and 24 from the minor salivary (labial) glands. As controls served parotid gland biopsies (n=8) and labial gland biopsies (n=8) obtained from non-pSS sicca patients (complaints of dryness, not fulfilling the AECG criteria). Clinical data of the pSS patients and sicca patients are presented in table 1. Furthermore, 5 parotid glands from individuals with no complaints of dryness were included in this study. Of these five patients, who had undergone surgery for pleomorph adenoma (n=3) or warthin tumor (n=2) the resection margins of the parotid gland were used. To explore whether FcRL4⁺ cells are affected by rituximab or abatacept, parotid gland biopsies from pSS patients enrolled in the placebo-controlled rituximab trial (18 rituximab, 9 placebo)^{18,19} and open label abatacept study (n=15)^{20,21} were also analyzed.

In addition, tissue samples from the parotid gland of 49 pSS patients diagnosed with parotid MALT lymphomas were obtained. These pSS patients were either diagnosed or referred for parotid MALT lymphoma at the University Medical Center Groningen (supplementary Figure 1). Biopsy material stored at other hospitals was requested for re-evaluation. Clinical data at time of diagnosis of MALT lymphoma are presented in table 1. From 10 parotid MALT lymphoma patients, a diagnostic labial salivary gland biopsy (for the diagnosis of pSS) prior to lymphoma development was available for analysis as well.

Histological evaluation of salivary gland biopsies

Hematoxylin and eosin (HE) stained sections were used to assess focus score (FS) and presence of LELs. FS was based on the number of periductal infiltrates of ≥ 50 lymphocytes (foci)/4 mm² parenchyma. In case of multiple large confluent foci an arbitrary maximal FS of 12 was used (1 pSS patient).²² LELs were defined as a cross section of a striated duct with infiltration of lymphocytes within the contour of the basement membrane combined with hyperplasia of the ductal epithelium.¹⁹

Immunohistochemical staining for FcRL4

Formalin fixed (4%), paraffin embedded tissue samples were sectioned at 4 μ m thickness and deparaffinized. After antigen retrieval in 1mM EDTA pH8.0, 98°C, 15 minutes and blocking of endogenous peroxidase (0.3% H₂O₂) slides were incubated for 75 minutes with a culture supernatant of monoclonal mouse-anti-human FcRL4 antibody produced and generously provided by Profs. Pileri and Falini (Bologna and Perugia, Italy)¹³ diluted in PBS/1%BSA. After incubation with a horseradish peroxidase (HRP) labeled secondary

antibody (Real™EnVision™ Detection System, DAKO) FcRL4 was visualized with DAB (3,3' diaminobenzidine). As negative (isotype) control an irrelevant IgG2a mouse monoclonal antibody (clone C1.18.4, BD Biosciences) was used (Supplementary Figure 2). Parotid MALT lymphomas were considered positive if there was detectable FcRL4, expressed by at least 5% of the lymphoma B-cells. To quantify FcRL4 expression in salivary gland biopsies, the relative area of FcRL4 staining was measured with Aperio ImageScope software (algorithm positive pixel count v9 (v12.0)). Thresholds of negative and positive pixels were manually corrected for each slide minimizing false positive pixels from non-specific background staining. FcRL4 staining was evaluated in the glandular parenchyma only excluding interparenchymal connective- and fatty tissue.

Phenotype and proliferative capacity of FcRL4⁺ cells

Dual staining for FcRL4 in combination with transcription factors Pax5, Bcl6, Blimp1 (PRDM1) and Mum1 (IRF4) or proliferation marker Ki-67 (supplementary table 1) was performed using the MultiVision Polymer Detection System (ThermoScientific) according to manufacturers manual. After deparaffinization, antigen retrieval and endogenous peroxidase blocking (see before) Ultra-V-block was applied. After incubation with primary antibodies in PBS/1%BSA for 75 minutes, MultiVision Polymer Cocktail was used. Staining for FcRL4 was visualized by LVRed (HRP conjugated anti-mouse IgG) and the transcription factor or proliferation marker by LVBlue (alkaline phosphatase conjugated anti-rabbit IgG).

mRNA-isolation and qPCR of FcRL4

From 11 pSS patients with parotid MALT lymphomas, 9 pSS patients without a lymphoma and 8 non-pSS sicca patients frozen parotid biopsies were available. Total mRNA was extracted using the Absolutely RNA Microprep Kit (Agilent Technologies) according to instructions of the manufacturer. After DNase treatment, cDNA was synthesized using Oligo dT12-18's and M-MLV Reverse Transcriptase (Thermo-Fisher Scientific). A qPCR for FcRL4 expression was carried out on the CFX384 Touch Real-Time PCR detection system (BioRad) using SYBR green supermix (BioRad) using primer sets for β -actin: 5' GAGCGGGAAATCGTGCGTGAC-3' (forward), 5' AGGAAGGAAGGCTGGAAGAGTGC-3' (reverse) and FcRL4: 5'-GGGCGTCCTTGCTGGCCTTT-3' (forward), 5' GGGTGTTTCCTGGGGTCAGGGT-3' (reverse). Experiments were carried out in duplicate. Gene expression was normalised to β -actin expression.

Statistical analysis

Wilcoxon Signed Rank, Mann-Whitney U were used when appropriate to test differences between parameters. Spearman's correlation coefficient was calculated for testing correlations (IBM SPSS Statistics V.22).

Table 1: Characteristics of pSS patients diagnosed with parotid MALT lymphoma, pSS patients and non-pSS sicca patients

Variable	pSS parotid (n=30)	Sicca parotid (n=8)	pSS labial (n=24)	Sicca labial (n=8)	pSS parotid MALT lymphoma (n=49)	pSS pre- lymphoma labial (n=10)
Patient characteristics						
Age year diagnose, median (IQR)	47 (33-62) ¹	56 (46-64) ¹	56 (38-68) ¹	44 (40-62) ¹	53 (43-64) ²	46 (32-61) ¹
Female, n(%)	30 (100%)	7 (88%)	22 (92%)	7 (88%)	45 (92%)	10 (100%)
ΔpSS-MALT lymphoma year, mean ±SD	-	-	-	-	2.6 ±5.13	5.3 ±1.5
Ann Arbor / Musshoff stage*						
Localized disease, n(%)	-	-	-	-	29 (59%)	-
Locally disseminated, n(%)	-	-	-	-	19 (39%)	-
Disseminated disease, n(%)	-	-	-	-	1 (2%)	-
Laboratory assessments						
SSA positive, n(%)	26 (87%)	0 (0%) ^a	20 (83%)	1 (13%)	43 (92%) ^d	10 (100%)
SSB positive, n(%)	17 (57%)	0 (0%) ^a	9 (38%)	0 (0%)	32 (68%) ^d	6 (60%)
RF elevated, n(%)	25(83%)	0 (0%) ^b	14 (61%) ^c	0 (0%)	44 (94%) ^d	10 (100%)
ANA positive, n(%)	26 (87%)	3(43%) ^a	22 (96%) ^c	3 (38%)	46 (98%) ^d	10 (100%)
Histopathological parameters						
Focus score, median (IQR)	2.4 (1.8-3.7)	0 (0-0.7)	2.9 (1.6-4.2)	0 (0-0.5)	-	-
Presence LELs, n(%)	28 (93%)	0 (0%)	8 (33%)	0 (0%)	48 (98%)	4 (40%)

Between the pSS patients with a labial gland biopsy and pSS patients with a parotid gland biopsy there was no significant differences in age at time of pSS diagnosis. *Staging of parotid MALT lymphoma based on the Ann Arbor classification with modification by Musshoff.^{35,36} Localized disease: lymphoma located in one or more salivary glands. Locally disseminated: lymphoma localized in one or more salivary glands with one or more enlarged regional lymph nodes (>1cm). Disseminated disease: localization of lymphoma in one or more salivary glands, with one or more enlarged regional lymph nodes (>1cm) and/or bone marrow, spleen, liver or other extra nodal site than the salivary gland, or localization of lymphoma in multiple extra nodal sites. ¹age at diagnosis of pSS or non-pSS sicca, ²age at diagnosis of MALT lymphoma, ³n=7, ⁴n=6, ⁵n=23, ⁶n=47. LELs: lymphoepithelial lesions, IQR: Interquartile range.

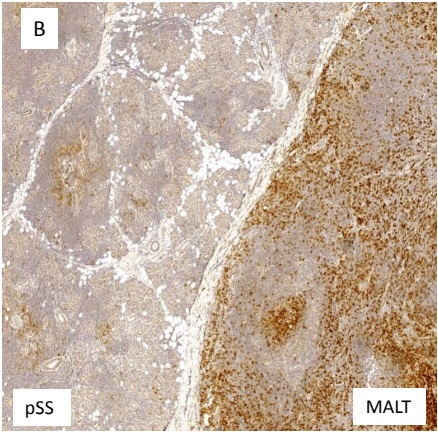
RESULTS

FcRL4⁺ cells are present in salivary gland tissue of pSS patients

FcRL4 positive (FcRL4⁺) cells were clearly present in nearly all parotid gland biopsies (29/30, 97%) and in the majority of labial (17/24, 71%) gland biopsies of pSS patients at the time of pSS diagnosis (Figure 1 and Supplementary Figure 2). Compared to the overall lymphocyte population in the glandular tissue of pSS patients, the numbers of FcRL4⁺ cells (as expressed by relative surface areas stained by the antibody) were relatively low but varied between patients. Remarkably, in pSS patients the numbers of FcRL4⁺ cells were significantly higher in parotid gland tissue than in labial gland tissues ($p=0.003$, Figure 1H). Furthermore, the intensity of the FcRL4 staining was higher in parotid gland tissue compared to labial gland tissue. In pSS patients, the majority of FcRL4⁺ cells was located within LELs of the salivary glands and a smaller fraction in the periductal infiltrate, mostly in close proximity to the epithelium. FcRL4 staining intensity was highest within the LELs. All LELs contained FcRL4⁺ cells, even if LELs were very small, i.e., LELs with only few infiltrating lymphocytes and minimal reactive epithelial changes. FcRL4⁺ cells were absent from parotid gland tissue of patients without sicca complaints ($n=5$, data not shown). They could also not be observed in labial gland biopsies and in the majority of parotid gland biopsies of non-pSS sicca patients.

Measurement of FcRL4 transcript levels by qRT-PCR confirmed the expression of FcRL4 protein in salivary gland biopsies of pSS patients and their virtual absence in non-pSS sicca patients (Figure 2).

As shown in Figure 1H there is a wide variety in numbers of FcRL4⁺ cells in parotid glands of pSS patients and there are patients with high levels and patients with low levels of FcRL4⁺ cells. There is a tendency that patients with autoantibodies (anti-SSA, anti-SSB, RF, ANA) have higher levels of FcRL4⁺ cells compared to patients with lower levels of FcRL4⁺ cells (supplementary Figure 3).



A) Quantitative PCR analysis of FcRL4 in parotid gland biopsies showed an increase of FcRL4 mRNA expression in pSS patients and pSS parotid MALT lymphoma patients compared to sicca patients. The MALT lymphoma that was negative for FcRL4 by immunohistochemistry is indicated. **B)** FcRL4 staining of the parotid gland from a pSS patient with an expansive MALT lymphoma. Difference in FcRL4 staining between glandular tissue (pSS, left side) and MALT lymphoma (MALT, right side) is clearly visible. Counterstain with hematoxylin. *Mann-Whitney U, $p < 0.05$.

Dual staining for FcRL4 and the B-cell associated transcription factor Pax5 revealed that virtually all FcRL4⁺ cells express Pax5, and thus represent B-cells. Dual staining with FcRL4 and other transcription factors expressed during B-cell differentiation showed that FcRL4⁺ cells did not express Bcl6, a transcription factor highly expressed by GC B-cells, nor PRDM1 and IRF4 which are both associated with plasma cell differentiation (Figure 3). Transcription factor expression profiles of the FcRL4⁺ cells were similar in both parotid and labial salivary gland tissue.

A high percentage of FcRL4⁺ B-cells in the LELs of the parotid gland (mean 20.5%, $\pm 7.7\%$) and labial gland (mean 15.4 $\pm 8.2\%$) express Ki-67, a marker expressed by cells that are not in the G₀ phase of the cell cycle. In the periductal infiltrate lower percentage of FcRL4⁺ B-cells express Ki-67 (parotid gland; mean 13.8%, $\pm 4.6\%$ and labial gland; mean 10.5%, $\pm 3.8\%$, Figure 3). Thus, a significant proportion of the FcRL4⁺ B-cells are actively dividing cells, especially within LELs.

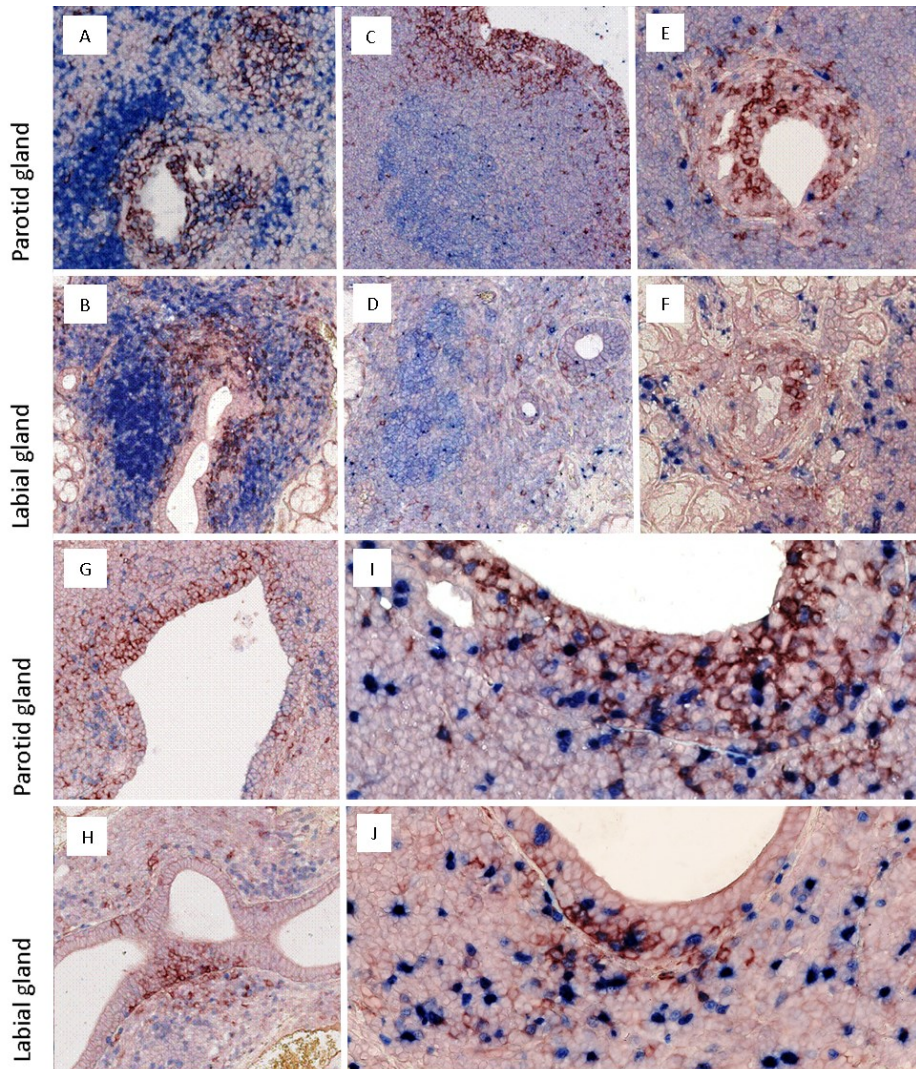


Figure 3: FcRL4⁺ cells are proliferative B-cells without signs of plasma cell differentiation.

Double staining for FcRL4 (brown) versus other proteins (blue). FcRL4⁺ B-cells in the parotid gland and the labial gland have a similar phenotype. **A,B**) FcRL4⁺ cells express Pax5. **C,D**) FcRL4⁺ cells do not express the germinal center B-cell associated transcription factor Bcl6. **E,F**) The transcription factor Mum1 is not expressed by FcRL4⁺ B-cells **G,H**) nor the transcription factor Blimp1, both associated with terminally differentiated plasma cells. **I,J**) FcRL4⁺ cells are proliferative cells. FcRL4⁺ Ki-67⁺ B-cells in the parotid and labial gland are found within the lymphoepithelial lesions and fewer in the parenchymal infiltrate.

FcRL4⁺ B-cells correlate with presence of LELs and CD20⁺ B-cells

Histopathological analysis of parotid and labial salivary gland biopsies of pSS patients revealed that the focus score (FS) is comparable between these two types of salivary glands, but that the number of LELs is higher in parotid glands than in labial glands (Table 1). Accordingly and as noted before, also the numbers of FcRL4⁺ B-cells, which are mostly located in or near LELs were higher in parotid glands. When we divided parotid and labial salivary gland biopsies each into two groups, one group with LELs and the other without LELs, significantly more FcRL4⁺ cells were present in salivary gland biopsies with LELs (Figure 4A, 4B).

Previously, we evaluated (i.e., pre-treatment) baseline numbers of LELs/mm² and CD20⁺ B-cells/mm² in parotid gland biopsies of pSS patients enrolled in the rituximab and abatacept studies.^{19,21} As we show here, there was a strong correlation between FcRL4 expression and number of LELs/mm² (Spearman $\rho=0.559$, $p<0.001$) and between FcRL4 expression and number of CD20⁺ B-cells/mm² (Spearman $\rho=0.588$, $p<0.001$, Figure 4C, 4D) in the pre-treatment biopsies of these patients ($n=42$). In contrast, there was no correlation between FcRL4 expression and FS (Figure 4E).

FcRL4⁺ B-cells are reduced after rituximab, not by abatacept

To study the effect of in-vivo B-cell depletion and blocking of T-cell co-stimulation on FcRL4⁺ B-cells, we compared pre-treatment and post-treatment parotid gland biopsies in the rituximab ($n=18$ rituximab and $n=9$ placebo) and abatacept ($n=15$) studies. Rituximab but not placebo, not only effectively reduced the number of CD20⁺ B-cells and LELs in parotid gland biopsies 12 weeks after treatment¹⁹ but also the numbers of FcRL4⁺ B-cells ($p=0.001$, Figure 5). Similar to the absence of any effect on the numbers of B-cells or LELs, FcRL4⁺ B-cells were not reduced by abatacept treatment ($p=0.163$, Figure 5) 24 weeks after treatment.²¹

FcRL4 expression is preserved in pSS associated parotid MALT lymphomas

Immunohistochemistry revealed that 47/49 (96%) of pSS-associated parotid MALT lymphomas expressed FcRL4. This is similar to other extra-nodal marginal zone lymphomas in general.¹¹ The FcRL4⁺ cells cluster in and around LELs and in the marginal zone (Figure 1). Both the number of FcRL4⁺ cells and the intensity of FcRL4 staining varied between cases.

Quantitative RT-PCR (qRT-PCR) analysis of the 11 parotid MALT lymphomas from which frozen material was available, including one specimen that did not exhibit detectable levels of FcRL4 by immunohistochemistry, revealed that, in contrast to sicca control patients ($n=8$) and pSS patients ($n=9$), FcRL4 transcripts were detectable in all lymphomas. The lowest mRNA level was found in the pSS patient with the immunohistochemical FcRL4 negative MALT lymphoma. As expected, FcRL4 transcript levels were significantly higher in parotid glands from pSS patients with MALT lymphoma compared to parotid biopsies obtained from pSS patients without lymphoma ($p=0.017$, Figure 2).

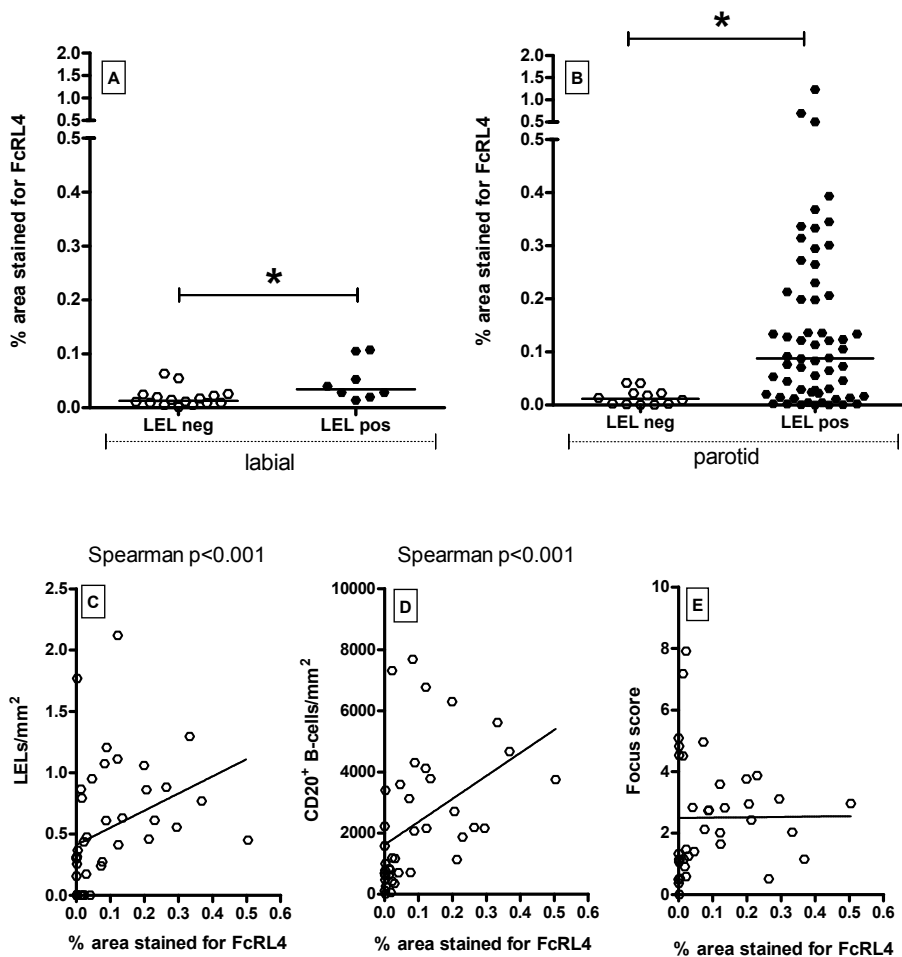


Figure 4: FcRL4⁺ B-cells are associated with LELs.

A) FcRL4⁺ B-cells in labial gland biopsies (n=24) are enriched in biopsies harboring LELs (33%). **B)** In parotid gland biopsies FcRL4⁺ B-cells are also significantly increased in biopsies harboring LELs (n=72, including baseline biopsies of the rituximab and abatacept trials). In total 83% of the parotid gland biopsies were positive for LELs. **C-E)** FcRL4 positivity in parotid gland biopsies (n=42, baseline rituximab and abatacept trials) is correlated with number of LELs/mm² (p = 0.559) and numbers of CD20⁺ B-cells/mm² (p = 0.588) glandular parenchyma. Focus score did not correlate with FcRL4. *Mann-Whitney U, p<0.05.

FcRL4 expression in pre-lymphoma labial gland biopsies

The 10 labial gland biopsies from pSS patients taken at time of pSS diagnosis, but prior (mean 5.3 ± 1.5 years) to parotid MALT lymphoma development, did not differ in numbers of FcRL4⁺ cells (as reflected by the relative surface area of FcRL4 staining) compared to labial biopsies of pSS patient without lymphoma development (p=0.360, Figure 1). Although at the group

level there was thus no significant difference, two pre-lymphoma pSS patients clearly had an elevated expression of FcRL4 in their diagnostic labial gland biopsy. Time between labial biopsy and parotid MALT lymphoma was 73 months and 4 months respectively in these patients.

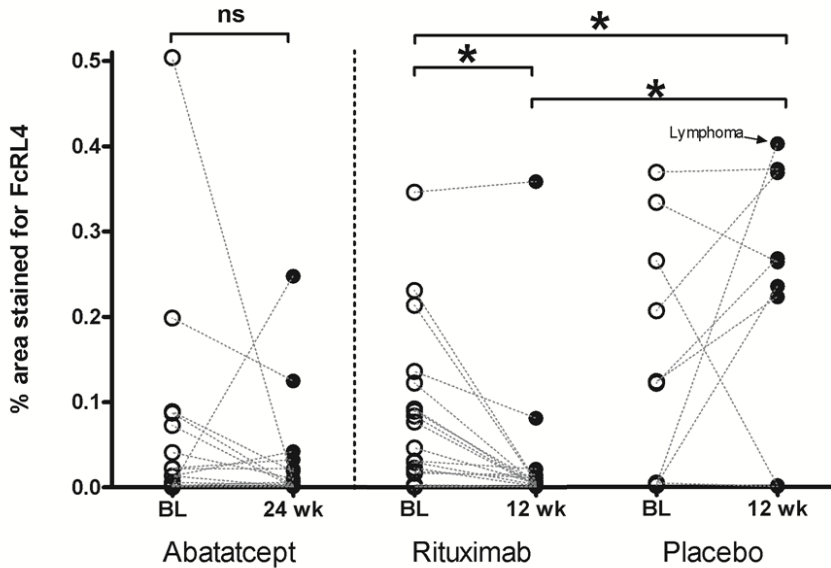


Figure 5: FcRL4⁺ B-cells are targeted by rituximab, not by abatacept.

Amount of FcRL4 staining is reduced after rituximab therapy in pSS patients. FcRL4⁺ B-cells located within the ductal epithelium and those located in the infiltrates that surrounds the ducts were depleted. The placebo group remained stable. As indicated, one placebo treated patient developed a lymphoma. Abatacept treatment of pSS patients did not affect the amount of FcRL4 staining. There was no significant difference in FcRL4 staining between baseline biopsies (BL) of abatacept trial and rituximab trial. All biopsies were taken from the parotid gland. Of note, follow up time of post-treatment biopsies varies between the studies since mode of action of these therapeutic biologicals differs.^{18,20} *Wilcoxon Signed Rank, $p < 0.05$.

DISCUSSION

In this study we show for the first time that FcRL4⁺ cells are present in the inflamed salivary glands of pSS patients. They are associated with the ductal epithelium forming LELs. Within these structures FcRL4⁺ cells are actively dividing. Strikingly, the number of FcRL4⁺ cells is much higher in parotid gland tissue than labial gland tissue. The transcription factor profile of FcRL4⁺ cells in both types of salivary glands reveals that these cells express Pax5, but not Blimp1, Mum1 or Bcl6. Thus, FcRL4⁺ cells in salivary gland tissue of pSS patients are highly proliferative genuine B-cells that have not differentiated towards plasma cells.

In healthy individuals the FcRL4⁺ B-cells are mostly found at mucosal sites within or in close proximity of epithelial linings.¹³ These cells have also been found in the target tissues of patients with autoimmune disease. In rheumatoid arthritis patients FcRL4⁺ B-cells were present in the synovia, beneath the synovial lining and around blood vessels.¹⁷ Our study shows that also in the salivary glands of pSS patients FcRL4⁺ B-cells have a clear association with the epithelium. This association is maintained in pSS-associated parotid MALT lymphomas, emphasizing the importance of the interaction of ductal epithelial cells and FcRL4⁺ B-cells. The ductal epithelial cells in pSS salivary gland parenchyma produce a wide variety of chemokines including CCL3/MIP-1 α and CCL5/RANTES.²³ These chemokines are ligands for the chemokine receptors CCR1 and CCR5 respectively, which are expressed at elevated levels by FcRL4⁺ B-cells present in the peripheral blood of healthy individuals.^{14,17} These, and other not yet identified chemokine-chemokine receptor interactions can contribute to homing and retention of FcRL4⁺ B-cells to inflamed salivary glands, and more specifically to the ductal epithelium. Differences in chemokine expression levels between ductal epithelial cells of labial and parotid glands may account for the higher numbers of FcRL4⁺ B-cells seen in parotid glands compared to labial glands of pSS patients.

Labeling with Ki-67 indicates that FcRL4⁺ B-cells of the salivary glands are highly proliferating cells. Approximately 15-20% of FcRL4⁺ B-cells in LELs of pSS patients are in cell cycle as determined immunohistochemical by Ki-67. In line with our findings in salivary glands of pSS patients, previous studies demonstrated (using immunofluorescence staining for Ki67, FACs and transcriptome analysis for Ki67) that a relative high fraction (5-43%) of tonsillar FcRL4⁺ (memory) B-cells are not in G₀ phase.^{13,24} In comparison, only a few percent of tonsillar memory cells not expressing FcRL4, are actively dividing.²⁴ Gene expression profiling studies further revealed that tonsillar FcRL4⁺ B-cells indeed overexpress several genes involved in the regulation of entry and progression through the cell cycle including Ki-67.²⁴

FcRL4⁺ B-cells fail to proliferate in response to BCR signaling, whereas signaling through innate pathways, for instance by TLRs, is enhanced.^{14,16,25} Sohn et al, observed that BCR signaling was attenuated and TLR9 activation by unmethylated CpG was enhanced in FcRL4⁺ transfected Ramos B-cells.¹⁶ Based upon these findings they speculated that FcRL4 signaling may act as a molecular switch to dampen adaptive signaling and enhance innate signaling in response to chronic (antigenic) stimulation. Zheng et al, reported that lymphocytes residing within LELs of parotid gland tissue from pSS patients express more TLR9 as compared to controls.²⁶ As epithelial cells in pSS are intrinsically more sensitive for cell death²⁷ they may deliver ligands for TLR activation such as nucleic acids containing particles. In addition, in pSS, ductal cells produce a wide variety of cytokines,²⁸ which can contribute to the activation of the FcRL4⁺ B-cells, particularly intraepithelial FcRL4⁺ B-cells expressing the highest levels of FcRL4. In this manner, ductal epithelial cells might be responsible for signals that lead to sustained activation and proliferation of FcRL4⁺ B-cells.

The epithelium may not only influence activation of FcRL4⁺ B-cells, but in turn the epithelium may also be affected by FcRL4⁺ B-cells. Indeed, the higher number (and severity of LELs) seen in parotid gland tissue compared to the labial gland tissue may be attributed to the higher number of infiltrating FcRL4⁺ B-cells. After appropriate stimulation, B-cells are able to secrete a wide variety of cytokines²⁹ and these cytokines may affect the epithelium. Intestinal epithelial cells, for example, are stimulated to proliferate by pro-inflammatory cytokines such as IL-6 derived from intraepithelial lymphocytes.^{5,30} Similarly, cytokines produced by FcRL4⁺ B-cells, may induce proliferation and differentiation of the epithelium, subsequently leading to formation of LELs. The impact of FcRL4⁺ B-cells on the ductal cells is further substantiated by our findings in parotid gland tissue of pSS patients treated with rituximab. FcRL4⁺ B-cells have strong expression of CD20 making them highly susceptible targets for rituximab therapy.^{13,14,17} Treatment with rituximab did not only reduce the total number of B-cells, but also reduced intraepithelial FcRL4⁺ B-cells. This resulted not only in a significant decrease in the number of LELs, but also normalization of the epithelial lining.^{19,31} Apparently, when FcRL4⁺ B-cells are depleted from the epithelium, stimulation of ductal cells by FcRL4⁺ B-cells is no longer present, enabling restoration of epithelium. Of note, blocking the CD28 mediated co-stimulation with abatacept did not affect the presence of (intraepithelial) FcRL4⁺ B-cells, and concomitantly also not the numbers and severity of LELs.²¹ Thus, in pSS patients a crosstalk between ductal epithelial cells and FcRL4⁺ B-cells is likely to exist and play a significant role in the formation of LELs.

In line with previous reports on extra-nodal marginal zone lymphomas in general,¹¹ we showed that the vast majority, if not all, of the parotid MALT lymphomas of pSS patients express FcRL4. FcRL4 mRNA expression in parotid MALT lymphomas is clearly increased as compared to pSS patients without MALT lymphoma indicating an expansion of FcRL4⁺ B-cells. Similar to the association of non-malignant FcRL4⁺ B-cells with the ductal epithelium of the glandular tissue of pSS patients, the majority of malignant FcRL4⁺ B-cells of parotid MALT lymphomas is located within or in close proximity with the ductal epithelium that forms LELs. The region of these LELs is also the region in which early expansion of neoplastic cells takes place in MALT lymphomas.⁹ Apparently, neoplastic FcRL4⁺ B-cells maintain their association with epithelium in parotid MALT lymphomas, emphasizing the importance of the interaction between epithelial cells and FcRL4⁺ B-cells.

In pSS patients MALT lymphomas preferentially develop in parotid salivary glands, and less frequent in other major and labial salivary glands.³² Presently, we do not know the lymphoma stem cells from which the clonal expansion derives. One possibility is that they reside within the compartment of mature B-cells from which the FcRL4⁺ B-cells derive and that the expansion of these FcRL4⁺ B-cells is due to the interaction with specific epithelial features within the parotid glands. Another possibility might be that the FcRL4⁺ B-cells themselves are directly targeted and become neoplastic. The high proliferative capacity of FcRL4⁺ B-cells in the ductal epithelium makes them prone for malignant transformation.

Moreover, tonsillar FcRL4⁺ B-cells exhibit an increased gene expression of activation induced deaminase (AID) compared to FcRL4 negative B-cells.²⁴ This gene encodes for an enzyme that converts C to U in DNA and is typically expressed in germinal center B-cells for initiation of both class switch recombination and somatic hypermutation but can also target non-immunoglobulin genes.³³ AID is therefore potentially mutagenic and may cause genomic instability.³⁴

Numbers of FcRL4⁺ B-cells vary between pSS patients, and part of the pSS patients appears to have higher numbers of these cells. As shown, pSS patients with autoantibodies appear to have higher levels of these cells in the glandular tissue. Further analysis in prospective studies is needed to see whether patients with the higher numbers of parotid gland FcRL4⁺ B-cells represent a distinct subgroup of patients and/or are the result of higher disease activity. However, at the group level the number of FcRL4⁺ cells in pre-lymphoma labial gland biopsies did not differ from the numbers seen in biopsies from pSS patients that did not develop lymphoma. In two pre-lymphoma labial gland biopsies high numbers of FcRL4⁺ cells were present. Whether these elevated numbers of FcRL4⁺ cells are clonally expanded B-cells with neoplastic potential, seeding from the parotids glands to the labial glands or vice versa, remains to be seen. Since high expression of FcRL4 was not seen in any of the labial gland biopsies of pSS patients without lymphoma development, increased FcRL4 expression in the labial gland biopsy might indicate that a pSS patient is at risk for parotid MALT lymphoma development.

In summary, FcRL4⁺ B-cells are present in pSS salivary glands in close association with the ductal epithelium forming LELs. Herewith these cells may play an important role in the pathogenesis of pSS, reduced saliva production and destruction of the glands. Furthermore, enrichment of parotid gland tissue with highly proliferative intraepithelial FcRL4⁺ B-cells provides a plausible explanation why MALT lymphomas predominantly develop in parotid glands rather than labial glands. Treatment with rituximab reduces FcRL4⁺ B-cells, interrupting the interaction between these cells and ductal cells enabling the epithelium to restore. Targeting of FcRL4⁺ B-cells in pSS patients might be explored for treatment of pSS patients in general, and more specifically for the treatment of pSS patients who are at risk for the development for parotid MALT lymphomas.

ACKNOWLEDGMENTS

The authors greatly thank Prof. S. Pileri and Prof. B. Falini (Bologna and Perugia, Italy) for generously providing the FcRL4 antibody. We also thank the following pathology departments from the Netherlands for providing residual biopsy material: Pathology Friesland (Leeuwarden), Laboratory Pathology Eastern-Netherlands (Hengelo), Pathology Isala Clinics (Zwolle), Pathology Rijnstate (Arnhem), Pathology Onze Lieve Vrouwe Gasthuis (Amsterdam) Pathology Martini Hospital (Groningen), Pathology University Medical Center Utrecht (Utrecht) and Laboratory Pathology and Medical Microbiology (Eindhoven). Additionally we thank Dr. R. Westra (rheumatologist) for providing clinical information about pSS patients treated at the Scheper Hospital (Emmen, The Netherlands).

Funding: This work was supported by the Dutch Arthritis Foundation, Amsterdam, the Netherlands [grant number 2013-2-066]. Clinical treatment studies described were supported by Bristol-Myers Squibb, Rueil Malmaison, France (abatacept) and Roche, Woerden, The Netherlands (rituximab). There was no involvement of these funding sources in study design, data collection, analysis and interpretation and writing of this report.

Ethics approval: Institutional Review Board of the University Medical Center Groningen (METc 2014.211).

REFERENCES

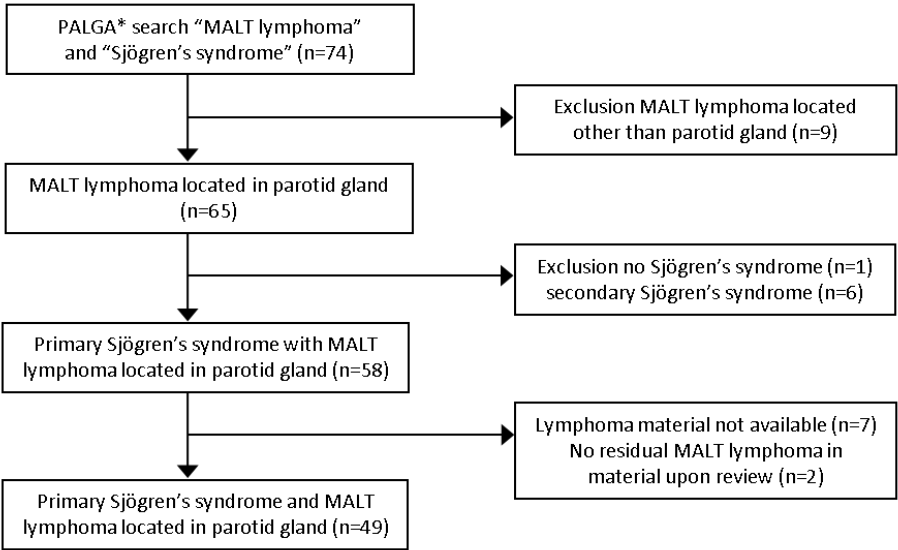
1. Brito-Zerón P, Baldini C, Bootsma H, et al. Sjögren syndrome. *Nat Rev Dis Prim* 2016;2:1-20.
2. Christodoulou MI, Kapsogeorgou EK, Moutsopoulos HM. Characteristics of the minor salivary gland infiltrates in Sjögren's syndrome. *J Autoimmun* 2010;34:400-07.
3. Ihrler S, Zietz C, Sendelhofert A, et al. Lymphoepithelial duct lesions in Sjögren-type sialadenitis. *Virchows Arch* 1999;434:315-23.
4. Pijpe J, Kalk WWI, van der Wal JE, et al. Parotid gland biopsy compared with labial biopsy in the diagnosis of patients with primary Sjögren's syndrome. *Rheumatology (Oxford)* 2007;46:335-41.
5. Kroese FGM, Abdulahad WH, Haacke E, et al. B-cell hyperactivity in primary Sjögren's syndrome. *Expert Rev Clin Immunol* 2014;10:483-99.
6. Giannouli S, Voulgarelis M. Predicting progression to lymphoma in Sjögren's syndrome patients. *Expert Rev Clin Immunol* 2014;10:501-12.
7. Voulgarelis M, Ziakas PD, Papageorgiou A, et al. Prognosis and outcome of non-Hodgkin lymphoma in primary Sjögren syndrome. *Medicine (Baltimore)* 2012;91:1-9.
8. Nocturne G, Boudaoud S, Miceli-Richard C, et al. Germline and somatic genetic variations of TNFAIP3 in lymphoma complicating primary Sjögren's syndrome. *Blood* 2013;122:4068-76.
9. Isaacson PG, Norton AJ. Extranodal Lymphomas. *Churchill Livingstone*; 1994.
10. Bacon CM, Du M-Q, Dogan A. Mucosa-associated lymphoid tissue (MALT) lymphoma: a practical guide for pathologists. *J Clin Pathol* 2007;60:361-72.
11. Falini B, Agostinelli C, Bigerna B, et al. IRTA1 is selectively expressed in nodal and extranodal marginal zone lymphomas. *Histopathology* 2012;61:930-41.
12. Masaki Y, Sugai S. Lymphoproliferative disorders in Sjögren's syndrome. *Autoimmun Rev* 2004;3:175-82.
13. Falini B, Tiacci E, Pucciarini A, et al. Expression of the IRTA1 receptor identifies intraepithelial and subepithelial marginal zone B cells of the mucosa-associated lymphoid tissue (MALT). *Blood* 2003;102:3684-92.
14. Ehrhardt GR, Hsu JT, Gartland L, et al. Expression of the immunoregulatory molecule FcRH4 defines a distinctive tissue-based population of memory B cells. *J Exp Med* 2005;202:783-91.
15. Wilson TJ, Fuchs A, Colonna M. Cutting edge: human FcRL4 and FcRL5 are receptors for IgA and IgG. *J Immunol*. 2012;188:4741-45.
16. Sohn HW, Krueger PD, Davis RS, et al. FcRL4 acts as an adaptive to innate molecular switch dampening BCR signaling and enhancing TLR signaling. *Blood* 2011;118:6332-41.
17. Yeo L, Lom H, Juarez M, et al. Expression of FcRL4 defines a pro-inflammatory, RANKL-producing B cell subset in rheumatoid arthritis. *Ann Rheum Dis* 2015;74:928-35.
18. Meijer JM, Meiners PM, Vissink A, et al. Effectiveness of rituximab treatment in primary Sjögren's syndrome: a randomized, double-blind, placebo-controlled trial. *Arthritis Rheum* 2010;62:960-68.
19. Delli K, Haacke EA, Kroese FGM, et al. Towards personalised treatment in primary Sjögren's syndrome: baseline parotid histopathology predicts responsiveness to rituximab treatment. *Ann Rheum Dis* 2016;75:1933-38.
20. Meiners PM, Vissink A, Kroese FGM, et al. Abatacept treatment reduces disease activity in early primary Sjögren's syndrome (open-label proof of concept ASAP study). *Ann Rheum Dis* 2014;73:1393-96.
21. Haacke EA, van der Vegt B, Meiners PM, et al. Abatacept treatment of patients with primary Sjögren's syndrome results in a decrease of germinal centres in salivary gland tissue. *Clin Exp Rheumatol* 2017;35:317-20.
22. Greenspan JS, Daniels TE, Talal N, et al. The histopathology of Sjögren's syndrome in labial salivary gland biopsies. *Oral Surg Oral Med Oral Pathol* 1974;37:217-29.
23. Cuello C, Palladinetti P, Tedla N, et al. Chemokine

- expression and leucocyte infiltration in Sjögren's syndrome. *Br J Rheumatol* 1998;37:779-83.
24. Ehrhardt GR a, Hijikata A, Kitamura H, et al. Discriminating gene expression profiles of memory B cell subpopulations. *J Exp Med* 2008;205:1807-17.
 25. Guerrier T, Le Pottier L, Devauchelle V, et al. Role of Toll-like receptors in primary Sjögren's syndrome with a special emphasis on B-cell maturation within exocrine tissues. *J Autoimmun* 2012;39:69-76.
 26. Zheng L, Zhang Z, Yu C, et al. Expression of Toll-like receptors 7, 8, and 9 in primary Sjögren's syndrome. *Oral Surg Oral Med Oral Pathol Oral Radiol Endod* 2010;109:844-50.
 27. Polihronis M, Tapinos NI, Theocharis SE, et al. Modes of epithelial cell death and repair in Sjögren's syndrome (SS). *Clin Exp Immunol* 1998;114:485-90.
 28. Manoussakis MN, Kapsogeorgou EK. The role of intrinsic epithelial activation in the pathogenesis of Sjögren's syndrome. *J Autoimmun* 2010;35:219-24.
 29. Lund FE. Cytokine-producing B lymphocytes-key regulators of immunity. *Curr Opin Immunol* 2008;20:332-38.
 30. Koch S, Nusrat A. The life and death of epithelia during inflammation: lessons learned from the gut. *Annu Rev Pathol* 2012;7:35-60.
 31. Pijpe J, Meijer JM, Bootsma H, et al. Clinical and histologic evidence of salivary gland restoration supports the efficacy of rituximab treatment in Sjögren's syndrome. *Arthritis Rheum* 2009;60:3251-56.
 32. Keszler A, Adler LI, Gandolfo MS, et al. MALT lymphoma in labial salivary gland biopsy from Sjögren syndrome: importance of follow-up in early detection. *Oral Surg Oral Med Oral Pathol Oral Radiol* 2013;115:e28-33.
 33. Matsumoto Y, Marusawa H, Kinoshita K, et al. *Helicobacter pylori* infection triggers aberrant expression of activation-induced cytidine deaminase in gastric epithelium. *Nat Med* 2007;13:470-76.
 34. Kumar R, DiMenna LJ, Chaudhuri J, et al. Biological function of activation-induced cytidine deaminase (AID). *Biomed J* 2014 ;37:269-83.
 35. Lister TA, Crowther D, Sutcliffe SB, et al. Report of a committee convened to discuss the evaluation and staging of patients with Hodgkin's disease: Cotswolds meeting. *J Clin Oncol* 1989;7:1630-36.
 36. Musshoff K. Clinical staging classification of non-Hodgkin's lymphomas (author's transl). *Strahlentherapie* 1977;153:218-21.

SUPPLEMENTARY MATERIALS

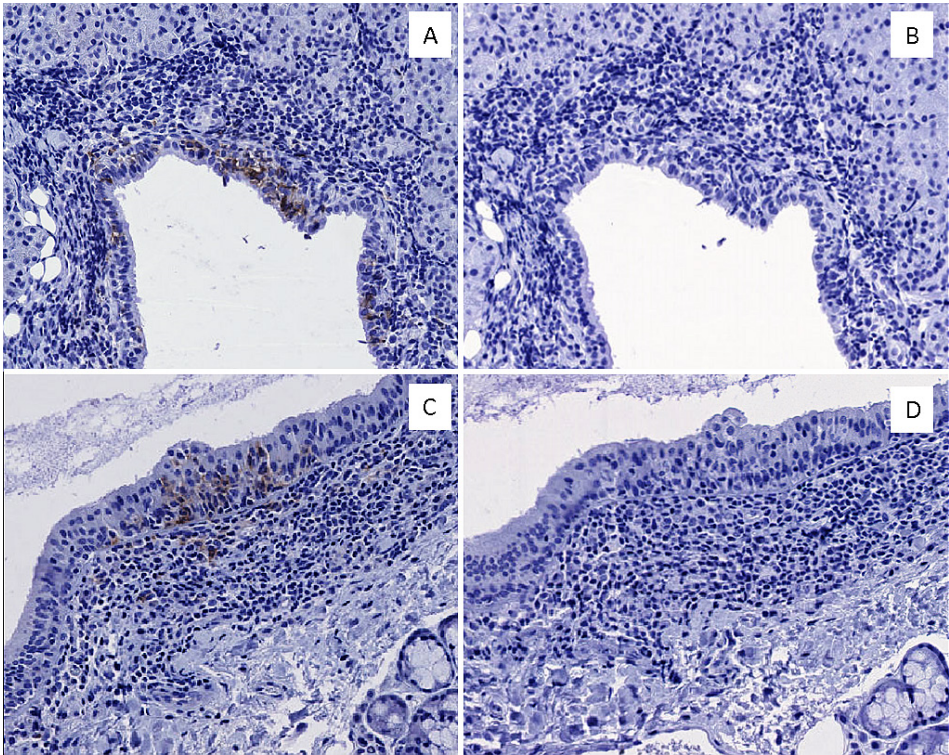
Supplementary Table 1: Antibodies used for immunohistochemistry.

Antigen	Clone	Host	Company
PAX5	SP34	Rabbit	Ventana Roche
BCL6	EPR11410-43	Rabbit	DAKO
BLIMP1	EPR16655	Rabbit	Abcam
MUM1	MRQ-43	Rabbit	Ventana Roche
Ki-67	SP6	Rabbit	Abcam



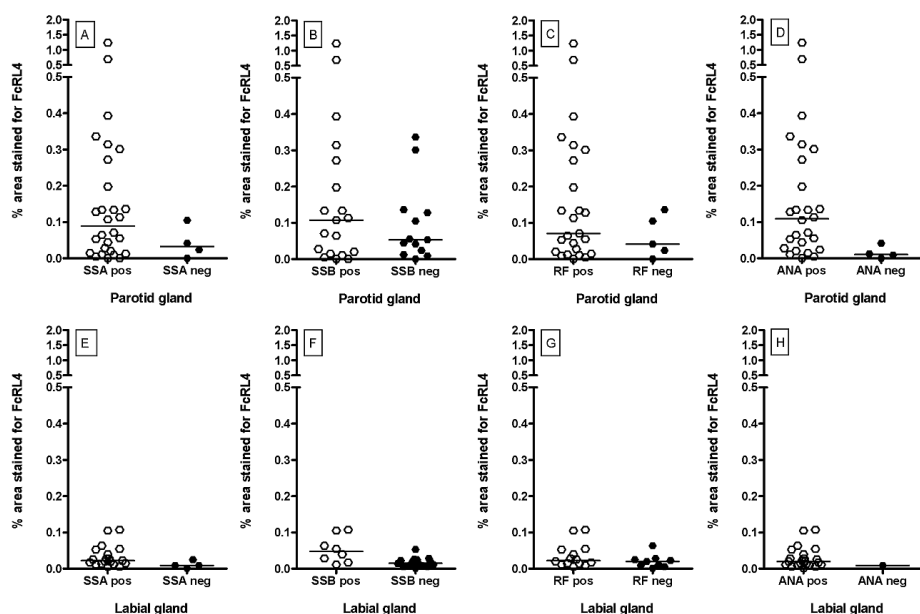
Supplementary Figure 1: Selection of pSS patients with parotid MALT lymphoma

A Pathology-Anatomy Nationwide Digital Archive (*PALGA) search was performed to identify all pSS patients diagnosed or revised with a parotid MALT lymphoma at the UMCG. Residual parotid MALT lymphoma biopsy material of pSS patients (n=49) from the following pathology departments was used; Pathology dept. University Medical Center Groningen, Groningen (n=36), Pathology dept. Friesland, Leeuwarden (n=7), Pathology dept. Isala Clinics, Zwolle (n=2), Laboratory Pathology dept. Eastern-Netherlands, Hengelo (n=1), Pathology dept. Onze Lieve Vrouwe Gasthuis, Amsterdam (n=1), Pathology dept. Martini Hospital, Groningen (n=1) and Pathology dept. University Medical Center Utrecht, Utrecht (n=1). *PALGA: Pathology-Anatomy Nationwide Digital Archive.



Supplementary Figure 2: Validity of the immunohistochemical FcRL4 staining.

Serial sections of a parotid gland biopsy from a pSS patient showing **A)** FcRL4⁺ cells in and surrounding a striated duct forming a lymphoepithelial lesion and **B)** negative IgG2a isotype control (clone C1.18.4, BD Biosciences). **C,D)** Serial sections of a labial gland biopsy from a pSS patient showing **C)** FcRL4⁺ cells in and surrounding a striated duct forming a small lymphoepithelial lesion and **D)** negative IgG2a isotype control.



Supplementary Figure 3: PSS patients with auto-antibodies tend to have high numbers of FcRL4⁺ B-cells in their salivary gland biopsy.

In pSS patients with autoantibodies (anti-SSA, anti-SSB, RF, ANA) tend to have higher numbers of FcRL4⁺ B-cells in their parotid gland biopsy (A-D) or labial gland biopsies (E-H). Horizontal bars in the graphs represents the median.



CHAPTER 5

Presence of intraepithelial B-lymphocytes is associated with the formation of lymphoepithelial lesions in salivary glands of primary Sjögren's syndrome patients

Martha S van Ginkel¹
Erlin A Haacke^{1,2}
Hendrika Bootsma¹
Suzanne Arends¹
Jolien F van Nimwegen¹

Gweny M Verstappen¹
Fred KL Spijkervet³
Arjan Vissink³
Bert van der Vegt²
Frans GM Kroese¹

Departments of ¹Rheumatology and Clinical Immunology, ²Pathology and Medical Biology, and ³Oral and Maxillofacial Surgery, University of Groningen, University Medical Center Groningen, the Netherlands

Modified version of: Clin Exp Rheumatol. 2019;37:42-48

ABSTRACT

Objective: Lymphoepithelial lesions (LELs) in salivary glands are associated with primary Sjögren's syndrome (pSS). LELs are composed of hyperplastic epithelium infiltrated with lymphocytes. The objective of this study was obtaining insight in the relative roles of intraepithelial B- and T-lymphocytes in the formation of LELs in salivary glands of pSS patients.

Methods: Parotid and labial salivary gland biopsies of pSS patients (n=15), non-SS sicca patients (n=5) and non-sicca controls (n=5) were analysed. Serial sections were stained with H&E and for cytokeratin, CD20 and CD3. Striated ducts with lymphocytes, but without hyperplasia, and striated ducts with LELs were identified in H&E and cytokeratin stained sections. LELs were classified in successive stages of severity based on the amount of hyperplasia (stage1-3). Numbers of B- and T-lymphocytes within striated ducts and LELs were counted in CD20 and CD3 stained sections.

Results: Lymphocyte-containing striated ducts of both salivary glands of all pSS and control patients harboured T-lymphocytes, scattered throughout the ductal epithelium. In contrast, B-lymphocytes were exclusively found in a small fraction (21%) of striated ducts without hyperplasia and in nearly all striated ducts with LELs of pSS patients, but not in controls. In striated ducts with LELs B-lymphocytes were mostly located in the areas of proliferating epithelium. Numbers of B-lymphocytes and B/T-ratios increased significantly with higher severity of LELs. This was even more pronounced in the parotid than in the labial gland.

Conclusion: We conclude there is an association between presence of intraepithelial B-lymphocytes and the formation of LELs in salivary glands of pSS patients.

INTRODUCTION

Primary Sjögren's syndrome (pSS) is a systemic autoimmune disease characterized by sicca complaints and lymphocytic infiltration of the lacrimal and salivary glands.¹ These infiltrates are mostly situated around the striated ducts, forming periductal foci. The major role of the salivary gland in the pathogenesis of the disease is illustrated by the prominent role of histopathology of the salivary gland in the 2016 ACR-EULAR classification criteria.² These criteria require either a positive salivary gland biopsy or presence of anti-Ro/SSA antibodies to classify a patient as pSS. A biopsy is suggestive for pSS when the focus score (FS) ≥ 1 . FS is defined as the number of foci (clusters of ≥ 50 lymphocytes) in 4 mm² glandular tissue.³ However, the FS has some important limitations and additional histopathological features may be helpful for diagnosis and classification of pSS.⁴ One of the features associated with pSS is the formation of lymphoepithelial lesions (LELs) within the foci.⁵ Ihrler et al. postulated that LELs develop in a stepwise manner: lymphocytic infiltration within the ductal epithelium with subsequent hyperplasia of ductal basal cells, causing differentiation into a multi-layered stratified epithelium, or even complete obstruction of the striated ducts.⁵ Interestingly, a serious complication of the disease is the development of non-Hodgkin lymphoma in 5-10% of the patients, mostly of the mucosa associated lymphoid tissue (MALT) type.⁶ These lymphomas most commonly develop in the parotid gland and are consistently associated with the presence of LELs in the glandular tissue. Both B- and T-lymphocytes may be present in LELs.^{4,7} However, the exact roles of B- and T- lymphocytes in LEL formation are unknown.

The aim of the work described here was to quantify the number of B- and T-lymphocytes within striated ducts without hyperplasia and striated ducts with LELs in both labial and parotid gland biopsies of pSS patients and controls, in order to get insight in the role of lymphocyte subtypes in LEL formation.

MATERIALS AND METHODS

Patients

Both parotid and labial salivary gland biopsies were collected of 15 pSS patients and 5 non-SS sicca patients, without MALT lymphoma, non-specific chronic sialadenitis (NSCS), sclerosing chronic sialadenitis (SCS) or other autoimmune diseases. Patient characteristics are provided in Table 1. PSS patients fulfilled the 2016 ACR-EULAR criteria. Non-SS sicca patients were defined as patients having sicca complaints, without serum anti-Ro/SSA antibodies and without foci (FS=0) in neither parotid nor labial salivary glands, and who did not use medication that is known to induce sicca symptoms. Furthermore, biopsy material of non-sicca control patients was obtained

from diagnostic redundant material. For parotid gland tissue of non-sicca controls (n=5), resection margins from parotidectomies of patients with a Warthin tumor (n=2) or pleomorphic adenoma (n=3) were used. For non-sicca labial gland tissue (n=5), samples from benign retention cyst (mucocele) resections were taken. The study of pSS patients and non-SS sicca patients was approved by the Medical Research Ethics Committee of the University Medical Centre Groningen (METc2013.066). All pSS and non-SS sicca patients provided informed consent. For the non-sicca controls, informed consent was not required by Dutch Law for Medical Research and by institutional guidelines. No objection against use of redundant tissue was recorded from these non-sicca controls in the institutional record of objection. Patient material was handled according to the 'Code of conduct for health research' of the Dutch Federation of Biomedical Scientific Societies.⁸

Table 1: Patient characteristics.

	pSS patients (n=15)	Non-SS sicca patients (n=5)	Non-sicca controls, parotid gland (n=5)	Non-sicca controls, labial gland (n=5)
Age*	49.1 (±14.2)	46.7 (±13.5)	59.2 (±12.2)	24.8 (±17.0)
Female	14 (93)	4 (80)	2 (40)	2 (40)
Anti-SSA-positivity	14 (93)	0 (0)	N.D.	N.D.
FS parotid gland	1.3 (0.6 – 1.9)	0 (0-0)	N.D.	N.D.
FS labial gland	1.6 (0.8 – 2.3)	0 (0-0)	N.D.	N.D.
UWS ≤0.1ml/min	10 (67)	4 (80)	N.D.	N.D.
OSS ≥5	8 (62)	0 (0)	N.D.	N.D.
Schirmer's test ≤5 mm	13 (87)	2 (40)	N.D.	N.D.

Data are given as mean (±SD), number (%) or median (IQR). FS: Focus Score; UWS: Unstimulated Whole Saliva; OSS: Ocular Staining Score; N.D.: not determined. * Age at the time of diagnosis.

Histochemical and immunohistochemical staining

Formalin fixed (4%), paraffin embedded tissue samples were serially sectioned at 3 µm thickness and deparaffinized. Tissue samples were automatically stained with hematoxylin and eosin (H&E) and manually stained for CD20 (clone L-26, Ventana Roche), CD3 (clone 2GV6, Ventana Roche) and high molecular weight cytokeratin (hmwCK, clone 34BE12, Ventana Roche). For the immunohistochemical staining antigen retrieval was performed (15 minutes, 98 °C in EDTA buffer pH 8.0) and endogenous peroxidase was blocked. Primary antibodies were used at a pre-fixed dilutions in 1% BSA-PBS (Ventana Roche) for 75 minutes. After incubation with a poly-HRP-labelled secondary antibody (Thermo Scientific), the primary antibodies were visualised by using DAB (3,3'-diaminobenzidine). The typical spatial distribution of CD3,

CD20 and hmwCK staining within tonsillar tissue was used as both a positive and negative control, as the tonsillar epithelium expresses hmwCK and does not express CD3 and CD20 and the tonsillar lymphoid tissue expresses CD3 and CD20, but does not express hmwCK.

Histological analysis

The FS and severity of LELs was scored on H&E stained sections. HmwCK staining was used to identify the ductal epithelium, and to detect “occluded LELs” (Figure 1), which are otherwise very difficult to detect unequivocally. Only striated ducts with lymphocytes within the epithelium were analysed. Ducts were divided into two groups: striated ducts with lymphocytes, but without epithelial hyperplasia and striated ducts with lymphocytes with epithelial hyperplasia (i.e. LELs). LELs were subdivided into three stages, according to the amount of hyperplasia (Figure 1). In all biopsies, the 10 most severe LELs were selected for further analysis. In case less than 10 striated ducts with LELs were present, striated ducts without hyperplasia, but with intraepithelial lymphocytes, identified by H&E staining, were selected to complete the total of 10 ducts. If the total number of striated ducts with lymphocytes in the salivary gland tissue was still less than 10, the maximum number of striated ducts with intraepithelial lymphocytes and LELs was analysed. Numbers of B- and T-lymphocytes within each of the striated ducts and LELs were manually scored by using Image J cell counter in serial CD20 and CD3 stained sections.

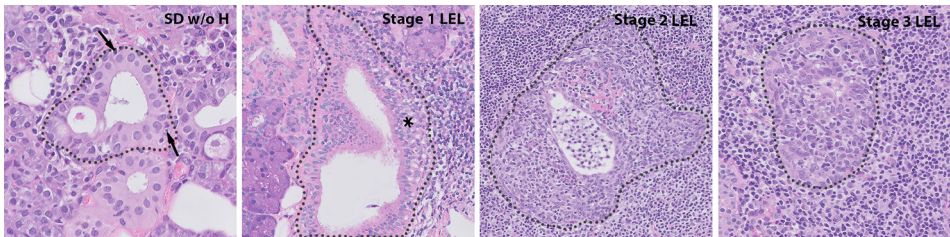


Figure 1: Scoring of severity of LELs.

Striated ducts with lymphocytes were divided into two groups: striated ducts without epithelial hyperplasia (SD w/o H) and striated ducts with epithelial hyperplasia (stage 1-3 LELs). Stage 1 LEL: Lymphocytic ductal infiltration and hyperplasia affecting less than 50 percent of the epithelium. Stage 2 LEL: Lymphocytic ductal infiltration and hyperplasia affecting between 50 and 100 percent of the epithelium. Stage 3 LEL: Lymphocytic ductal infiltration and fully circumferentially hyperplastic epithelium without lumen. Arrows point at lymphocytes and the star marks the area of proliferation. Dotted lines mark the ductal border, identified on hmwCK staining.

Statistical analysis

Statistical analyses were performed in IBM SPSS Statistics 23. Generalized estimating equations (GEE) were used to analyse the numbers of B-, T-lymphocytes and B/T-ratio's

within LELs of pSS patients over the different stages of severity, within striated ducts without hyperplasia of pSS versus control patients, and within LELs of parotid versus labial glands of pSS patients. Spearman's correlation coefficient was used to analyse correlations between parotid and labial glands of individual pSS patients and to analyse associations between severity of LELs, FS and clinical features of pSS patients.

RESULTS

Histological analysis

Of the total number of 50 biopsies (25 parotid and 25 labial glands), six biopsies (5 parotid and 1 labial gland) were excluded from the analysis due to insufficient biopsy material ($< 4 \text{ mm}^2$), or because slides were not stored in a consecutive order. For pSS patients, 11 parotid and 14 labial gland biopsies were analysed, of which 97 and 137 striated ducts were selected for the parotid and labial glands, respectively (median value 10 for both types of glands). For the control group (non-SS sicca patients and non-sicca controls), 9 parotid and 10 labial gland biopsies were analysed, of which 41 and 65 striated ducts were selected (median value 4 and 7, respectively).

Severity of LELs

In pSS patients, striated ducts with LELs were found in 81% of parotid and 86% of labial glands, and they were consistently located in association with periductal infiltrates. This is in contrast to striated ducts with intraepithelial lymphocytes, but without hyperplasia, which were not always associated with periductal infiltrates. Striated ducts with LELs were completely absent in non-SS sicca patients and non-sicca controls; in these patients only striated ducts without epithelial hyperplasia were present. Numbers of analysed striated ducts without hyperplasia and striated ducts with LELs, including frequencies of stages of LELs, are shown in Table 2. The number of stage 3 LELs is relatively small in both types of glands, due to the small study population. Stage 2 LELs dominated in parotid glands of pSS patients, whereas stage 1 LELs were most frequent in labial glands. Mean severity of LELs (stage 1-3) of pSS patients was, however, not significantly different between parotid and labials glands (1.38 ± 0.78 and 1.08 ± 0.56 , respectively). In the parotid gland of pSS patients, a higher FS was associated with presence of more severe LELs ($r_s 0.540$, $p=0.038$).

B- and T-lymphocytes within striated ducts and LELs

T-lymphocytes were detected in all striated ducts without hyperplasia and striated ducts with LELs (stage 1-3) of pSS patients as well as in all striated ducts without hyperplasia of the non-SS sicca patients and non-sicca controls. In contrast, B-lymphocytes were

exclusively found in striated ducts without hyperplasia and striated ducts with LELs of pSS patients, and were completely absent in the striated ducts of non-SS sicca and non-sicca controls. B-lymphocytes were nearly always found in striated ducts with LELs of pSS patients, namely in 100% of parotid and 87% of labial gland stage 1-3 LELs. The remaining 13% of LELs without B-lymphocytes in labial glands, were all scored as stage 1 LELs. Interestingly, B-lymphocytes in striated ducts with LELs were mostly concentrated in the areas where the epithelium was proliferating, whereas T-lymphocytes were scattered through the whole ductal epithelium (Figure 2). Although B-lymphocytes were consistently found in striated ducts with LELs, they were also present in 21% of striated ducts without hyperplasia of pSS patients; these striated ducts were also associated with a periductal focus.

Table 2: Numbers and frequencies of analysed striated ducts without hyperplasia and LELs.

	Parotid gland		Labial gland	
	pSS patients N = 99 ducts	Controls N = 41 ducts	pSS patients N = 137 ducts	Controls N = 65 ducts
SD w/o H	63	41	92	65
LELs	36	0	45	0
Stage 1 LELs	13 (36)	-	33 (73)	-
Stage 2 LELs	21 (58)	-	9 (20)	-
Stage 3 LELs	2 (6)	-	3 (7)	-

Data are given as number or number (%). SD w/o H: striated duct without hyperplasia; LELs: lymphoepithelial lesions. Controls: non-SS sicca patients and non-sicca controls.

In the parotid and labial gland of pSS patients, the absolute numbers of B-lymphocytes in the striated ducts with LELs increased significantly with higher severity of LELs (overall increase $p < 0.001$). For T-lymphocytes such an association was only seen in the parotid gland ($p = 0.042$). Absolute numbers of B-lymphocytes showed a higher increase compared to T-lymphocytes, resulting in a significant increase of the B/T-ratio with higher severity of LELs in both glands (overall increase $p < 0.001$) (figure 3). In both parotid and labial salivary glands of pSS patients, there was a predominance of T-lymphocytes in striated ducts without hyperplasia as well as in stage 1 LELs (B/T-ratio < 1). In the more severe stages of LELs (stage 2-3), B-lymphocytes outnumbered the T-lymphocytes (B/T-ratio > 1) (figure 3). The fact that B-lymphocytes were present in striated ducts without hyperplasia of pSS patients, but not in control patients, was also reflected by a significantly higher number of B-lymphocytes and higher B/T-ratio in striated ducts without hyperplasia of pSS patients than in non-SS sicca and non-sicca controls in both salivary glands ($p < 0.001$) (Figure 3). Numbers of B-lymphocytes, T-lymphocytes and B/T-ratios within LELs (stage 1-3) were significantly higher in the parotid gland than in the labial gland ($p = 0.001$, $p = 0.021$ and

p=0.007 respectively). To compare parotid and labial glands of individual pSS patients, the highest number of B-lymphocytes, T-lymphocytes and the highest B/T-ratio within LELs of each gland was taken. A correlation was found between the highest number of T-lymphocytes (rs 0.659, p=0.038). No concordance was found between the highest number of B-lymphocytes, highest B/T-ratio and most severe stage of LEL within parotid and labial gland biopsies of individual pSS patients.

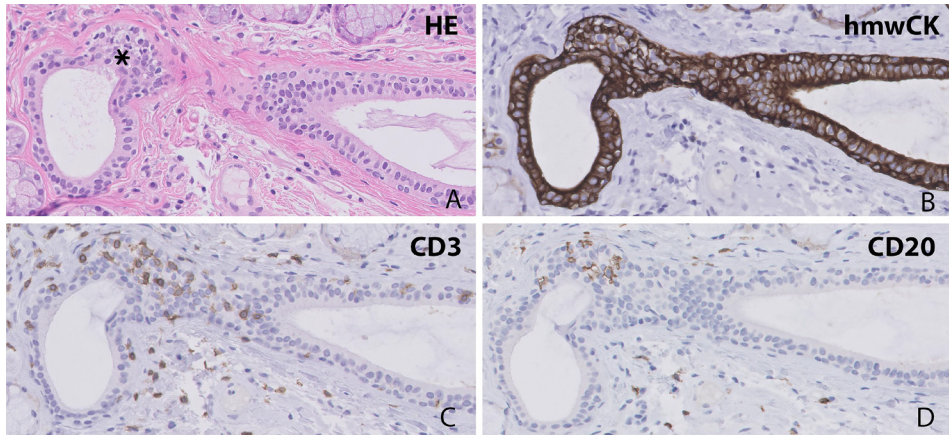


Figure 2: B-lymphocytes are located in the hyperplastic area of the striated duct.

Serial sections were stained with H&E, and for hmwCK, CD3 and CD20. **A)** Stage 1 LEL with infiltrating lymphocytes and ductal hyperplasia (star) after H&E staining. **B)** Positive hmwCK staining marks the ductal epithelium. **C)** CD3⁺ T-lymphocytes are scattered throughout the whole ductal epithelium, whereas **D)** CD20⁺ B-lymphocytes are located in the hyperplastic area.

Clinical correlations

In order to further explore the role of LELs in disease development, severity of LELs was correlated to clinical findings of pSS patients. Positive correlations were found between the highest B/T-ratio in the parotid gland and IgG-levels and rheumatoid factor (RF) levels in plasma of pSS patients (rs 0.790, p=0.004 and rs 0.696, p=0.017, respectively). A positive correlation was also found between the most severe stage of LEL within labial glands and the flow rate of unstimulated whole saliva (UWS) (rs 0.563, p=0.029). No correlations with ESSDAI scores or other clinical parameters were found in this small study population.

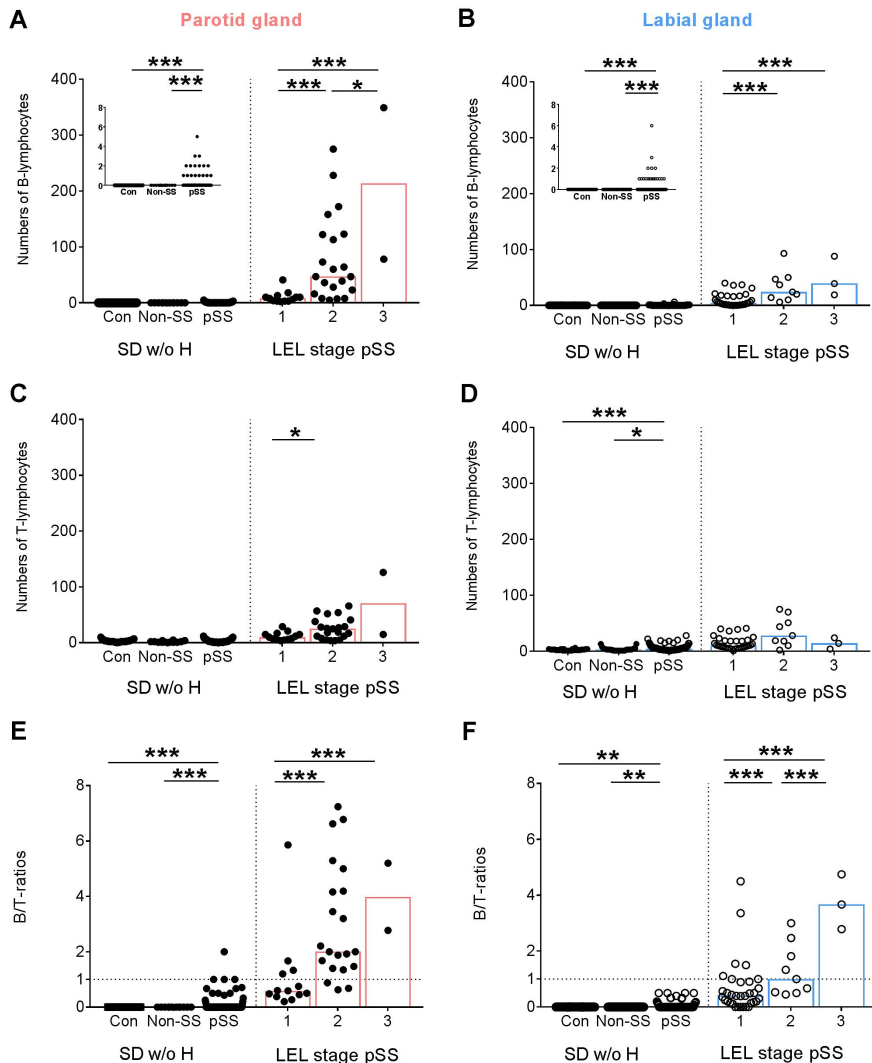


Figure 3: B-lymphocytes are exclusively present in striated ducts of pSS patients, and their absolute numbers increase with higher severity of LELs.

Numbers of B- and T-lymphocytes, as well as B/T-ratios were assessed in striated ducts without hyperplasia (SD w/o H) and striated ducts with hyperplasia (LELs) of pSS and control patients. LELs were only present in pSS patients. Striated ducts without hyperplasia of non-sicca controls (con), non-SS sicca patients (non-SS) and pSS patients (pSS) are listed on the left side of each graph. Striated ducts with LELs (stage 1-3) of pSS patients are listed on the right side of the graphs. Bars represent medians. GEE analyses were used to analyse differences in numbers of B-lymphocytes (A,B), T-lymphocytes (C,D) and B/T ratios (E,F) between SD w/o H of pSS and control patients (left side of graphs) and between the different LEL stages of pSS patients (right side of graphs) in both the parotid (A,C,E) and the labial salivary gland (B,D,F). Only significant differences are shown. *** p<0.001, ** p<0.01, * p<0.05.

DISCUSSION

The main aim of this study was to gain insight in the formation of LELs by quantification of the numbers of B- and T-lymphocytes within striated ducts without hyperplasia and within different stages of LELs in the parotid and labial salivary gland of pSS patients, compared to salivary glands of non-SS sicca patients and non-sicca controls. We found that all analysed striated ducts with lymphocytes consistently harbored T-lymphocytes, scattered throughout the whole epithelium. In contrast, B-lymphocytes were exclusively seen in striated ducts without hyperplasia and in striated ducts with LELs of pSS patients, and were mostly located in areas of proliferating epithelium. B-lymphocytes were completely absent in the striated ducts of non-SS sicca and non-sicca controls. Absolute numbers of B-lymphocytes increased with higher severity of LELs in both glands, leading to a significant increase in B/T-ratio over the stages of LELs. This was even more pronounced in the parotid gland, than in the labial gland.

Our observation that in non-SS sicca patients (in this study defined as patients without anti-SSA antibodies and FS=0) and in non-sicca controls (all without periductal foci), the ductal epithelium only contains T-lymphocytes, indicates that these cells are a normal component of the salivary gland epithelium. On the other hand, B-lymphocytes were only present in a small proportion of striated ducts without hyperplasia and in all (parotid gland) or nearly all (labial glands) of the striated ducts with LELs of pSS patients. These B-lymphocytes are predominantly located at the sites where the epithelium is hyperplastic. These findings strongly argue that intraepithelial B-lymphocytes are involved in proliferation of the epithelial cells and the generation of LELs. Strong support for this notion also comes from studies of pSS patients treated with B-lymphocyte depletion therapy (rituximab). These studies showed that this therapy not only results in depletion of intraepithelial B-lymphocytes of the ducts but concomitantly also in downstaging of LELs.⁹ In this study, the possible contribution of hyperactive B-lymphocytes in salivary gland dysfunction was also reflected by positive correlations between B/T-ratios and severity of LELs with serological parameters and salivary secretion. However, our study population was quite small and correlations with clinical parameters should be further explored in a larger cohort of pSS patients.

Based upon the results of the current study, it seems plausible that influx of B-lymphocytes precedes the hyperplastic reaction of the epithelium, since 21% of striated ducts with lymphocytes, but without hyperplasia of pSS patients (but not of controls), already contain B-lymphocytes. A major chemokine produced by the ductal epithelium of pSS patients that can attract CXCR3-expressing B- and T-lymphocytes, is the inflammatory chemokine CXCL10, which is induced by IFN.¹⁰ Strongly elevated levels of this chemokine are detected in saliva, tears and serum of pSS patients.^{11,12} We have previously observed that the vast majority of B-lymphocytes within the LELs express FcRL4.¹³ A high proportion

of these intra-epithelial B-lymphocytes is proliferative in both the parotid (mean $20.5 \pm 7.7\%$) and labial gland (mean $15.4 \pm 8.2\%$), as revealed by Ki67 staining.¹³ Thus after the initial influx into the epithelium, these cells may proliferate locally. The reason for the proliferation of the B-lymphocytes (and possibly to some extent also intraepithelial T-lymphocytes) is not known. The epithelial cells in the inflamed salivary glands of the pSS patients produce a wide variety of cytokines, including BAFF and APRIL,¹⁴ which may support the intraepithelial proliferation of the B-lymphocytes. Verstappen et al.¹⁵ revealed expression of IL-21 within the parotid ductal epithelium. This cytokine, important for B-lymphocyte activation and differentiation, is a signature cytokine for follicular helper T-lymphocytes (T_{FH}). This observation opens the possibility that T_{FH} play a role in the activation of intraepithelial B-lymphocytes.

Interestingly, also the MALT lymphomas in the parotid gland of pSS patients express FcRL4 and the neoplastic B-lymphocytes are characteristically associated with LELs. We therefore hypothesized that the neoplastic B-lymphocytes arise from this small subset of FcRL4-expressing B-lymphocytes.¹³ In line with the observation that MALT lymphomas preferentially develop in the parotid glands of pSS patients we observed in this study that B/T ratios are higher in striated ducts with LELs of parotid glands compared to labial glands.

We speculate that after homing into the epithelium, the (FcRL4⁺) B-lymphocytes activate the ductal epithelial (stem) cells, after which they start to proliferate. How these B-lymphocytes exert their possible effects on the epithelium remains to be shown, but cytokines secreted by activated B-lymphocytes are possible candidates. It is already known that intestinal intraepithelial lymphocytes can secrete pro-inflammatory cytokines like IL-2, IL-4 and IL-6, which can cause epithelial cell proliferation.¹⁶ Vice versa, epithelial stem cells derived from the parotid glands proliferate under the influence of pro-inflammatory cytokines in vitro.¹⁷ In RA, FcRL4⁺ B-lymphocytes have been found in synovial fluid, where they produce cytokines such as TNF α and RANKL.¹⁸ In salivary glands of pSS patients, FcRL4⁺ B-lymphocytes may possibly also secrete cytokines within the ductal epithelium and thereby stimulate proliferation of the epithelial cells [Verstappen et al. submitted for publication]. More research on the functional capabilities of the (FcRL4⁺) B-lymphocytes in pSS patients is needed, especially on the cytokines they produce.

In conclusion, LELs are a characteristic histopathological finding in salivary glands of pSS patients and there is a close interaction between lymphocytes and the ductal epithelial cells. Our results show an association between intra-epithelial B-lymphocytes and hyperplasia of the basal ductal epithelial cells and thereby the formation of LELs in salivary glands of pSS patients.

ACKNOWLEDGEMENTS

Funding: This study was financially supported by grants from the NIH (USA; RFA-DE-06-004), the Dutch Arthritis Foundation and the Jan-Kornelis de Cock Foundation (Groningen, the Netherlands). There was no involvement of these funding sources in study design, data collection, analysis and interpretation and writing of this report.

REFERENCES

1. Brito-Zeron P, Baldini C, Bootsma H, et al. Sjögren syndrome. *Nat Rev Dis Primers* 2016;2:16047.
2. Shiboski CH, Shiboski SC, Seror R, et al. 2016 American College of Rheumatology/European League Against Rheumatism classification criteria for primary Sjögren's syndrome: A consensus and data-driven methodology involving three international patient cohorts. *Ann Rheum Dis* 2017;76:9-16.
3. Greenspan JS, Daniels TE, Talal N, et al. The histopathology of Sjögren's syndrome in labial salivary gland biopsies. *Oral Surg Oral Med Oral Pathol* 1974;37:217-29.
4. Kroese FGM, Haacke EA, Bombardieri M. The role of salivary gland histopathology in primary Sjögren's syndrome: promises and pitfalls. *Clin Exp Rheumatol* 2018;36:222-33.
5. Ihrler S, Zietz C, Sendelhofert A, et al. Lymphoepithelial duct lesions in Sjögren-type sialadenitis. *Virchows Arch* 1999;434:315-23.
6. Routsias JG, Goules JD, Charalampakis G, et al. Malignant lymphoma in primary Sjögren's syndrome: an update on the pathogenesis and treatment. *Semin Arthritis Rheum* 2013;43:178-86.
7. Masaki Y, Sugai S. Lymphoproliferative disorders in Sjögren's syndrome. *Autoimmun Rev* 2004;3:175-82.
8. FMWV Code of Conduct for Health Research, [internet] 2011. Available from https://www.federa.org/sites/default/files/bijlagen/coreon/code_of_conduct_for_medical_research_1.pdf
9. Delli K, Haacke EA, Kroese FG, et al. Towards personalised treatment in primary Sjögren's syndrome: baseline parotid histopathology predicts responsiveness to rituximab treatment. *Ann Rheum Dis* 2016;75:1933-38.
10. Ogawa N, Ping L, Zhenjun L, et al. Involvement of the interferon-gamma-induced T cell-attracting chemokines, interferon-gamma-inducible 10-kd protein (CXCL10) and monokine induced by interferon-gamma (CXCL9), in the salivary gland lesions of patients with Sjögren's syndrome. *Arthritis Rheum* 2002;46:2730-41.
11. Hernandez-Molina G, Michel-Peregrina M, Hernandez-Ramirez DF, et al. Chemokine saliva levels in patients with primary Sjögren's syndrome, associated Sjögren's syndrome, pre-clinical Sjögren's syndrome and systemic autoimmune diseases. *Rheumatology (Oxford)* 2011;50:1288-92.
12. Lee YJ, Scofield RH, Hyon JY, et al. Salivary chemokine levels in patients with primary Sjögren's syndrome. *Rheumatology (Oxford)* 2010;49:1747-52.
13. Haacke EA, Bootsma H, Spijkervet FKL, et al. FcRL4+ B-cells in salivary glands of primary Sjögren's syndrome patients. *J Autoimmun* 2017;81:90-98.
14. Jonsson MV, Szodoray P, Jellestad S, et al. Association between circulating levels of the novel TNF family members APRIL and BAFF and lymphoid organization in primary Sjögren's syndrome. *J Clin Immunol* 2005;25:189-901.
15. Verstappen GM, Kroese FG, Meiners PM, et al. B Cell Depletion Therapy Normalizes Circulating Follicular Th Cells in Primary Sjögren Syndrome. *J Rheumatol* 2017;44:49-58.
16. Koch S, Nusrat A. The life and death of epithelia during inflammation: lessons learned from the gut. *Annu Rev Pathol* 2012;7:35-60.
17. Pringle S, Wang X, Verstappen GMPJ, et al. Salivary gland stem cells age prematurely in primary Sjögren's syndrome. *Arthritis Rheumatol* 2019;71:133-42.
18. Yeo L, Lom H, Juarez M, et al. Expression of FcRL4 defines a pro-inflammatory, RANKL-producing B cell subset in rheumatoid arthritis. *Ann Rheum Dis* 2015;74:928-35.





CHAPTER 6a

Germinal centres in diagnostic
labial gland biopsies of patients
with primary Sjögren's syndrome
are not predictive for parotid MALT
lymphoma development

Erlin A Haacke^{1,2}
Bert van der Vegt²
Arjan Vissink³

Fred KL Spijkervet³
Hendrika Bootsma¹
Frans GM Kroese¹

Department of ¹Rheumatology & Clinical Immunology, ²Pathology and Medical Biology,
³Oral and Maxillofacial Surgery, University of Groningen, University Medical Center
Groningen, the Netherlands

Modified version of: Ann Rheum Dis. 2017;76:1781-84

ABSTRACT

Objective: Patients with primary Sjögren's syndrome (pSS) have an increased risk of developing non-Hodgkin's lymphoma (NHL), particularly parotid gland mucosa-associated lymphoid tissue (MALT) lymphomas. Presence of germinal centres (GCs) in labial gland biopsies has been suggested as predictive factor for NHL. We assessed whether presence of GCs is increased in labial gland biopsies from patients with pSS who developed parotid MALT lymphoma, the dominant NHL-subtype in pSS, compared with patients with pSS who did not develop lymphoma.

Methods: Eleven labial gland biopsies from patients with pSS that were taken prior to parotid MALT lymphoma development were compared to biopsies of 22 matched pSS controls (1:2) who did not develop lymphoma. Biopsies were evaluated for GCs (H&E and Bcl6).

Results: Labial gland biopsies of pSS MALT lymphoma patients, revealed GCs in 2/11 (18%) H&E sections and 3/11 (27%) Bcl6 stained sections. In controls, GCs were present in 4/22 (18%) of H&E sections and 5/22 (23%) of Bcl6 stained sections.

Conclusion: Presence of GCs in labial gland biopsies does not differ between patients with pSS that develop parotid MALT lymphoma and patients with pSS who do not develop lymphoma. The presence of GCs in labial gland biopsies is therefore not a predictive factor for pSS-associated parotid MALT lymphomas.

INTRODUCTION

Primary Sjögren's syndrome (pSS) is a systemic autoimmune disease, in which salivary and lacrimal glands are affected by a chronic inflammatory process, which leads to dryness of mouth and eyes.¹ Histopathologically, this inflammatory process is characterised by a periductal lymphoid infiltrate in the glandular parenchyma.² In roughly one quarter of the patients with pSS, germinal centres (GCs) can be found within these lymphoid infiltrates reflecting the B-cell hyperactivity that characterises the disease.^{3,4} Although the clinical significance of these GCs remains to be elucidated, the presence of GCs in the glandular tissue of patients with pSS is generally associated with more severe clinical disease as reflected by a higher focus score (FS), increased presence of anti-SSA/Ro (52 kD + 60 kD) and anti-SSB/La autoantibodies and elevated levels of proinflammatory cytokines in the blood.³

A serious complication of pSS is the 5%-10% lifetime risk of developing non-Hodgkin's B-cell lymphomas (NHL).⁵ The most common subtype NHL in pSS is the mucosa-associated lymphoid tissue (MALT) lymphoma.⁵⁻⁷ These MALT lymphomas preferentially arise in the parotid glands and account for >60% of the lymphomas arising in patients with pSS.⁶⁻⁸ Which patients with pSS will develop NHL is largely unknown, but several predictors have been identified including disease activity, persistent glandular enlargement, lymphadenopathy, palpable purpura, anti-Ro/anti-La antibodies, rheumatoid factor (RF), lymphopenia, declined C3 or C4 levels, cryoglobulinaemia and a FS ≥ 3 in the labial gland biopsy.⁹⁻¹¹ Presence of GCs in diagnostic labial gland biopsies has also been proposed as a predictive factor for the development of NHL. However, in the study underlying this assumption, all subtypes of NHL were taken into account, including NHL subtypes not typically associated with pSS, such as follicular lymphoma and T-cell lymphoma.¹² For this reason, we explored the predictive role of GCs in labial gland biopsies from patients with pSS for parotid gland MALT lymphomas.

6a

MATERIALS AND METHODS

Patients

From 56 patients with pSS diagnosed with parotid MALT lymphoma we were able to acquire labial gland biopsies of 11 patients taken at diagnosis of pSS, before (median 4.0, IQR 1.5-6.1 years) lymphoma diagnosis (Table 1). Labial gland biopsies from 22 pSS patients with a NHL free follow-up (median 12.0, IQR 6.3-16.8 years) served as controls (Supplementary Table 1). Matching of control pSS patients (1:2) was based on age at diagnosis of pSS and the presence of SSA autoantibodies. Patients were frequency-matched within three age groups: patients diagnosed with pSS at an age of ≤ 40 , between 40 and 60 and ≥ 60 years. All patients were clinically diagnosed as pSS and retrospectively

fulfilled the ACR-EULAR (American College of Rheumatology - European League Against Rheumatism) classification criteria¹³ at time of diagnosis. Of the 33 included patients, 32 also fulfilled the AECG-criteria at time of diagnosis. Of one patients this is uncertain due to missing sialometry and ocular examination.

Histopathological assessment of diagnostic salivary gland biopsies

Diagnostic labial salivary gland biopsies were formalin fixed, paraffin embedded and sectioned at 3 µm thickness. Serial sections were stained with H&E, and immunohistochemically for B-cell lymphoma six protein (Bcl6, clone 2B11+PD7/26, Ventana, Illkirch, France) and CD45 (clone 2B11+PD7/26, Ventana, Illkirch, France). Staining was performed on a Ventana Benchmark platform as previously described.¹⁴ In H&E stained sections, FS, lymphoepithelial lesions (LELs) and GCs were assessed. FS was based on the number of clusters of ≥50 lymphocytes (foci)/4 mm² parenchyma. In case of multiple large confluent foci an arbitrary FS of 12 was used.¹⁵ LELs were defined as a striated duct with lymphocytes within its basement membrane. GCs were defined as a clearly visible lighter area in a lymphocytic infiltrate containing cells usually present in classical GCs: follicular dendritic cells, centrocytes, centroblasts and macrophages. Since detection of GCs is difficult in H&E stained sections, and small GCs may be overlooked,¹⁶ we also evaluated GCs in Bcl6 stained sections. Bcl6 is a transcription factor highly expressed by all GC B-cells. A cluster of ≥5 adjacent Bcl6⁺ cells within a focus was classified as a GC.

Besides focus score, we also measured the extent of glandular inflammation as proposed.² This was assessed using CD45 staining. CD45 is expressed by all lymphoid and non-lymphoid cells of hematopoietic origin, allowing easy quantification of the relative area of the infiltrate. CD45 expression was measured using ImageScope v12.0 (Aperio Technologies). Slides were blinded and independently scored by a trained resident (EH) and a dedicated head & neck pathologist (BvdV).

Statistical analysis

Mann-Whitney U test and Fisher's Exact test were used accordingly to test differences between groups (IBM-SPSS Statistics V.23).

RESULTS

Analysis of H&E stained sections from diagnostic labial gland biopsies, taken prior to parotid MALT lymphoma development, revealed presence of GCs in 2/11 (18%) patients (Table 2). Staining for Bcl6, revealed an extra (small) GC in a biopsy of one additional patient (Figure 1, Table 2). Thus, in pSS patients who developed parotid MALT lymphoma, GCs were present in 3/11 (27%) prelymphoma labial gland biopsies. In the patients with

pSS that did not develop parotid MALT lymphomas (nor any other type of NHL) GCs were detected in 4/22 (18%) diagnostic labial gland biopsies in H&E stained sections and in 5/22 (23%) of Bcl6 stained sections (Table 2). This proportion was comparable with that seen in patients with pSS who did develop parotid MALT lymphoma.

Since $FS \geq 3$ has been suggested as predictive factor for NHL development,⁹ we compared FS and relative area of CD45⁺ infiltrate in prelymphoma labial gland biopsies and biopsies from control pSS patients. FS did not differ between both groups (Mann-Whitney U, $p=0.204$). The percentage of biopsies with $FS \geq 3$ was even higher in the control group (36% versus 27%). The relative area of CD45⁺ lymphocytic infiltrate, however, tended to be higher in the prelymphoma labial gland biopsies than in the controls (Table 2).

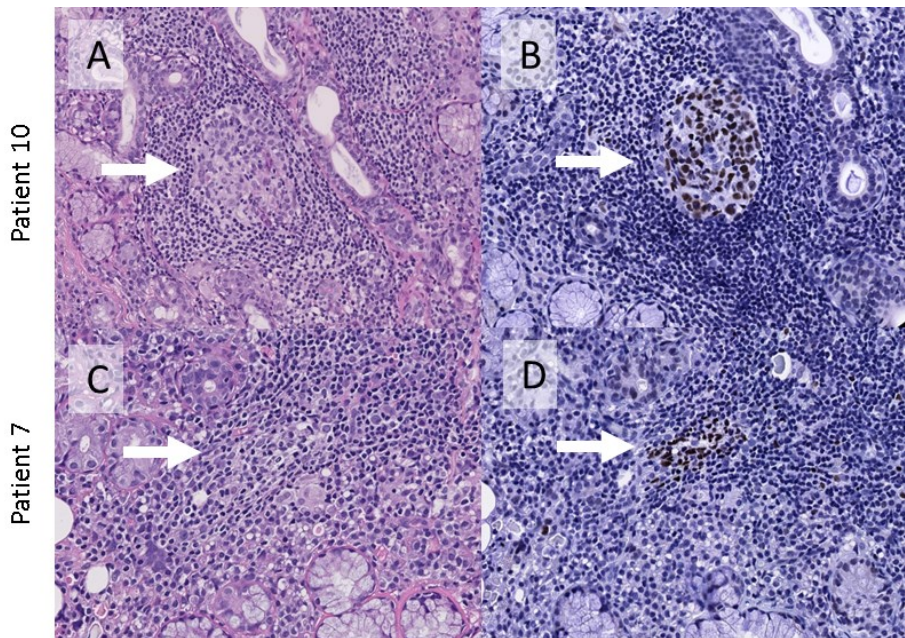


Figure 1: GCs in diagnostic labial salivary gland biopsies of patients with pSS who developed a parotid MALT lymphoma later on. **A)** Clearly visible GC in a periductal focus of the labial gland, H&E stain. **B)** Bcl6 staining of serial section, showing the same GC. **C)** Suspicious GC in a periductal focus of the labial gland, H&E stain. **D)** Bcl6 staining of a serial section shows a small GC. Arrows point to GCs. GCs, germinal centres; pSS, primary Sjögren's syndrome.

Table 1: Patients characteristics and histopathology results of pSS patients (n=11) developing a parotid MALT lymphoma.

Patient	Gender	Age pSS (year)	Δ lymph pSS (year)	Ann Arbor	pSS biopsy	FS	CD45 (%)	GC H&E	GC Bcl6	LEL H&E	Anti-SSA	Anti-SSB
1	F	37	3.5	2	Labial	4.0	27.6	-	-	+	+	+
2	F	60	13.7	1	Labial	0.8	5.3	-	-	-	+	-
3	F	32	4.0	1	Labial	1.1	12.2	-	-	-	+	+
4	F	28	0.2*	1	Labial	0	7.4	-	-	-	+	+
5	F	63	6.1	2	Labial	4.7	38.8	+	+	+	+	-
6	F	47	3.2	2	Labial	1.8	23.4	-	-	+	+	+
7	F	45	0.3*	1	Labial	2.0	34.1	-	+	+	+	+
8	F	67	4.6	1	Labial	0	5.3	-	-	-	+	+
9	F	31	4.0	2	Labial	1.7	20.3	-	-	+	+	+
10	F	51	13.3	3	Labial	2.7	18.2	+	+	+	+	-
11	F	61	1.5	1	Labial	4.0	21.6	-	-	+	+	-

Δ lymph pSS: time between diagnosis of pSS and parotid MALT lymphoma, Ann Arbor Musshoff: 1) localized disease: lymphoma located in one or more salivary glands, 2) locally disseminated: lymphoma localized in one or more salivary glands with one or more enlarged regional lymph nodes (>1cm), 3) disseminated disease: localization of lymphoma in one or more salivary glands, with one or more enlarged regional lymph nodes (>1cm)

and/or bone marrow, spleen, liver or other extra nodal site than the salivary gland, or localization of lymphoma in multiple extra nodal sites.²⁰ FS: focus score, GC: germinal center, H&E: hematoxylin and eosin, Bcl6: B cell lymphoma 6 protein, LEL: lymphoepithelial lesions. *Biopsy taken shortly before lymphoma diagnosis.

Table 2: Patient characteristics and histological results of diagnostic labial gland biopsies from pSS developing parotid MALT lymphomas and control labial gland biopsies.

Variable	Labial biopsies prior to parotid MALT lymphoma (n=11)	Labial biopsies from pSS patients without lymphoma (n=22)	P-value Mann-Whitney U test (MWU) or Fisher's exact test (FT)
Female n (%)	11/11 (100%)	20/22 (91%)	0.542 (FT)
Age (year), mean (sd)	47.5 (14.0)	48.7 (17.2)	0.638 (MWU)
Anti-SSA positive, n (%)	11/11 (100%)	22/22 (100%)	-
Anti-SSB positive, n (%)	7/11 (64%)	13/22 (59%)	1.000 (FT)
Anti-RF positive, n (%)	11/11 (100%)	19/22 (86%)	0.534 (FT)
Anti-ANA positive, n (%)	11/11 (100%)	21/22 (96%)	1.000 (FT)
Δ pSS-lymph (year), median (IQR)	4.0 (1.5 – 6.1)	-	-
Δ pSS-FU (year), median (IQR)	-	12.0 (6.3 – 16.8)	-
FS, median (IQR)	1.8 (0.8 – 4.0)	2.7 (1.4 – 3.5)	0.204 (MWU)
FS≥3, n (%)	3/11 (27%)	8/22 (36%)	1.000 (FT)
Area CD45 (%), median (IQR)	20.3 (7.4 – 27.7)	12.7 (9.4 – 19.1)	0.143 (MWU)
LELs based on H&E, n (%)	7/11 (64%)	13/22 (59%)	1.000 (FT)
GC based on H&E, n (%)	2/11 (18%)	4/22 (18%)	1.000 (FT)
GC based on Bcl6, n (%)	3/11 (27%)	5/22 (23%)	1.000 (FT)

Δ lymph-pSS: time between diagnosis of pSS and parotid MALT lymphoma, Δ pSS-FU: time between diagnosis of pSS and last follow up, GC: germinal center, H&E: hematoxylin and eosin, Bcl6: B-cell lymphoma 6 protein.

6a

DISCUSSION

This study shows that the presence of GCs does not differ between diagnostic labial gland biopsies from patients with pSS who did develop parotid MALT lymphoma and patients with pSS patients who did not develop such lymphoma. In H&E stained sections we observed an identical percentage of GCs in both categories of patients (18%). With a more sensitive and specific method to identify GCs, viz. staining for the GC B-cell associated transcription factor Bcl6,¹⁶ a slightly higher incidence of GCs was seen in both groups: 27% for pre-lymphoma patients and 23% for non-lymphoma pSS patients. Although the two groups of patients with pSS are rather small, the percentages of GCs are similar to those reported for labial gland biopsies among the general pSS population.³ Based upon a large number of studies, Risselada et al. reported that the mean weighted percentage of GCs in labial gland biopsies of patients with pSS was 25.1±5.0% (range 18.3-33%) in H&E stained sections. Since there was no difference in the occurrence of GCs in labial gland biopsies of patients with pSS prior to parotid MALT lymphoma development and the matched pSS controls as well as with the general pSS population, we conclude that presence of GCs in labial biopsies is not likely predictive for parotid MALT lymphoma development.

Other studies that examined the predictive value of GCs in NHL development did not restrict themselves to MALT lymphoma.^{9,12,17} In a retrospective analysis of prelymphoma labial gland biopsies from 13 pSS patients with unspecified NHL lymphomas, Risselada et al.⁹ found that in H&E stained sections GCs were present in only three (23%) of the patients. Johnsen et al.¹⁷ showed that in similarly stained labial gland biopsies of pSS NHL patients, 4 out of 12 biopsies (33%) exhibited GCs. The matched control group of pSS patients without malignant lymphoma development showed an even higher percentage of 46% (13/28) GCs in the biopsies. However, in Johnsen's study, biopsies were taken prior to NHL development and simultaneously or even after NHL development.

In contrast to our findings and the aforementioned reports, two earlier studies (Theander et al.¹² and Bombardieri et al.¹⁸) indicated an increased incidence of GCs in diagnostic biopsies preceding NHL development. Theander et al. observed that 6 out of 7 patients had GCs in diagnostic labial salivary gland biopsies, prior to NHL development. Besides differences in patient cohorts, the most likely explanation for the apparent discrepancy between Theander's study and our findings might be the selection of patients with pSS that developed NHL. While Theander et al. took all NHLs into account, we restricted ourselves to NHLs that are typically associated with pSS, namely parotid MALT lymphomas. Remarkably, only one out of seven pSS lymphomas in Theander's retrospective study represented a salivary gland (parotid) MALT lymphoma, making comparison with our study difficult. Bombardieri et al.¹⁸ found 'GC-like structures' in six out of eight (75%) of labial gland biopsies from pSS and patients with secondary Sjögren's preceding parotid MALT lymphoma. However, in this study, GC-like structures were determined by the presence of T-cells, B-cells and CD21⁺ FDC networks. Although CD21⁺ FDC networks are a prerequisite for GC development, their presence does not imply that GCs are indeed present. This may lead to a significant overestimation of the number of GCs in the tissue compared with Bcl6 staining.^{16,19}

In conclusion, there are no indications that the occurrence of GCs in diagnostic labial gland biopsies is increased in patients with pSS who developed parotid MALT lymphoma. Thus, in our opinion, labial salivary gland GCs of patients with pSS are not likely a predictive factor for parotid MALT lymphoma development. Nevertheless, their presence might be of clinical relevance for stratification of pSS patients regarding treatment options. For this reason, uniform histopathological criteria for the assessment of GCs are eagerly awaited.

ACKNOWLEDGEMENTS

Acknowledgements: The authors thank the following pathology departments from the Netherlands for providing residual biopsy material: Pathology Friesland (Leeuwarden), Pathology Gelre Hospital (Apeldoorn), Pathology Rijnstate (Arnhem), Pathology Martini Hospital (Groningen), Pathology University Medical Center Utrecht (Utrecht) and Laboratory Pathology and Medical Microbiology (Eindhoven).

Ethical approval information: Institutional Review Board of the University Medical Center Groningen (METc 2014.211).

REFERENCES

1. Brito-Zerón P, Baldini C, Bootsma H, et al. Sjögren syndrome. *Nat Rev Dis Prim* 2016;2:1-20.
2. Fisher BA, Jonsson R, Daniels T, et al. Standardisation of labial salivary gland histopathology in clinical trials in primary Sjögren's syndrome. *Ann Rheum Dis* 2017;76:1161-68.
3. Risselada AP, Looije MF, Kruize AA, et al. The role of ectopic germinal centers in the immunopathology of primary Sjögren's syndrome: a systematic review. *Semin Arthritis Rheum* 2013;42:368-76.
4. Kroese FGM, Abdulahad WH, Haacke E, et al. B-cell hyperactivity in primary Sjögren's syndrome. *Expert Rev Clin Immunol* 2014;10:483-99.
5. Giannouli S, Voulgarelis M. Predicting progression to lymphoma in Sjögren's syndrome patients. *Expert Rev Clin Immunol* 2014;10:501-12.
6. Voulgarelis M, Ziakas PD, Papageorgiou A, et al. Prognosis and outcome of non-Hodgkin lymphoma in primary Sjögren syndrome. *Medicine (Baltimore)* 2012;91:1-9.
7. Nocturne G, Boudaoud S, Miceli-Richard C, et al. Germline and somatic genetic variations of TNFAIP3 in lymphoma complicating primary Sjögren's syndrome. *Blood* 2013;122:4068-76.
8. Keszler a, Adler LI, Gandolfo MS, et al. MALT lymphoma in labial salivary gland biopsy from Sjögren syndrome: importance of follow-up in early detection. *Oral Surg Oral Med Oral Pathol Oral Radiol Elsevier*; 2013;115:e28-33.
9. Risselada AP, Kruize AA, Goldschmeding R, Lafeber FPJG, Bijlsma JWJ, van Roon JAG. The prognostic value of routinely performed minor salivary gland assessments in primary Sjögren's syndrome. *Ann Rheum Dis* 2014;73:1537-40.
10. Fragkioudaki S, Mavragani CP, Moutsopoulos HM. Predicting the risk for lymphoma development in Sjögren syndrome: An easy tool for clinical use. *Medicine (Baltimore)* 2016;95:e3766.
11. Fragkioudaki S, Mavragani CP, Moutsopoulos HM. Predicting the risk for lymphoma development in Sjögren syndrome: An easy tool for clinical use. *Medicine (Baltimore)* 2016;95:e3766.
12. Theander E, Vasaitis L, Baecklund E, et al. Lymphoid organisation in labial salivary gland biopsies is a possible predictor for the development of malignant lymphoma in primary Sjögren 's syndrome. *Ann Rheum Dis* 2011;161:1363-8.
13. Shiboski CH, Shiboski SC, Seror R, et al. 2016 American College of Rheumatology/European League Against Rheumatism classification criteria for primary Sjögren's syndrome A consensus and data-driven methodology involving three international patient cohorts. *Ann Rheum Dis* 2017;76:9-16.
14. Delli K, Haacke EA, Kroese FGM, et al. Towards personalised treatment in primary Sjögren's syndrome: baseline parotid histopathology predicts responsiveness to rituximab treatment. *Ann Rheum Dis*. 2016;75:1933-8.
15. Greenspan JS, Daniels TE, Talal N, et al. The histopathology of Sjögren's syndrome in labial salivary gland biopsies. *Oral Surg Oral Med Oral Pathol* 1974;37:217-29.
16. Delli K, Haacke EA, Ihrler S, et al. Need for consensus guidelines to standardise the assessment of germinal centres and other histopathological parameters in salivary gland tissue of patients with primary Sjögren's syndrome. *Ann Rheum Dis* 2016;75:e32.
17. Johnsen SJ, Gudlaugsson E, Skaland I, et al. Low Protein A20 in Minor Salivary Glands is Associated with Lymphoma in Primary Sjögren's Syndrome. *Scand J Immunol* 2016;83:181-7.
18. Bombardieri M, Barone F, Humby F, et al. Activation-Induced Cytidine Deaminase Expression in Follicular Dendritic Cell Networks and Interfollicular Large B Cells Supports Functionality of Ectopic Lymphoid Neogenesis

- in Autoimmune Sialoadenitis and MALT Lymphoma in Sjogren's Syndrome. *J Immunol* 2007;179:4929–38.
19. Jonsson M V, Skarstein K. Follicular dendritic cells confirm lymphoid organization in the minor salivary glands of primary Sjögren's syndrome. *J Oral Pathol Med* 2008;37:515–21.
20. Musshoff K. Clinical staging classification of non-Hodgkin's lymphomas (author's transl). *Strahlentherapie* 1977;153:218–21.

SUPPLEMENTARY MATERIALS

Supplementary Table 1: Patients characteristics and histopathology results of labial (minor) salivary gland biopsies from matched pSS patients (n=22) who did not develop a lymphoma during the course of their disease.

Patient	Gender	Age pSS (year)	Δ pSS FU (year)	Biopsy	FS	CD45 (%)	GC H&E	GC Bcl6	LEL H&E	Anti-SSA	Anti-SSB
1	F	46	22.3	Labial	3.2	19.0	-	-	+	+	+
2	M	39	21.2	Labial	0.5	7.9	+	+	+	+	-
3	F	34	20.7	Labial	2.7	12.7	-	-	+	+	+
4	F	29	2.2	Labial	1.2	10.0	-	-	+	+	-
5	F	40	7.4	Labial	1.5	3.9	-	-	-	+	-
6	F	58	7.5	Labial	12.0	18.3	-	-	-	+	+
7	F	52	6.4	Labial	4.8	12.0	-	-	-	+	+
8	F	64	2.9	Labial	1.1	8.1	-	-	-	+	-
9	F	17	15.5	Labial	6.5	20.8	-	-	-	+	-
10	F	20	11.8	Labial	2.3	14.2	+	+	+	+	+
11	F	38	5.9	Labial	2.7	12.7	-	-	-	+	-
12	F	66	.3	Labial	3.2	19.6	-	-	-	+	-
13	F	66	17.6	Labial	2.7	17.3	-	-	+	+	+
14	F	65	12.9	Labial	3.2	10.4	-	-	+	+	+
15	F	38	12.8	Labial	4.3	16.1	-	-	+	+	+
16	F	68	11.3	Labial	2.9	19.4	+	+	+	+	-
17	F	22	15.7	Labial	0.2	1.9	-	-	-	+	+
18	F	53	12.2	Labial	4.6	12.0	-	-	+	+	-
19	M	66	7.5	Labial	1.1	4.0	-	-	-	+	+
20	F	62	16.6	Labial	1.9	9.8	-	-	+	+	+
21	F	59	17.5	Labial	2.8	22.4	+	+	+	+	+
22	F	72	6.1	Labial	2.6	26.6	-	+	+	+	+

Δ pSS FU: time between diagnosis of pSS and last follow up, GC: germinal center, H&E: hematoxylin and eosin, Bcl6: B-cell lymphoma 6 protein, LEL: lymphoepithelial lesion.





CHAPTER 6b

Germinal centres in diagnostic biopsies of pSS patients are not a risk factor for non-Hodgkin's lymphoma but a reflection of high disease activity

Erlin A Haacke^{1,2}
Bert van der Vegt²
Arjan Vissink³

Fred KL Spijkervet³
Hendrika Bootsma¹
Frans GM Kroese¹

Department of ¹Rheumatology & Clinical Immunology, ²Pathology and Medical Biology, ³Oral and Maxillofacial Surgery, University of Groningen, University Medical Center Groningen, the Netherlands

Modified version of: Arthritis Rheumatol 2019;71:170-171

Dear Editor, with great interest we have read the article of Sène et al.¹ in which ectopic germinal centres (GCs) in labial gland biopsies of primary Sjögren syndrome (pSS) patients were found predictive for Non-Hodgkin's lymphoma (NHL) development later in the disease. In the univariate analysis the presence of GCs in these biopsies was not significantly different between pSS patients who developed NHL or pSS patients who did not. However, multivariate analysis revealed that presence of GCs in biopsies was an independent predictor for NHL development.¹ This study adds to the ongoing discussion about the presence of ectopic GCs in pSS diagnostic salivary gland biopsies as a risk factor for subsequent NHL development. The study of Theander et al.² showed that GCs in diagnostic labial gland biopsies was predictive for NHL development in pSS patients, whereas we³ and others^{4,5} did not detect such an association. As discussed extensively,^{3,6} a major reason for the apparent discrepancy in the different studies was the variation in NHL-subtypes that were included.

Remarkably, half of the pSS patients in the study of Sène et al.¹ were male, whereas in the other studies that evaluated the presence of GCs as risk factor, the majority of patients (>81%) were females.²⁻⁵ Whether the predictive value of presence of GCs in diagnostic biopsies differs between males and females is not known.

A very unusual observation in the study of Sène et al.¹ was that **all** pSS patients who developed NHL, had a monoclonal gammopathy (MG). In pSS patients in general, the presence of MG is 4-22%.^{1,7,8} We observed MG at time of lymphoma diagnosis in 4/8 (50%) pSS patients with a parotid MALT lymphoma (Haacke et al., unpublished data). In another recent study only 3/7 (43%) pSS patients with pulmonary MALT lymphomas exhibited MG.⁹ Presence of MG is known as a risk factor for NHL development, but is also associated with higher disease activity.^{8,10} The presence of MG in pSS pre-lymphoma patients in the study of Sène et al.¹ could thus also be a reflection of high disease activity (ESSDAI) which is an independent predictor for NHL development.¹¹

Also the presence of GCs in biopsies is associated with high disease status.¹² Since disease activity as measured by ESSDAI can change over time,¹³ the time point when the diagnostic pSS biopsy is taken, is of crucial importance. If a labial gland biopsy is taken during a period of relatively low disease activity, the likelihood of presence of GCs might consequently be low. On the other hand, when a diagnostic pSS salivary gland biopsy is taken in a period of high disease activity, the chance of finding GCs is higher.

Thus, both GCs and MG are associated with higher disease status, but there is no clear indication that presence of *ectopic* GCs is a prerequisite for MALT lymphoma development. There are many pSS patients with GCs in their salivary gland biopsies that do not develop NHL. Of note, presence of GCs is usually assessed in labial salivary glands, which are not the sites where MALT lymphoma preferentially develop. We conclude that for prediction of pSS patients who are at risk for NHL development, clinical and laboratory factors such as low C4, RF-positivity, presence of cryoglobulin,

highly active disease, purpura, lymphadenopathy and especially persistent parotid enlargement^{5,11,14} are more important than presence of GCs in diagnostic salivary gland biopsies.

REFERENCES

1. Sène D, Ismael S, Forien M, et al. Ectopic germinal centre-like structures in minor salivary gland biopsy predict lymphoma occurrence in patients with primary Sjögren syndrome. *Arthritis Rheumatol* 2018;70:1481-88.
2. Theander E, Vasaitis L, Baecklund E, et al. Lymphoid organisation in labial salivary gland biopsies is a possible predictor for the development of malignant lymphoma in primary Sjögren's syndrome. *Ann Rheum Dis* 2011;161:1363-68.
3. Haacke EA, Vegt B van der, Vissink A, et al. Germinal centres in diagnostic labial gland biopsies of patients with primary Sjögren's syndrome are not predictive for parotid MALT lymphoma development. *Ann Rheum Dis* 2017;76:1781-84.
4. Johnsen SJ, Gudlaugsson E, Skaland I, et al. Low Protein A20 in Minor Salivary Glands is Associated with Lymphoma in Primary Sjögren's Syndrome. *Scand J Immunol* 2016;83:181-87.
5. Fragkioudaki S, Mavragani CP, Moutsopoulos HM. Predicting the risk for lymphoma development in Sjögren syndrome: An easy tool for clinical use. *Medicine (Baltimore)* 2016;95:e3766.
6. Kroese FGM, Haacke EA, Bombardieri M. The role of salivary gland histopathology in primary Sjögren's syndrome: promises and pitfalls. *Clin Exp Rheumatol* 2018;36:222-33.
7. Baimpa E, Dahabreh IJ, Voulgarelis M, et al. Hematologic manifestations and predictors of lymphoma development in primary Sjögren syndrome: clinical and pathophysiologic aspects. *Medicine (Baltimore)* 2009;88:284-93.
8. Brito-Zerón P, Kostov B, Fraile G, et al. Characterization and risk estimate of cancer in patients with primary Sjögren syndrome. *J Hematol Oncol* 2017;10:90.
9. Yachoui R, Leon C, Sitwala K, et al. Pulmonary MALT Lymphoma in Patients with Sjögren's Syndrome. *Clin Med Res* 2017;15:6-12.
10. Yang Y, Chen L, Jia Y, et al. Monoclonal gammopathy in rheumatic diseases. *Clin Rheumatol*. 2018;37:1751-62.
11. Nocturne G, Virone A, Ng W-F, et al. Rheumatoid Factor and Disease Activity Are Independent Predictors of Lymphoma in Primary Sjögren's Syndrome. *Arthritis Rheumatol (Hoboken, NJ)* 2016;68:977-85.
12. Risselada AP, Looije MF, Kruize AA, et al. The role of ectopic germinal centers in the immunopathology of primary Sjögren's syndrome: a systematic review. *Semin Arthritis Rheum* 2013;42:368-76.
13. Gottenberg J-E, Seror R, Saraux A, et al. Evolution of Disease Activity over a 5-Year Period in the 395 Patients with Primary Sjögren's Syndrome of the Assess Prospective Cohort [Abstract]. *Arthritis Rheumatol* 2016;68.
14. Nishishinya MB, Pereda CA, Muñoz-Fernández S, et al. Identification of lymphoma predictors in patients with primary Sjögren's syndrome: a systematic literature review and meta-analysis. *Rheumatol Int* 2015;35:17-26.





PART 3

Histopathological changes
after biological treatment





CHAPTER 7a

Towards personalized treatment in primary Sjögren's syndrome: baseline parotid histopathology predicts responsiveness to rituximab treatment

Erlin A Haacke^{1,2}
Konstantina Delli³
Frans GM Kroese¹
Rodney P Pollard³
Stephan Ihrler⁴

Bert van der Vegt²
Arjan Vissink³
Hendrika Bootsma¹
Frederik KL Spijkervet³

Department of ¹Rheumatology & Clinical Immunology, ²Pathology and Medical Biology,
³Oral and Maxillofacial Surgery, University of Groningen, University Medical Center
Groningen, the Netherlands, ⁴Laboratory for Dermatohistology & Oral Pathology,
Munich, Germany

Modified version of: Ann Rheum Dis. 2016;75:1933-1938

ABSTRACT

Objectives: The aims of this study were (1) to assess the effect of rituximab (RTX; anti-CD20) treatment in primary Sjögren's syndrome (pSS) patients based on sequential parotid biopsies obtained in a placebo-controlled, randomized clinical trial, and (2) to assess the prognostic value of the histological characteristics of parotid gland tissue with regard to responsiveness to RTX treatment.

Methods: In a double-blinded, placebo-controlled trial, sequential parotid gland biopsies were taken from 20 RTX-treated and 10 placebo-treated pSS patients, at baseline and 12 weeks after treatment. The relative amount of lymphocytic infiltrate (stained for CD45), absolute number of T-cells and B-cells per mm² parenchyma (stained for CD3 and CD20, respectively), focus score, number of germinal centers and of lymphoepithelial lesions per mm² in parotid gland parenchyma were assessed. Histopathological data were compared between clinical responders (decrease in European League Against Rheumatism EULAR Sjögren's Syndrome Disease Activity Index (ESSDAI) score of ≥ 3 at 12 weeks compared to baseline) and non-responders (change in ESSDAI < 3) to RTX treatment.

Results: In RTX-treated patients, a significant reduction in the number of CD20⁺ B-cells/mm² parenchyma was observed, while no such reduction was observed in placebo-treated patients. The number of CD3⁺ T-cells/mm² in parenchyma did not change in either group. Furthermore, the number and the severity of lymphoepithelial lesions/mm² and number of germinal centers/mm² was significantly reduced in RTX-treated patients, but did not change in placebo-treated patients. When comparing the pre-treatment characteristics of clinical responders with non-responders, the median number of CD20⁺ B-cells/mm² parenchyma at baseline was significantly higher in responders (1871 versus 353 cells/mm², $p=0.001$). Other histopathological baseline characteristics were not predictive for response to RTX treatment.

Conclusion: RTX treatment in pSS leads to a major reduction of lymphocytic infiltration and to fewer B-cells, germinal centers and lymphoepithelial lesions in parotid gland parenchyma. A high pre-treatment number of CD20⁺ B-cells/mm² parotid gland parenchyma predicts better responsiveness of pSS patients to RTX treatment. Pre-treatment parotid gland histopathological characteristics could therefore contribute to a more personalized treatment approach to pSS.

INTRODUCTION

Primary Sjögren's syndrome (pSS) is a common rheumatic disease, with a prevalence of 60.8 (95% CI 43.7 to 77.9) cases per 100 000 inhabitants in the total population.¹ PSS commonly affects salivary and lacrimal glands, resulting in a sensation of dry mouth (xerostomia) and dry eyes (keratoconjunctivitis sicca). Although the exact pathogenic mechanism has not been fully elucidated, in patients with pSS the minor and major salivary glands are characteristically infiltrated by mononuclear lymphoid cells, which form periductal foci. The classic glandular lesion is composed of a lymphoid infiltrate of T and B lymphocytes, whose distribution may vary according to lesion severity.² A central role is attributed to B-cells, which to be hyperactive.³ PSS patients have an increased risk of developing lymphoproliferative diseases, which is about 4% during the first 5 years, 10% at 15 years and 18% after 20 years post-diagnosis.⁴ Consequently, about 7.5% of patients with pSS develop malignant B-cell lymphoma. In 48-75% of these cases, this is the mucosa-associated lymphoid tissue (MALT) type of lymphoma.⁵⁻⁷ Most commonly, these lymphomas arise in the parotid glands. The assumed role of hyperactive B-cells in the pathogenesis of pSS is supported by the observed beneficial objective and subjective clinical effects of B-cell depletion by rituximab (RTX), a chimeric monoclonal antibody that binds to the B-cell surface antigen CD20.⁸⁻¹⁶ Significant response was observed in most trials, except from one large randomized clinical trial, the TEARS study.¹⁷ Posthoc application of the Sjögren's syndrome response index (SSRI), showed also significant response rate difference between RTX and placebo in TEARS.¹⁸ Because there are some concerns about the efficacy of rituximab, the TRACTISS study is aiming to provide evidence whether rituximab improves the clinical outcomes.¹⁹ The final results of the TRACTISS study, including a subanalysis on responders and non-responders, are eagerly awaited.

In a previous open-label phase II study, based on sequential parotid biopsies of 5 pSS patients, we showed that RTX treatment might result in restoration of secretory tissue at a glandular level in responding patients.²⁰ In that study we observed a reduction of the lymphocytic infiltration with partial to complete loss of germinal centers (GC) and redifferentiation of lymphoepithelial lesions (LEL) to regular striated ducts. However, major limitations of the study by Pijpe et al. were the small number of patients and lack of a placebo group.²⁰ Therefore, the aims of the current study were (1) to assess the effect of RTX treatment in pSS patients based on sequential parotid biopsies obtained in a placebo-controlled, randomized clinical trial, and (2) to assess the prognostic value of the histological characteristics of parotid gland tissue with regard to responsiveness to RTX treatment.

7a

MATERIALS AND METHODS

Patients

Thirty patients with pSS were treated in a randomized double-blinded placebo-controlled trial on days 1 and 15 with either 1000 mg RTX i.v. (Roche, Woerden, the Netherlands; n= 20) or placebo i.v. (n= 10) at the University Medical Center Groningen, the Netherlands, as described before.¹⁴ All patients fulfilled the American European Consensus Group Criteria (AECG) criteria for pSS.²¹ To minimise side effects (infusion reactions, serum sickness), all patients, including the placebo treated patients, were pre-medicated with methylprednisolone (100 mg i.v.), acetaminophen (1000 mg p.o.) and clemastine (2 mg i.v.), and received 60 mg oral prednisone on days 1 and 2, 30 mg on days 3 and 4, and 15 mg on day 5 after each infusion.

An incisional biopsy was taken under local anesthesia from the same parotid gland before and 12 weeks after therapy.²² The European League Against Rheumatism (EULAR) Sjögren's Syndrome Disease Activity Index (ESSDAI)^{23,24} was assessed at the same time points by two experienced rheumatologists, who were blinded to the treatment group, in order to evaluate possible systemic complications.¹⁶ With regard to response to RTX treatment, patients were categorized into two groups: clinical responders, if the decrease in ESSDAI was 3 points or more at 12 weeks after treatment compared to baseline, and clinical non-responders, if the change of ESSDAI was less than 3 points. The cut-off of 3 points was chosen because this difference indicates a clinically relevant effect.²⁵ All patients provided informed consent in accordance with the ethics committee of the University Medical Center Groningen (METC approval: 05.229).

Histopathologic analysis

Parotid gland tissue biopsies were fixed in 4% formaldehyde, embedded in paraffin, cut at a thickness of 3 μm , and stained with hematoxylin and eosin. The focus score (defined as ≥ 50 lymphocytes per 4 mm^2 glandular tissue), and the number of GC/ mm^2 parotid gland parenchyma were determined. GC were defined as a clearly visible lighter area in a lymphocytic infiltrate containing cells that are usually present in classical germinal centers, like follicular dendritic cells, centrocytes or centroblasts and macrophages. LEL are expressed in LEL/ mm^2 of parotid gland parenchyma, excluding intraparenchymal connective and fat tissue. LEL were evaluated in immunohistochemically stained tissue sections, stained for CD20 as B-lymphocytes predominate in the LEL. A LEL was defined as a cross section of a striated duct with infiltration of CD20⁺ B-cells within the basement membrane combined with hyperplasia of the epithelium. To evaluate regeneration of the ducts, LEL were subcategorized into three stages (Figure 1A): stage 1) LEL affecting less than 50% of the epithelium of the striated duct (partial LEL); stage 2) LEL affecting between 50% and 100% of the epithelium of the striated duct (developed LEL); stage 3) LEL with fully

circumferentially affected epithelium without lumen (occluded LEL). For histopathological evaluation, biopsies were independently scored by 2 investigators (R.P.P. and S.I.) in a blinded setting. In case of discrepancy, a definitive score was established by consensus.

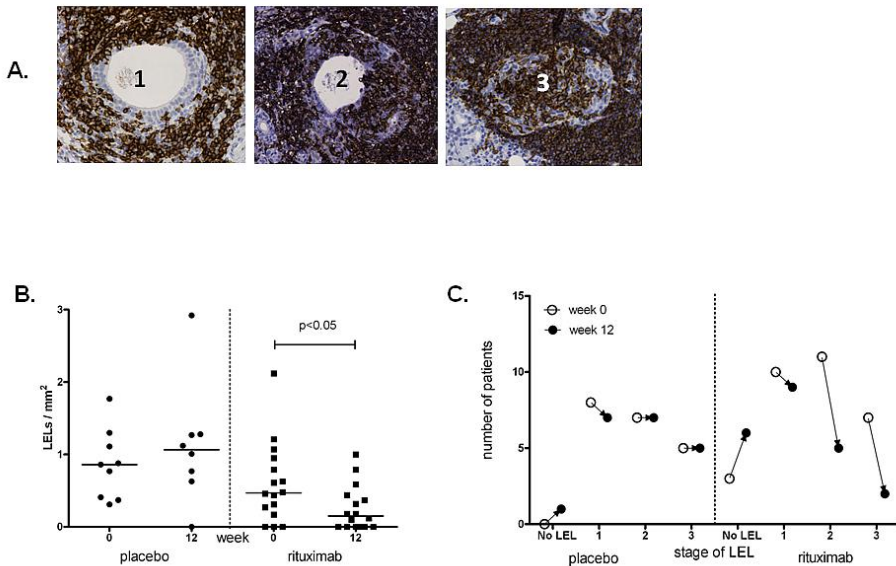


Figure 1: **A)** Classification of lymphoepithelial lesions (LELs) in three stages as stained with CD20:20 (1) LEL affecting less than 50% of the epithelium of the striated duct (partial LEL); (2) LEL affecting between 50% and 100% of the epithelium of the striated duct (developed LEL); (3) LEL with fully circumferential affected epithelium without lumen (occluded LEL). **B)** Number of LELs/mm² of parenchyma in parotid glands of patients with primary Sjögren's syndrome (pSS). Horizontal lines indicate median values. **C)** Presence of three stages of LELs/mm² in placebo-treated and rituximab (RTX)-treated patients at week 0 and week 12; y axis indicates the total number of patients, while x axis the presence of different stages of LEL.

Immunohistochemical analysis

Immunostaining was utilized for the analysis of lymphocytic infiltrate and was performed as follows. Parotid glands were fixed in 4% buffered formaldehyde, embedded in paraffin wax and sectioned into 4-µm-thick serial sections. Sections were stained after deparaffinisation, pre-treatment with Ultra CC1 (Ventana Medical Systems, Inc, USA), antigen retrieval and endogenous peroxidase blocking using the Benchmark machine. Sections were immunohistochemically stained with anti-CD45 (dilution 1:25, Dako, Heverlee, Belgium, clone 2B11+PD7/26), anti-CD79a (dilution 1:100, Dako, Heverlee, Belgium, clone JCB117), anti-CD20 (dilution 1:200, Dako, Heverlee, Belgium, clone L-26) and anti-CD3 (dilution 1:20, Monosan, Uden, the Netherlands, clone PS-1) antibodies. The sections were then treated with peroxidase-labelled secondary antibody and visualized with the chromogen DAB (3,3' Diaminobenzidine) solution.

The relative amount of CD45 positive lymphocytic infiltrates was assessed in relation to the total amount of tissue parenchyma by morphometry with use of ImageJ software (v1.46). Using HistoQuest software, version 3.5.3.0171, two markers were created, the DAB master marker (CD20) and the hematoxylin non-master marker (nucleus). For the master marker, multiple reference shade was set on 8 with a background threshold range of 5–255. Ring mask and identified cell mask were used. By using a color picker, the shade was chosen directly from a positively stained CD20 cell. One whole section was analyzed excluding intraparenchymal connective and fat tissue leaving multiple regions of interest (ROIs). For the assessment of CD20⁺ cells, scattergrams were created for each ROI, allowing the visualization of corresponding positive cells in the source ROI, using the real-time back-gating feature. To correct false events, a specific gate according to cell size and intensity of CD20 staining was defined and applied to all analyzed samples. CD20⁺ cells were quantified according to the selected marker and gate. By using the real-time back-gating feature, automatically counted CD20⁺ cells were visualized and controlled. The CD20⁺ cell count (number of cells/mm²) for each analyzed ROI was obtained. The same procedure was followed for CD3⁺ cell count.

Statistical analysis

Analysis was carried out with IBM SPSS Statistics 20 (SPSS, Chicago, Illinois, USA). Mann-Whitney U test was used to compare differences between the RTX and placebo groups or between clinical responders and non-responders. Wilcoxon signed-rank test was used to compare differences over time within groups. Spearman's correlation coefficient was used to analyze the relationship between histopathology and ESSDAI. Correlations (p) <0.3 were interpreted as a poor association, 0.3–0.6 as moderate, 0.6–0.8 as good and >0.8 as excellent.¹⁵ P-values <0.05 were considered as statistically significant. Power analysis was performed with Statistical Power Calculator (DDS Research, Washington DC, USA).

RESULTS

From the total group of 30 patients, five patients had to be excluded from histopathological analysis, due to serum sickness ($n=1$, RTX-group) or insufficient biopsy material ($n=3$, RTX-group); one patient dropped out of the study (placebo group). Thus, complete evaluation could be performed of parotid gland biopsies taken from 16 RTX treated patients and 9 placebo-treated patients.

Lymphocytic infiltrate in parotid glands

No differences at baseline between the RTX-treated group and the placebo-treated group were found regarding the focus score, relative area of CD45 staining, numbers of CD20⁺ B-cells and CD3⁺ T-cells and proportion of biopsies containing GC (data not shown).

After treatment, the focus score did not change significantly in either the RTX-treated group or the placebo-treated group (Table 1). However, CD45 staining demonstrated a significant decrease of the relative area of infiltrates at 12 weeks after RTX treatment. In the placebo group no change was observed between baseline values and 12-week post-treatment values (Figure 2, Table 1).

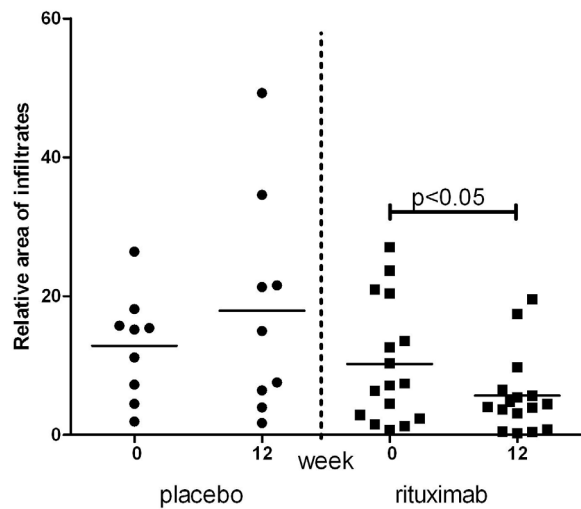


Figure 2: Effect of placebo (n=9) and rituximab (RTX) (n=16) treatment on relative areas of infiltrates (stained with CD45; %), in parotid gland parenchyma of patients with primary Sjögren's syndrome (pSS). Horizontal lines indicate median values.

By counting the number of CD20⁺cells/mm² of parenchyma, a significant decrease was observed in the number of B-cells (1172 versus 355 cells/mm², p=0.001) in the glandular tissue at 12 weeks after RTX treatment compared to baseline (Figure 3, Table 1). In the placebo-treated group the number of CD20⁺/mm² of parenchyma of the parotid glands at week 12 was not statistically different from the number of CD20⁺ cells at baseline (Table 1). The number of CD3⁺cells/mm² of parenchyma remained unaffected after 12 weeks both in the placebo and RTX-treated group (Table 1).

GC were present at baseline in 67% and 68% of the parotid glands of the placebo and RTX-treated patients, respectively. RTX treatment resulted in a significant decrease in the total number of GC/mm² (Figure 4, Table 1). Twelve out of 16 parotid glands (75%) were completely devoid of GC 12 weeks after treatment with RTX. In the placebo group, no significant difference was observed in the number of GC/mm² between baseline levels and 12 weeks after treatment.

Table 1: Histopathological and immunohistochemical data [median values and interquartile range (Q1-Q3)] before and after RTX or placebo therapy.

	Placebo (n=9)		
	Baseline	Week 12	p
Focus score	1.63 (0.84-3.27)	1.97 (1.47-2.88)	0.678
LELs/mm ²	0.77 (0.38-1.05)	1.11 (0.67-1.23)	0.310
GCs/mm ²	0.06 (0-0.23)	0.09 (0.03-0.15)	0.735
CD45 (%)	15.2 (5.86-16.92)	14.8 (5.2-28.06)	0.374
CD20 ⁺ cells/mm ²	2709 (1469-4395)	3664 (2256-7979)	0.173
CD3 ⁺ cells/mm ²	863 (359-1483)	1712 (725-2878)	0.953

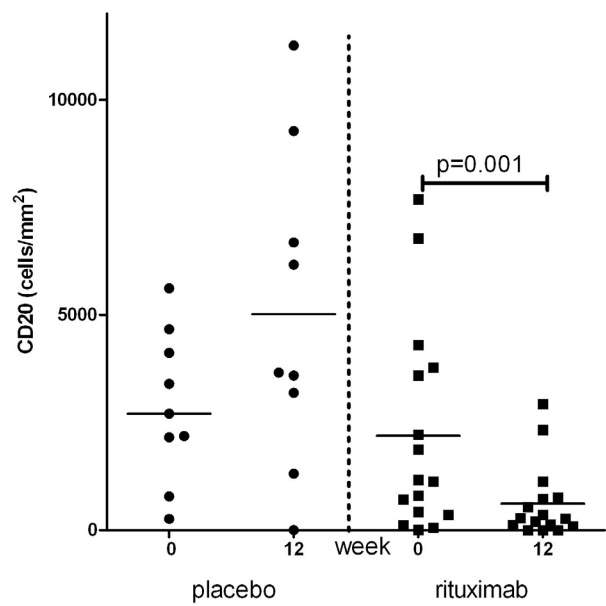


Figure 3: Effect of placebo (n=9) and rituximab (RTX) (n=16) treatment on number of CD20+ cells/mm2 of parenchyma in parotid glands of patients with primary Sjögren's syndrome (pSS). Horizontal lines indicate median values.

RTX-treated (n=16)		
Baseline	Week 12	p
1.7 (0.87-2.5)	1.19 (0.59-1.23)	0.179
0.48 (0.24-0.91)	0.18 (0-0.42)	0.011
0.07 (0-0.28)	0 (0-0.1)	0.004
7.45 (1.85-22.35)	3.96 (0.48-7.71)	0.011
1172 (389-5278)	355 (51-743)	0.001
315 (124-2157)	180 (91-570)	0.535

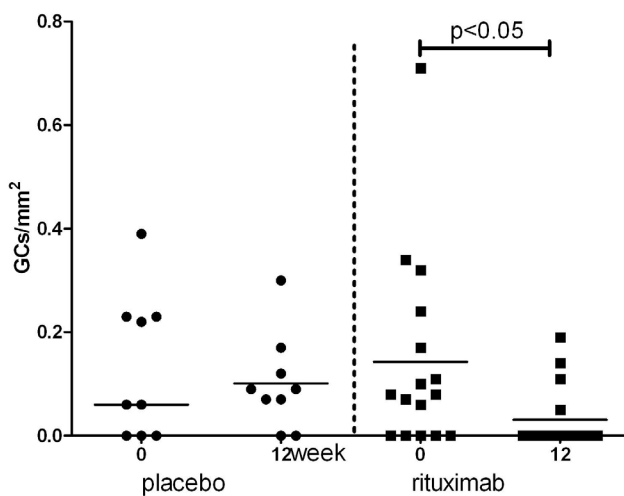


Figure 4: Number of germinal centres (GCs)/mm² of parenchyma in parotid glands of patients with primary Sjögren's syndrome (pSS). Horizontal lines indicate median values.

Lymphoepithelial lesions

At baseline, no differences were observed in the presence of LEL in the parotid gland parenchyma between the group of RTX-treated patients and the placebo treated patients (data not shown). In the RTX-treated group, a significant decrease in the total number of LEL/mm² was observed after 12 weeks of treatment (Figure 1B, Table 1). In 6 out of 16 patients (38%), LEL were completely absent after RTX treatment. In the placebo group, no significant change was observed in the amount of LEL/mm² after 12 weeks (Figure 1B, Table 1). Besides the number of LEL/mm², the severity of the lesions also appeared to decrease; all stages of LEL seemed to transform to a less severe stage. Detailed data regarding the presence of all stages of LEL/mm² in placebo and RTX-treated patients at week 0 and week 12 is presented in Figure 1C.

Histopathology and ESSDAI

Of the 16 patients that were treated with RTX, 11 patients (69%) improved by 3 or more ESSDAI points and were therefore considered to be clinical responders.²⁵ The other 5 were considered to be non-responders. The supplementary table shows the number (%) of patients having any degree of activity per ESSDAI domain (score at least 1) before and after RTX therapy, stratified for responders and non-responders.

The baseline (pre-treatment) histopathological parameters (CD20⁺ cells/mm², CD3⁺ cells/mm², CD45⁺ relative infiltrate, GC/mm², LELs/mm² and focus score) as well as CD19-positive B-cell subsets determined by flow-cytometry in the peripheral blood (i.e., CD38Low CD27-, CD38High CD27-, CD27 Low CD38-, CD27High CD38-, CD38Low CD27Low, CD38High CD27High, CD27Low CD38High, CD27High CD38Low, CD38- CD27-) of responders and non-responders to RTX treatment were subjected to additional statistical analysis. In responders, the baseline number of CD20⁺ cells/mm² was significantly higher in comparison to non-responders [1871 (Q1-Q3=801-4310) cells/mm² versus 353 (Q1-Q3=35-2102) cells/mm²; Figure 5]. At an alpha level of 5% it was calculated that the number of responders and non-responders would give us a power of 94.2% to assume that their baseline number of CD20⁺ cells/mm² could serve as potentially prognostic factor with regard to responsiveness to RTX treatment. The other baseline histological characteristics, as well as baseline B-cell subsets determined by flow-cytometry in the peripheral blood, did not differ significantly between responders and non-responders. Of note, there was no correlation between the absolute numbers of CD20⁺ B-cells/mm² of parenchyma and ESSDAI or between B-cell subsets in peripheral blood and ESSDAI.

Furthermore, in RTX treated patients the change in ESSDAI correlated with the change in the number of CD20⁺ cells/mm² of parenchyma ($p=0.706$ and $p<0.05$). No other statistically and clinically significant correlations were found for the changes between baseline and 12 weeks.

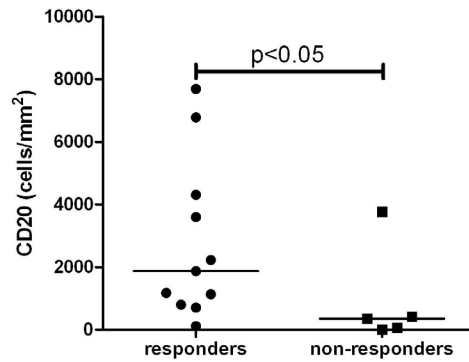


Figure 5: Number of baseline CD20⁺ cells/mm² in clinical responders (n=11) and non-responders (n=5), $p<0.05$. Horizontal lines indicate median values.

DISCUSSION

We demonstrated that RTX treatment significantly reduced the overall lymphocytic infiltrate with a major loss of the B-cell component and number of GC/mm² of parotid gland parenchyma in pSS patients. In addition, a major reduction of the quantity and severity of LEL was apparent, reflecting significant restoration of the striated ducts.

RTX treatment results in a considerable decrease in the number of B-cells in the parotid gland tissue. Although this is reflected by a decrease in the amount of infiltrate, as measured by staining for CD45, this is not manifested by a decrease in the focus score. This apparent discrepancy can be explained by the fact that the foci also contain high numbers of T-cells, which may outnumber the number of B-cells², and which are not affected in significant numbers by RTX treatment. The focus score is therefore not an appropriate criterion to measure the local effect of RTX on the periductal lymphocytic infiltration. Although RTX treatment results in the almost complete absence of B-cells in the peripheral blood of patients with pSS²⁶, this is thus not accompanied by a complete loss of B-cells in parotid salivary gland tissue. These results are in line with other studies in pSS^{20,28} and rheumatoid arthritis²⁹⁻³¹ showing a certain degree of persistence of B-cells in the local tissue after RTX treatment. In contrast, Devauchelle-Pensec et al. reported a total depletion in B-cells in labial salivary glands of pSS patients after RTX treatment.¹⁰ However, in that study only a very low number of the pSS patients (6 out of 15) showed significant numbers of B-cells in the periductal infiltrates at baseline. This is remarkable, since B-cells usually make up to 20-60% of the lymphocytes in the infiltrates of the labial glands of pSS patients, depending upon the grade of the lesion.²

In this study at baseline the included patients had high systemic activity, as indicated by the relatively high ESSDAI scores, and the high numbers of GC/mm².³² We observed a strong reduction of GCs in the parotid tissue after RTX treatment; in several patients we even observed a complete absence of GCs. This is striking, since not all B-cells are depleted in the parotid glands, and GC B-cells may be relatively more resistant for anti-CD20 therapy compared to other B-cells, as shown by Gong et al. in a murine model for human CD20 expression.³³ A possible explanation for the strong depletion of GCs in the parotid tissue might be that RTX treatment also results in a significant reduction of follicular helper T cells (T_{FH}), as indicated by analysis of peripheral blood samples (Verstappen et al. 2015, manuscript in preparation). T_{FH} cells are essential for the development of GCs at local sites. These cells are present in the salivary gland tissue of pSS patients³⁴, where they may drive GC formation and generation of plasma cells. It is therefore possible that the relative absence of T_{FH} in the salivary gland tissue after RTX treatment contributes to the loss of GC activity in these pSS patients.

LEL develop in striated ducts in pSS patients, particularly in the parotid glands. The epitheliotropic autoimmune inflammation of the intraepithelial lymphocytes results in the reaction of the epithelium and induction of these lesions.³⁵ RTX treatment not only results in a significant reduction of the number CD20⁺ B-cells in the periductal infiltrates, but also in a recovery of the LEL, as revealed by a considerable reduction of the severity of the lesions at all stages (Figure 1C). Such a restoration/redifferentiation of LEL was also observed in the small RTX treatment study (5 patients) described by Pijpe et al.²⁰ Apparently, RTX treatment also results in depletion of B-cells within the basement membrane of striated ducts. To explain this, we have hypothesized that the trigger for LEL formation is diminished, and as a result less epithelial reaction takes place leading to reduced proliferation and finally anatomical restoration of the striated ducts. The trigger for LEL formation is unknown, but B-cell derived cytokines may possibly be responsible for this. This notion is in line with the finding of Pollard et al., who showed in the same cohort of RTX-treated patients that the serum levels of pro-inflammatory cytokines (e.g. IL-6) decreased significantly.³⁶

Patients with pSS have different genetic backgrounds, demographic features and prognosis and exhibit a wide variety of clinical manifestations, involving a number of pathophysiological pathways.³⁷ Personalized treatment, i.e. providing 'the right patient with the right drug at the right dose at the right time'³⁸, will therefore be the key to treating pSS. An important finding in our study was that clinical responders to RTX treatment had a higher number of CD20⁺ B-cells/mm² of parenchyma parotid gland tissue at pre-treatment (baseline) compared to non-responders. Furthermore, we also observed a correlation between the change in the number of CD20⁺ cells/mm² of parenchyma and the change in ESSDAI. When higher numbers of B-cells are present in the parotid gland parenchyma, it is therefore possible that RTX treatment may result in depletion of more absolute numbers of B-cells responsible for the disease activity (measured by ESSDAI) than when lower numbers of B-cells are present in the tissue. The baseline number of B-cells/mm² of parenchyma of

parotid gland may therefore determine patients' response to treatment with RTX and may be considered as a biomarker for a more personalized treatment approach to pSS patients. The nature of these disease-associated B-cells that are reduced after RTX treatment needs to be elucidated. These cells are probably not antibody-producing cells, since antibody producing cells persist in the parotid salivary glands after RTX treatment.²⁸ Alternatively, these cells may represent cytokine-producing B-cells.³⁶

Although the change in number of B-cells in the infiltrates of the salivary glands correlated to the change in ESSDAI after RTX treatment, the absolute number of B-cells at baseline did not correlate to the ESSDAI. Furthermore, the focus score of the salivary glands did not correlate to the ESSDAI. However, Risselada et al. showed a significant correlation at baseline between the focus score and the cumulative ESSDAI in labial salivary glands of 174 pSS patients ($p=0.166-0.284$, $p\leq 0.04$).³⁹ This discrepancy could be ascribed to the fact that the study by Risselada et al. was retrospective, where ESSDAI was assessed at any time point during disease (not necessarily at diagnosis and biopsy), that 21% of patients used immunomodulating medication at the time of the biopsy and correlations were considered to be significant even if p was as low as $0.166-0.284$. Moreover, the size of the focus (as we assessed by CD45 staining) is probably more relevant than the absolute number of present foci in the salivary gland tissue.

In conclusion, we demonstrated that in parotid gland tissue of pSS patients:

1. RTX treatment leads to major reduction of B-cells, and a significant reduction in the number of GCs and LEL. This reduction in the LEL may be the consequence of a major decrease of local B-cell infiltration and may result in structural regeneration of the glands, especially the striated ducts.
2. The baseline number of CD20⁺B-cells/mm² of parenchyma may serve as a prognostic biomarker to predict response to RTX treatment. As a result, baseline histopathological characteristics of a parotid biopsy may strongly contribute to a more personalized treatment approach to pSS patients.

7a

ACKNOWLEDGEMENTS

Contributors: The authors would like to thank Mr. Klaas Sjoelma, UMCG Microscopy and Imaging Center (UMIC), University Medical Center Groningen, for his assistance during the immunohistochemical analysis of specimens with HistoQuest software and Dr Suzanne Arends, Department of Rheumatology and Clinical Immunology, University Medical Center Groningen, for critical reading of the manuscript.

Funding: Supported by unconditional grants of Roche (Woerden, the Netherlands) and the Jan-Kornelis de Cock foundation (Groningen, the Netherlands).

REFERENCES

1. Qin B, Wang J, Yang Z, et al. Epidemiology of primary Sjögren's syndrome: a systematic review and meta-analysis. *Ann Rheum Dis* 2015;74:1983-89.
2. Christodoulou MI, Kapsogeorgou EK, Moutsopoulos HM. Characteristics of the minor salivary gland infiltrates in Sjögren's syndrome. *J Autoimmun* 2010;34:400-07.
3. Kroese FG, Abdulahad WH, Haacke E, et al. B-cell hyperactivity in primary Sjögren's syndrome. *Expert Rev Clin Immunol* 2014;10:483-99.
4. Nishishinya MB, Pereda CA, Muñoz-Fernández S, et al. Identification of lymphoma predictors in patients with primary Sjögren's syndrome: a systematic literature review and meta-analysis. *Rheumatol Int* 2015;35:17-26.
5. Sutcliffe N, Inanc M, Speight P, et al. Predictors of lymphoma development in primary Sjögren's syndrome. *Semin Arthritis Rheum* 1998;28:80-87.
6. Theander E, Henriksson G, Ljungberg O, et al. Lymphoma and other malignancies in primary Sjögren's syndrome: a cohort study on cancer incidence and lymphoma predictors. *Ann Rheum Dis* 2006;65:796-803.
7. Ekström SK, Vajdic CM, Falster M, et al. Autoimmune disorders and risk of non- Hodgkin lymphoma subtypes: a pooled analysis within the InterLymph Consortium. *Blood* 2008;111:4029-38.
8. Pijpe J, van Imhoff GW, Spijkervet FKL, et al. Rituximab treatment in patients with primary Sjögren's syndrome: an open-label phase II study. *Arthritis Rheum* 2005;52:2740-50.
9. Pijpe J, van Imhoff GW, Vissink A, et al. Changes in salivary gland immunohistology and function after rituximab monotherapy in a patient with Sjögren's syndrome and associated MALT lymphoma. *Ann Rheum Dis* 2005;64:958-60.
10. Devauchelle-Pensec V, Pennec Y, Morvan J, et al. Improvement of Sjögren's syndrome after two infusions of rituximab (anti-CD20). *Arthritis Rheum* 2007;57:310-17.
11. Seror R, Sordet C, Guillevin L, et al. Tolerance and efficacy of rituximab and changes in serum B cell biomarkers in patients with systemic complications of primary Sjögren's syndrome. *Ann Rheum Dis* 2007;66:351-57.
12. Dass S, Bowman SJ, Vital EM, et al. Reduction of fatigue in Sjögren syndrome with rituximab: results of a randomised, double-blind, placebo-controlled pilot study. *Ann Rheum Dis* 2008;67:1541-44.
13. Meijer JM, Meiners PM, Slater JJRH, et al. Health-related quality of life, employment and disability in patients with Sjögren's syndrome. *Rheumatology* 2009;48:1077-82.
14. Meijer JM, Meiners PM, Vissink A, et al. Effectiveness of rituximab treatment in primary Sjögren's syndrome a randomized, double-blind, placebo-controlled trial. *Arthritis Rheum* 2010;62:960-68.
15. Meiners PM, Arends S, Brouwer E, et al. Responsiveness of disease activity indices ESSPRI and ESSDAI in patients with primary Sjögren's syndrome treated with rituximab. *Ann Rheum Dis* 2012;71:1297-1302.
16. Moerman RV, Arends S, Meiners PM, et al. EULAR Sjögren's Syndrome Disease Activity Index (ESSDAI) is sensitive to show efficacy of rituximab treatment in a randomised controlled trial. *Ann Rheum Dis* 2014;73:472-74.
17. Devauchelle-Pensec V, Mariette X, Jousse-Joulin S, et al. Treatment of primary Sjögren syndrome with rituximab: a randomized trial. *Ann Intern Med* 2014;160:233-42.
18. Cornec D, Devauchelle-Pensec V, Mariette X, et al. Development of the Sjögren's Syndrome Responder Index, a data-driven composite endpoint for assessing treatment efficacy. *Rheumatology (Oxford)* 2015;54:1699-1708.
19. Brown S, Navarro Coy N, Pitzalis C, et al. The TRACTISS protocol: a randomised double blind placebo controlled clinical trial of anti-B-cell therapy in patients with primary Sjögren's Syndrome. *BMC Musculoskelet Disord* 2014;15:21.

20. Pijpe J, Meijer JM, Bootsma H, et al. Clinical and histologic evidence of salivary gland restoration supports the efficacy of rituximab treatment in Sjögren's syndrome. *Arthritis Rheum* 2009;60:3251-56.
21. Vitali C, Bombardieri S, Jonsson R, et al. Classification criteria for Sjögren's syndrome: a revised version of the European criteria proposed by the American-European Consensus Group. *Ann Rheum Dis* 2002;61:554-58.
22. Delli K, Vissink A, Spijkervet FK. Salivary gland biopsy for Sjögren's syndrome. *Oral Maxillofac Surg Clin North Am* 2014;26:23-33.
23. Seror R, Ravaud P, Bowman SJ, et al. EULAR Sjögren's syndrome disease activity index: development of a consensus systemic disease activity index for primary Sjögren's syndrome. *Ann Rheum Dis* 2010;69:1103-09.
24. Seror R, Theander E, Brun JG, et al. Validation of EULAR primary Sjögren's syndrome disease activity (ESSDAI) and patient indexes (ESSPRI). *Ann Rheum Dis* 2015;74:859-66.
25. Seror R, Bootsma H, Saraux A, et al. Defining disease activity states and clinically meaningful improvement in primary Sjögren's syndrome with EULAR primary Sjögren's syndrome disease activity (ESSDAI) and patient-reported indexes (ESSPRI). *Ann Rheum Dis* 2016;75:382-89.
26. Abdulahad WH, Meijer JM, Kroese FG, et al. B cell reconstitution and T helper cell balance after rituximab treatment of active primary Sjögren's syndrome: a double-blind, placebo-controlled study. *Arthritis Rheum* 2011;63:1116-23.
27. Ring T, Kallenbach M, Praetorius J, et al. Successful treatment of a patient with primary Sjögren's syndrome with rituximab. *Clin Rheumatol* 2006;25:891-94.
28. Hamza N, Bootsma H, Yuvaraj S, et al. Persistence of immunoglobulin-producing cells in parotid salivary glands of patients with primary Sjögren's syndrome after B cell depletion therapy. *Ann Rheum Dis* 2012;71:1881-87.
29. Kavanaugh A, Rosengren S, Lee SJ, et al. Assessment of rituximab's immunomodulatory synovial effects (ARISE trial). 1: clinical and synovial biomarker results. *Ann Rheum Dis* 2008;67:402-08.
30. Vos K, Thurlings RM, Wijbrandts CA, et al. Early effects of rituximab on the synovial cell infiltrate in patients with rheumatoid arthritis. *Arthritis Rheum* 2007;56:772-78.
31. Thurlings RM, Vos K, Wijbrandts CA, et al. Synovial tissue response to rituximab: mechanism of action and identification of biomarkers of response. *Ann Rheum Dis* 2008;67:917-25.
32. Risselada AP, Looije MF, Kruize AA, et al. The role of ectopic germinal centers in the immunopathology of primary Sjögren's syndrome: a systematic review. *Semin Arthritis Rheum*. 2013;42:368-76.
33. Gong Q, Ou Q, Ye S, et al. Importance of cellular microenvironment and circulatory dynamics in B-cell immunotherapy. *J Immunol* 2005;174:817-26.
34. Jin L, Yu D, Li X, et al. CD4+CXCR5+ follicular helper T cells in salivary gland promote B cells maturation in patients with primary Sjögren's syndrome. *Int J Clin Exp Pathol* 2014;15:1988-96.
35. Ihrler S, Blasenbren-Vogt S, Sendelhofert A, et al. Regeneration in chronic sialadenitis: an analysis of proliferation and apoptosis based on double immunohistochemical labelling. *Virchows Arch* 2004;444:356-61.
36. Pollard RP, Abdulahad WH, Bootsma H, et al. Predominantly proinflammatory cytokines decrease after B cell depletion therapy in patients with primary Sjögren's syndrome. *Ann Rheum Dis* 2013;72:2048-50.
37. Cornec D, Jamin C, Pers JO. Sjögren's Syndrome: Where do we stand and where shall we go? *J Autoimmun* 2014;51:109-14.
38. FDA. Accessed on 21.7.2015. Available at: <http://www.fda.gov/scienceresearch/specialtopics/personalizedmedicine/default.htm>
39. Risselada AP, Kruize AA, Goldschmeding R, et al. The prognostic value of routinely performed minor salivary gland assessments in primary Sjögren's syndrome. *Ann Rheum Dis* 2014;73:1537-40.

SUPPLEMENTARY MATERIALS

Supplementary Table 1: Number (%) of patients having any degree of activity per ESSDAI domain (score at least 1) before and after RTX therapy, stratified for clinical responders and non-responders.

	Responders		Non-responders	
	Before	After	Before	After
Cutaneous	1 (9)	0 (0)	0 (0)	0 (0)
Pulmonary	5 (45)	0 (0)	0 (0)	0 (0)
Renal	0 (0)	0 (0)	0 (0)	0 (0)
Articular	8 (73)	2 (18)	5 (100)	5 (100)
Muscular	0 (0)	0 (0)	0 (0)	0 (0)
Peripheral nervus system	0 (0)	0 (0)	0 (0)	0 (0)
Central nervus sytem	0 (0)	0 (0)	0 (0)	0 (0)
Hematological	6 (55)	5 (45)	2 (40)	2 (40)
Glandular	9 (82)	4 (36)	4 (80)	4 (80)
Constitutional	1 (9)	0 (0)	0 (0)	0 (0)
Lymphadenopathy	0 (0)	0 (0)	0 (0)	0 (0)
Biological	11 (100)	8 (73)	2 (40)	2 (40)





CHAPTER 7b

In primary Sjögren's syndrome high absolute numbers and proportions of B-cells in parotid glands predict responsiveness to rituximab as defined by ESSDAI, but not by SSRI.

Konstantina Delli¹
Erlin A Haacke^{2,3}
Frans GM Kroese²
Rodney P Pollard¹
Stephan Ihrler⁴

Bert van der Vegt³
Arjan Vissink¹
Hendrika Bootsma²
Frederik KL Spijkervet¹

Department of ¹Oral and Maxillofacial Surgery, ²Rheumatology & Clinical Immunology, ³Pathology and Medical Biology, University of Groningen, University Medical Center Groningen, the Netherlands and ⁴Laboratory for Dermatohistology & Oral Pathology, Munich, Germany

Modified version of: Ann Rheum Dis. 2016 Jun;75(6):e34

With great interest we have read the article by Cornec et al¹ regarding our paper 'Towards personalised treatment in primary Sjögren's syndrome (pSS): baseline parotid histopathology predicts responsiveness to rituximab treatment'.² In essence we showed in our paper that absolute numbers of CD20⁺ cells/mm² of parenchyma of parotid gland tissue are predictive for the responsiveness of patients with primary Sjögren's syndrome (pSS) to rituximab (RTX) treatment. Cornec et al. argue that there is a discrepancy in outcomes presented in their study and our study,¹ as they observed that a high proportion of minor salivary gland B cells predict absence of a clinical response to RTX.³ As we will show and explain here, there is no inconsistency between the two studies and most of the apparent discrepancy is likely the result of differences in how the tissues are analyzed and how the disease activity is established.

Absolute numbers versus proportions of B cells and technique applied

A major difference in the two studies is how B cells are assessed in tissue sections of salivary gland biopsies of pSS patients before (and after) RTX treatment. We measured absolute numbers of CD20⁺ B cells/mm² of parenchyma, while Cornec et al. assessed the proportion of B cells.^{1,3} Obviously, even when there is a change in absolute numbers of B cells in the tissue, the B/T cell ratio still can remain the same. Thus, although higher numbers of B cells, do not need to be reflected per se in higher proportions of B cells, we also found in our study that patients with higher absolute numbers of B cells in the glandular tissue, had a higher B/B+T cell ratio. Furthermore, responders to RTX, as defined by a decrease in European League Against Rheumatism EULAR Sjögren's Syndrome Disease Activity Index (ESSDAI) score of ≥ 3 ($\Delta\text{ESSDAI} \geq 3$) at 12 weeks after treatment compared to baseline,⁴ had a higher B/B+T cell ratio compared to non-responders (Figure 1).

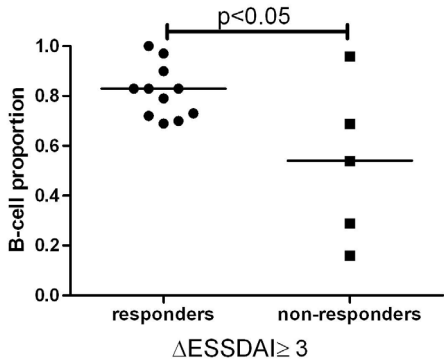


Figure 1: Proportions of baseline CD20+ cells in clinical responders (n=11) and non-responders (n=5) as defined by ESSDAI, $p < 0.05$. Horizontal lines indicate median values.

Nevertheless, there are some technical differences between the two studies that warrant some attention. We counted the absolute number of cells with HistoQuest software (version 3.5.3.0171, Tissuegnostics, Vienna, Austria), a well-known and widely used image analysis software package within pathology. Since parotid gland biopsies include areas of fat and fibrous tissue and intra parenchymal lymph nodes, we excluded these areas manually from the analysis, in order to increase the accuracy of the data. We would like to emphasize that, as stated in the section on 'Immunohistochemical analysis' in the materials and methods of our article,² the whole slide (except from fat and fibrous tissue) was evaluated and areas of interest were not electively chosen, as implied by Cornec et al.¹ The methodology used by Cornec et al. is based on digital pixel counting procedure developed by Costa et al.^{1,3,5} We have some concerns about this method. First, with the method of Costa et al. extra-glandular areas are not excluded from the tissue specimen studied,⁵ which has the risk to include in the counting infiltrating cells located in areas of non-interest, e.g., intraparenchymal fat tissue, fibrous tissue, perineural tissue, etc. Second, although the number of pixels is reported to correlate to the manually counted cells,⁵ the exact number of pixels corresponding to one cell remains unknown. Moreover, although the B-cell proportions assessed with the method of Costa et al. correlate moderately to focus scores,⁵ the focus score does not give an indication about the severity of inflammation, as discussed in our paper.² As a consequence, when the area covered by a single focus at baseline is rather large, a clinically relevant decrease in the inflamed area is not necessary reflected by a decrease in focus score. Apparently the HistoQuest method of counting the absolute number of cells is more precise in these aspects. Thus, it would be interesting to know whether the results reported by Cornec et al. change if biopsies would have been analyzed with the HistoQuest software approach.³

ESSDAI versus SSRI

Another factor that contributes significantly to the apparent difference between the two studies concerns the way disease activity has been defined. Cornec et al. pose that the discrepancy in outcomes can partially be attributed to ineffectiveness of RTX in improving systemic involvement as measured by ESSDAI.¹ This prompted them to develop and use the Sjögren's Syndrome Response Index (SSRI), an index reflecting mainly the objective and subjective sicca symptoms.⁶ When we applied the SSRI to classify patients as responder or non-responder, we were unable to detect any difference in our data in baseline CD20⁺ B-cells/mm² parenchyma between responders and non-responders (Figure 2). Importantly, the agreement between ESSDAI and SSRI in defining responders in our study was rather poor ($\kappa=0.25$, percentage of agreement 64%; data not shown). Based on these findings we conclude that it is evident that ESSDAI and SSRI measure different outcomes; the ESSDAI focuses on systemic disease activity and the SSRI mainly on sicca related complaints. In this respect it is also worth mentioning that in our placebo treated patients, SSRI characterized

40% of the patients as responders, while ESSDAI only 11%. ESSDAI has been proven to be sensitive to measure the change in disease activity after therapeutic interventions and also showed that RTX was effective in our double-blind placebo-controlled RTX trial.^{4,7-10} Thus, further validation is necessary for the SSRI.

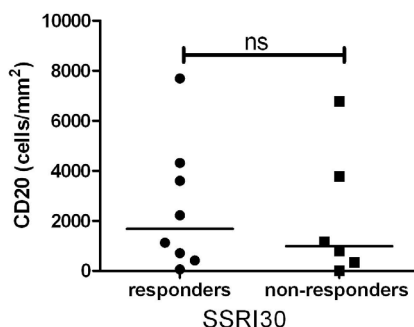


Figure 2: Numbers of baseline CD20+ cells/mm² in clinical responders (n=8) and non-responders (n=6) as defined by SSRI. Horizontal lines indicate median values, ns: non-significant.

Differences in general features

In addition to these two main aspects that result in the apparent discrepancies between the two studies, there are also some other differences that may influence differences in outcomes.

Baseline ESSDAI: Although the baseline ESSDAI scores were rather similar between the two studies (8 in our study and 10 in the TEARS study) only in our study the ESSDAI was prospectively evaluated.^{11,12} In the TEARS study the ESSDAI was retrospectively evaluated.

Baseline salivary gland positivity: Another major difference between the two studies is the positivity of salivary gland biopsy of the included patients; all patients in our study had a positive parotid gland biopsy at baseline, while only 64% of the patients included in the study by Cornec et al. had a positive minor salivary gland biopsy.¹ When excluding patients with a negative minor salivary gland biopsy from the study by Cornec et al., the median proportion of B-cells in responders would have been probably higher than in non-responders, which is in agreement with the conclusion of our study.

Parotid versus minor salivary gland biopsy: The different histopathological characteristics observed in parotid and minor salivary gland biopsies complicate the comparison as, e.g., the B/T-cell ratio differs greatly. Minor salivary glands of healthy controls may have a physiological infiltrate that consists mainly of T-lymphocytes (and plasma cells), while parotid salivary gland tissue of healthy controls shows rarely a lymphocytic infiltrate. Although those differences have been shown by Pijpe et al.,¹³ there is still a need for larger studies focusing on the inherent differences in the histopathological characteristics of parotid and minor salivary gland tissue in both pSS patients and healthy controls.

Salivary gland ultrasound

Like Cornec et al., we also feel that ultrasound has merit in the diagnosis and assessment of the disease activity of pSS.^{1,14,15} However, before making salivary gland ultrasound a standard in pSS diagnostics, disease monitoring and treatment evaluation, there are several questions that need to be answered first, i.e. the reliability of ultrasound in the evaluation of changes that occur in the major salivary glands of pSS patients, and the validity of ultrasound to detect the histopathologic changes occurring in the parotid tissue of patients (suspected) with pSS in particular (direct comparison of ultrasonographic and histopathologic features).

Conclusion

From the abovementioned, it may be concluded that our study and the study of Cornec et al. differ in some respect,^{2,3} but do not present contradicting results. Most likely differences in assessment of patients' responsiveness to RTX treatment by using different methods and techniques lead to different results and apparent differences (Table 1). Probably, by combining theirs and our analyses we might even be able to more efficiently select patients at baseline who probably will benefit from RTX treatment.

Table 1 : Comparison of two studies

STUDY	Cornec et al., 2015	Delli et al., 2015
Outcome	Proportion of B cells	Absolute number of CD20 ⁺ B-cells/mm ² parenchyma
Software	Digital pixel counting software, developed by the same team ⁵	HistoQuest software, version 3.5.3.0171, Tissuegnostics, Vienna, Austria
Tool for measuring response to RTX	SSRI ⁶	ESSDAI ⁴
Salivary gland	Minor salivary glands	Parotid gland
General features	<ul style="list-style-type: none"> • Baseline ESSDAI:10 • Median age: 50.4 to 54.8 (± 9.5 & ±13.8) • Baseline salivary gland biopsy positivity: 64% • Baseline anti-SSA positivity: 80% 	<ul style="list-style-type: none"> • Baseline ESSDAI: 8 • Median age: 43 (±11 years) • Baseline salivary gland biopsy positivity: 100% • Baseline anti-SSA positivity: 100%

REFERENCES

1. Cornec D, Costa S, Devauchelle-Pensec V, et al. Do high numbers of salivary-gland infiltrating B cells predict better or worse outcomes after rituximab in patients with primary Sjögren's syndrome? *Ann Rheum Dis* 2016;75:e33.
2. Delli K, Haacke EA, Kroese FG, et al. Towards personalised treatment in primary Sjögren's syndrome: baseline parotid histopathology predicts responsiveness to rituximab treatment. *Ann Rheum Dis* 2016;75:1933-38.
3. Cornec D, Costa S, Devauchelle-Pensec V, et al. Blood and salivary-gland BAFF-driven B-cell hyperactivity is associated to rituximab inefficacy in primary Sjögren's syndrome. *J Autoimmun* 2016;67:102-10.
4. Seror R, Bootsma H, Saraux A, et al. Defining disease activity states and clinically meaningful improvement in primary Sjögren's syndrome with EULAR primary Sjögren's syndrome disease activity (ESSDAI) and patient-reported indexes (ESSPRI). *Ann Rheum Dis* 2016;75(2):382-9.
5. Costa S, Schutz S, Cornec D, et al. B-cell and T-cell quantification in minor salivary glands in primary Sjögren's syndrome: development and validation of a pixel-based digital procedure. *Arthritis Res Ther* 2016;18:21.
6. Cornec D, Devauchelle-Pensec V, Mariette X, et al. Development of the Sjögren's Syndrome Responder Index, a data-driven composite endpoint for assessing treatment efficacy. *Rheumatology (Oxford)* 2015;54:1699-708.
7. Meiners PM, Arends S, Brouwer E, et al. Responsiveness of disease activity indices ESSPRI and ESSDAI in patients with primary Sjögren's syndrome treated with rituximab. *Ann Rheum Dis* 2012;71:1297-02.
8. Meiners PM, Vissink A, Kroese FG, et al. Abatacept treatment reduces disease activity in early primary Sjögren's syndrome (open-label proof of concept ASAP study). *Ann Rheum Dis* 2014;73:1393-6.
9. Meiners PM, Arends S, Meijer JM, et al. Efficacy of retreatment with rituximab in patients with primary Sjögren's syndrome. *Clin Exp Rheumatol* 2015;33:443-4.
10. Moerman RV, Arends S, Meiners PM, et al. EULAR Sjögren's Syndrome Disease Activity Index (ESSDAI) is sensitive to show efficacy of rituximab treatment in a randomised controlled trial. *Ann Rheum Dis* 2014;73:472-4.
11. Meijer JM, Meiners PM, Vissink A, et al. Effectiveness of rituximab treatment in primary Sjögren's syndrome: a randomized, double-blind, placebo-controlled trial. *Arthritis Rheum* 2010;62:960-8.
12. Devauchelle-Pensec V, Mariette X, Jousse-Joulin S, et al. Treatment of Primary Sjögren Syndrome With Rituximab. A Randomized Trial. *Ann Intern Med* 2014;160:233-42.
13. Pijpe J, Kalk WWI, Wal JE van der, et al. Parotid gland biopsy compared with labial biopsy in the diagnosis of patients with primary Sjögren's syndrome. *Rheumatology* 2007;46:335-41.
14. Delli K, Dijkstra PU, Stel AJ, et al. Diagnostic properties of ultrasound of major salivary glands in Sjögren's syndrome: a meta-analysis. *Oral Dis* 2015;21:792-800.
15. Jousse-Joulin S, Milic V, Jonsson MV, et al. Is salivary gland ultrasonography a useful tool in Sjögren's syndrome? A systematic review. *Rheumatology (Oxford)* 2016;55:789-00.



CHAPTER 8

Abatacept treatment of patients with primary Sjögren's syndrome results in a decrease of germinal centres in salivary gland tissue

Erlin A Haacke^{1,2}
Bert van der Vegt²
Petra M Meiners³
Arjan Vissink³

Fred KL Spijkervet³
Hendrika Bootsma¹
Frans GM Kroese¹

Department of ¹Rheumatology & Clinical Immunology, ²Pathology and Medical Biology, ³Oral and Maxillofacial Surgery, University of Groningen, University Medical Center Groningen, the Netherlands

Modified version of: Clin Exp Rheumatol. 2017;35:317-320

ABSTRACT

Objective: The aim of this study was to assess the histopathological changes in parotid gland tissue of primary Sjögren's syndrome (pSS) patients treated with abatacept.

Methods: In all 15 pSS patients included in the open-label Active Sjögren Abatacept Pilot (ASAP, 8 abatacept infusions) study parotid gland biopsies were taken before treatment and at 24 weeks of follow up. Biopsies were analysed for pSS-related histopathological features and placed in context of clinical responsiveness as assessed with EULAR Sjögren's syndrome disease activity index (ESSDAI).

Results: Abatacept treatment resulted in a decrease of germinal centres (GCs)/mm² ($p=0.173$). Number of GCs/mm² at baseline was associated with response in the glandular domain of ESSDAI (Spearman $p=0.644$, $p=0.009$). Abatacept treatment did not reduce focus score, lymphoepithelial lesions, area of lymphocytic infiltrate, amount of CD21⁺ networks of follicular dendritic cells, and numbers of CD3⁺ T-cells or CD20⁺ B-cells. Number of IgM plasma cells/mm² increased ($p=0.041$), while numbers of IgA and IgG plasma cells/mm² were unaffected during abatacept treatment.

Conclusion: Abatacept affects formation of GCs of pSS patients in parotid glands, which is dependent on co-stimulation of activated follicular-helper-T-cells. Herewith local formation of (autoreactive) memory B-cells is inhibited. Presence of GCs at baseline predicts responsiveness to abatacept in the ESSDAI glandular domain.

INTRODUCTION

Primary Sjögren's syndrome (pSS) is an autoimmune disease characterized by chronic inflammation of exocrine glands, histomorphologically seen as periductal infiltrates predominantly consisting of T- and B-cells. Lymphocytic infiltration of the epithelium of striated ducts leads to formation of lymphoepithelial lesions (LELs) which are more pronounced in parotid than in labial glands.¹ Besides periductal infiltrates, there is a plasmacytosis with an increased number of IgG expressing plasma cells.² A subset of pSS patients develop germinal centers (GCs) in ectopic lymphoid infiltrates of the glands. Presence of GCs is associated with more active disease and is considered to be a predictor for malignant lymphoma development.³⁻⁵

There are no approved therapeutic interventions for pSS yet, but promising results with biological disease modifying anti-rheumatic drugs, e.g. abatacept, are reported. Abatacept was shown to be effective and safe in open-label studies in pSS.^{6,7} This fully human biological binds to CD80/CD86 on antigen presenting cells and hereby blocks the CD28-mediated co-stimulation of CD4⁺ T-cells.⁸ In pSS patients, systemic disease activity is assessed with the EULAR Sjögren's Syndrome Disease Activity (ESSDAI) score. Abatacept treatment resulted in a decrease of ESSDAI with most prominent beneficial clinical effects in the glandular, articular, constitutional and biological domains. Saliva production remained stable during treatment.⁶ It is not clear yet what the effect of abatacept treatment is on the inflammatory process in salivary glands, in the context of responsiveness to treatment. Therefore, the aim of this study was to assess the histopathological changes in parotid gland tissue of early and active pSS patients treated with abatacept. This evaluation was performed in a standardized fashion that was shown before to identify biomarkers useful for personalized medicine.⁹

MATERIALS AND METHODS

Patients

In all pSS patients (for characteristics see supplementary Table 1) included in the open-label Active Sjögren Abatacept Pilot (ASAP) study (n=15),⁶ a parotid gland biopsy was taken within 12 months before and 24 weeks after the initiation of abatacept treatment. Patients received abatacept infusions (≈10 mg/kg) on days 1, 15, 29 and every 4 weeks thereafter (Bristol Myers Squibb, France). ESSDAI scores were used for rating disease activity.¹⁰

(Immuno-)histological staining and evaluation of parotid gland biopsies

(Immuno-)histological processing and staining was performed as previously described (see also Figure 1).⁹ Primary antibodies are listed in supplementary Table 2. Staining was performed on serial sections, except for CD21. For practical reasons, staining for CD21 was performed on

sections from the same paraffin blocks, but sectioned in a separate session. Hematoxylin and eosin (HE) stained sections were used to assess FS and number of GCs/mm². Dual staining with CD20 and CK8/18 was used to determine number of LELs/mm². Severity of LELs was scored as previously described.⁹ Evaluation was performed independently and blinded (B.V., E.H.) resolving discrepancies by consensus. Relative area of CD45⁺ lymphocytic infiltrate and CD21⁺ follicular dendritic cell (FDC) networks was measured using ImageScope v12.0 (Aperio Technologies, USA). Numbers of CD20, CD3, IgA, IgG, IgM positive cells were assessed using HistoQuest v3.5.3.0171 (Tissuegnostics, Austria).⁹ The parenchyma of the whole biopsy was examined, excluding intraparenchymal connective- and fat tissue.

Statistical analysis

Wilcoxon Signed Rank test was used to test differences between groups. Spearman correlation coefficient was calculated for correlations (IBM SPSS Statistics V.22).

RESULTS

Focus score, relative area of CD45⁺ lymphocytic infiltrate, number of CD20⁺ B-cells/mm² and CD3⁺ T-cells/mm², CD21⁺ FDC networks and total plasma cell population, were all unaffected by abatacept (Figure 1, Table 1). Also structure and regeneration of the ductal epithelium, as reflected by number and severity of LELs, was not improved (supplementary Figure 1). In contrast to these findings, number of GCs/mm² was reduced by abatacept treatment. At baseline, GCs were present in parotid gland biopsies of five patients and GCs were absent in all these patients after treatment (Figure 1I). In one patient GCs were absent at baseline, but detected after abatacept treatment. This patient was the only patient in whom ESSDAI had increased after treatment and thus can be considered as non-responder. In all other patients ESSDAI had decreased upon treatment and in these patients the decline in GCs/mm² was statistically significant ($p=0.043$). The ESSDAI glandular domain was higher in patients with GC activity than patients without GC activity at baseline (1.2 vs 0.6). The number of GCs/mm² at baseline was associated with improvement in the ESSDAI glandular domain (Spearman $\rho=0.644$, $p=0.009$), but not with other ESSDAI domains. Numbers of IgA and IgG plasma cells/mm² remained stable, while numbers of IgM plasma cells/mm² increased ($p=0.041$, Figure 1J). However, relative proportion of IgM plasma cells remained still low after treatment (4.8%).

Table 1: Histopathologic results of parotid gland tissue evaluation in pSS patients (n=15) treated with abatacept.

Variable	Baseline	Abatacept wk 24	P-value (Wilcoxon Signed Rank)
Histopathological pSS parameters			
Area of parotid parenchyma	5.3 (4.3-8.1)	6.5 (4.9-8.9)	0.820
Focus score (number of foci of ≥ 50 lymphocytes/4 mm ²)	3.1 (1.5-5.0)	3.2 (0.9-4.1)	0.173
Germinal centers (#/mm ²)	0.06 (0.13)*	0.009 (0.04)*	0.173
Lymphoepithelial lesions (#/mm ²)	0.24 (0-0.56)	0.27 (0-0.61)	0.583
Area of CD21 ⁺ FDC networks	0.063 (0.006-0.539)	0.030 (0.004-0.244)	0.334
Area of CD45 ⁺ lymphocytic infiltrate	9.0 (5.8-38.0)	15.3 (10.4-33.1)	0.649
B-cells (#/mm ²)	1187 (687-3128)	752 (268-3677)	0.394
T-cells (#/mm ²)	1109 (892-2510)	1119 (425-2971)	0.427
Total plasma cells (#/mm ²)	1271 (566-1939)	2161 (1177-2887)	0.125

Values are presented as median (IQR) unless otherwise specified. *Average (SD). P value <0.05 was considered statistically significant.

DISCUSSION

We assessed histopathological changes in parotid gland tissue in relation to abatacept treatment in early and active pSS patients. These changes were evaluated in a standardized fashion, that was previously shown to be able to identify biomarkers that predict responsiveness to rituximab treatment.⁹ Importantly, we observed that GCs disappeared completely in parotid gland tissue of patients with GCs at baseline (33%). Furthermore, number of IgM producing plasma cells increased, while other histopathological parameters measured did not change upon abatacept treatment. These observations are in line with our previous findings that during abatacept therapy secretion of stimulated whole saliva did not deteriorate.⁶

Also Adler et al.⁷ observed that foci/mm², CD3⁺ T-cells, CD20⁺ B-cells and total number of plasma cells in labial (rather than parotid) glands were unaffected by abatacept. However, in their study, two major elements of pSS histopathology, namely GCs and LELs, were not analyzed. We demonstrated for the first time that abatacept abrogated ectopic, histomorphologically-defined, GCs in a human autoimmune disease. Other studies had shown in a murine model for rheumatoid arthritis that the proportion of flow-cytometry-defined (GL7⁺Fas⁺) GC B-cells was reduced by abatacept treatment in lymph nodes draining affected joints.¹¹ Abatacept did not decrease the amount of CD21⁺ FDC networks (supplementary Figure 2). Although these networks are a prerequisite for GC formation in the foci, presence of these networks does not imply per se that GCs are also present.¹² Since abatacept does not affect the FDC networks, this observations

suggests that absence of GCs cannot be attributed to a disorganized microenvironment. For formation and perpetuation of GCs, GC B-cells require co-stimulatory signals from T-follicular-helper-cells (T_{fh} -cells) for their development and maintenance. T_{fh} -cells are also involved in pSS pathogenesis.¹³ T_{fh} -cells are elevated in blood from pSS patients and are also present in glandular tissue.¹⁴ In pSS patients T_{fh} -cells appear to be in a hyperactivated state as reflected by elevated ICOS-levels on circulating T_{fh} -cells [Verstappen, unpublished observations]. We have shown that abatacept selectively reduces the (elevated) proportion and number of circulating T_{fh} -cells in the peripheral blood of pSS patients to levels of healthy controls, and also normalizes the ICOS-levels [Verstappen, unpublished observations]. A reduction in T_{fh} -cell activity after abatacept treatment might lead to decreased GC activity in inflamed salivary glands. Presence of GCs in labial glands is associated with higher FS and percentages of patients positive for autoantibodies (RF, anti-SSA/SSB).^{3,4} Whether patients with GCs also exhibit higher systemic disease as reflected by higher ESSDAI remains to be explored. In our (small) group of pSS patients there was no difference in total ESSDAI scores between patients with and without GCs in their biopsy, but there was a difference detectable considering the ESSDAI glandular domain.

The characteristic epitheliotropic autoimmune inflammation in pSS is histologically seen as LELs of striated ducts. LELs are composed of proliferative metaplastic epithelial cells in association with intra-epithelial lymphocytes and are more pronounced in parotid than in labial glands¹, making analysis of these structures more easy and reliable in parotid tissue. We have shown here that numbers and severity of LELs are not influenced by abatacept. This finding indicates that the cross-talk between epithelial cells and intra-epithelial lymphocytes, thought to be responsible for formation and maintenance of LELs⁹, is independent of CD28-mediated co-stimulation.

Our data showed that numbers of IgG plasma cells/mm² remained stable in parotid gland tissue after abatacept treatment. Part of these IgG plasma cells comprise autoantibody producing cells.¹⁵ These findings support the notion that (autoreactive) plasma cells located at inflamed sites are long-lived cells that are not replaced by newly generated plasma cells in a T_{fh} -cell dependent fashion. Indeed our previous B-cell depletion studies showed that in parotid glands IgG-producing B-cell clones can persist for at least one year.¹⁶ A small proportion of long-lived plasma cells may express CD28 which is needed for their maintenance and survival.¹⁷ CD28 expressing plasma cells have, however, not yet been detected in parotid glands of pSS patients (unpublished data). Despite the fact that numbers of IgG (and IgA) producing plasma cells remained constant in parotid glands, serum IgG levels and autoantibody (anti-SSA/SSB) titers decreased during treatment.⁶ We suggest that this decrease is due to loss of (autoreactive) IgG producing plasma cells located elsewhere in the body. These cells are either CD28-expressing plasma cells that require CD28 stimulation for their survival or require T-cell dependent and CD28-mediated co-stimulation for their generation. In contrast to isotype switched plasma

cells, there was an increase in numbers of IgM plasma cells/mm² in parotid tissue. IgM plasma cells are generally considered to be short-lived and their formation can partially occur in a T-cell independent fashion. The increase in IgM plasma cell numbers during abatacept treatment is in line with this T-cell independency. Why their numbers increase is unclear. We speculate that blocking T-cell help, drives the B-cells towards differentiation of unswitched IgM plasma cells, at the expense of IgG or IgA plasma cells.

To conclude, abatacept treatment results in a reduction of GCs in parotid gland tissue of pSS patients, probably due to inhibition of local T-cell dependent B-cell activation. Likely, the selective decrease in (activated) T_H-cells plays an important role in reduction of GCs.

ACKNOWLEDGEMENTS

Funding: This study was financially supported by Bristol Myers Squibb, Rueil Malmaison, France, who also supplied study medication. There was no involvement of this funding source in study design, data collection, analysis and interpretation and writing of this report.

Patient consent: Obtained.

Ethics approval: Institutional Review Board of the University Medical Center Groningen (METc 2009.371).

REFERENCES

1. Pijpe J, Kalk WW, van der Wal JE, et al. Parotid gland biopsy compared with labial biopsy in the diagnosis of patients with primary Sjögren's syndrome. *Rheumatology (Oxford)* 2007;46:335–41.
2. Bodeutsch C, Kater L, Kruize AA. Quantitative immunohistologic criteria are superior to the lymphocytic focus score criterion for the diagnosis of Sjögren's syndrome. *Arthritis Rheum* 1992;35:1075–87.
3. Risselada AP, Looije MF, Kruize AA, et al. The role of ectopic germinal centers in the immunopathology of primary Sjögren's syndrome: a systematic review. *Semin Arthritis Rheum* 2013;42:368–76.
4. Theander E, Vasaitis L, Baecklund E, et al. Lymphoid organisation in labial salivary gland biopsies is a possible predictor for the development of malignant lymphoma in primary Sjögren's syndrome. *Ann Rheum Dis* 2011;70:1363–68.
5. Ferro F, Vagelli R, Bruni C, et al. One year in review 2016: Sjögren syndrome. *Clin Exp Rheumatol* 2016;34:161–71.
6. Meiners PM, Vissink A, Kroese FGM, et al. Abatacept treatment reduces disease activity in early primary Sjögren's syndrome (open-label proof of concept ASAP study). *Ann Rheum Dis* 2014;73:1393–96.
7. Adler S, Korner M, Forger F, et al. Evaluation of histological, serological and clinical changes in response to abatacept treatment of primary Sjögren's syndrome: A pilot study. *Arthritis Care Res (Hoboken)* 2013;65:1862–68.
8. Moreland L, Bate G, Kirkpatrick P. Abatacept. *Nat Rev Drug Discov* 2006;5:185–86.
9. Delli K, Haacke EA, Kroese FGM, et al. Towards personalised treatment in primary Sjögren's syndrome: baseline parotid histopathology predicts responsiveness to rituximab treatment. *Ann Rheum Dis* 2016;75:33–38.
10. Seror R, Bootsma H, Saraux A, et al. Defining disease activity states and clinically meaningful improvement in primary Sjögren's syndrome with EULAR primary Sjögren's syndrome disease activity (ESSDAI) and patient-reported indexes (ESSPRI). *Ann Rheum Dis* 2016;75:382–89.
11. Platt AM, Gibson VB, Patakas A, et al. Abatacept limits breach of self-tolerance in a murine model of arthritis via effects on the generation of T follicular helper cells. *J Immunol* 2010;185:1558–67.
12. Jonsson MV, Skarstein K. Follicular dendritic cells confirm lymphoid organization in the minor salivary glands of primary Sjögren's syndrome. *J Oral Pathol Med* 2008;37:515–21.
13. Ueno H, Banchereau J, Vinuesa CG. Pathophysiology of T follicular helper cells in humans and mice. *Nat Immunol* 2015;16:142–52.
14. Gong Y-Z, Nititham J, Taylor K, et al. Differentiation of follicular helper T cells by salivary gland epithelial cells in primary Sjögren's syndrome. *J Autoimmun* 2014;51:57–66.
15. Szyszko EA, Aqrabi LA, Jonsson R, et al. Non-proliferating plasma cells detected in the salivary glands and bone marrow of autoimmune NOD.B10.H2b mice, a model for primary Sjögren's syndrome. *Autoimmunity* 2016;49:41–49.
16. Hamza N, Bootsma H, Yuvaraj S, et al. Persistence of immunoglobulin-producing cells in parotid salivary glands of patients with primary Sjögren's syndrome after B cell depletion therapy. *Ann Rheum Dis* 2012;71:1881–87.
17. Rozanski CH, Utley A, Carlson LM, et al. CD28 Promotes Plasma Cell Survival, Sustained Antibody Responses, and BLIMP-1 Upregulation through Its Distal PYAP Proline Motif. *J Immunol* 2015;194:4717–28.

SUPPLEMENTARY MATERIALS

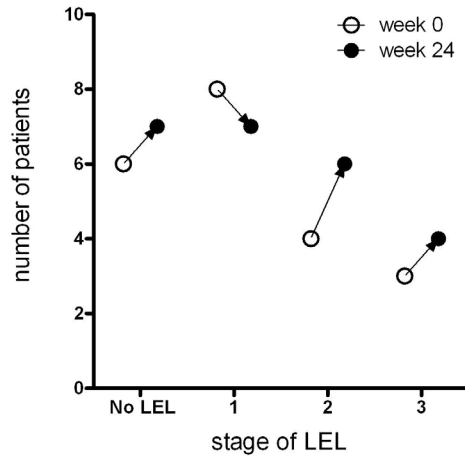
Supplementary Table 1: Patient characteristics and laboratory assessments at baseline in pSS patients (n=15) treated with abatacept.⁶

Variable	Baseline
Patient characteristics	
Age years, mean (SD)	43 (14)
Female gender, n(%)	12 (80)
Disease duration in months, median (IQR)	11 (7-36)
ESSDAI total, median (IQR)	11 (8-14)
ESSDAI glandular domain ≥1, n(%)	11(73) [#]
Laboratory assessments	
IgG (g/L), mean ±SD	21.5 ±7.3
RF (kIU/L), mean ±SD	89 ±94
SSA positive, n(%)	15 (100)
SSB positive, n(%)	12 (80)

Values are presented as median (IQR) unless otherwise specified.

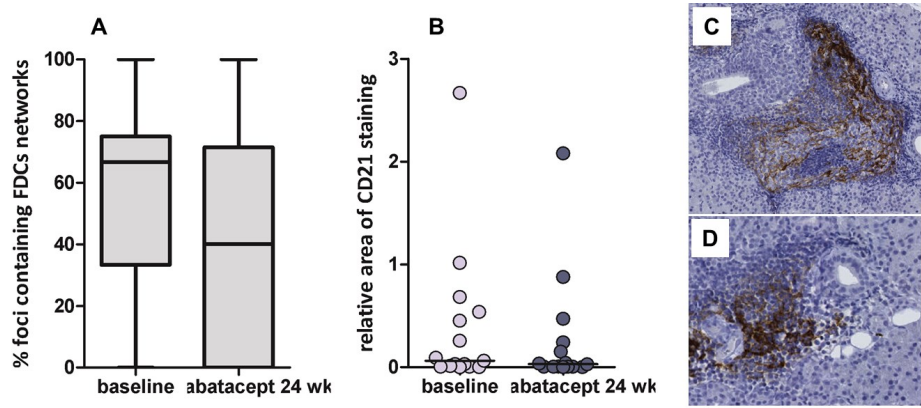
Supplementary Table 2: Antibodies used for immunohistochemistry.

Antigen	Clone	Host	Company
CD20	L-26	Mouse	Ventana Roche
CD3	2GV6	Rabbit	Ventana Roche
CD45	2B11 + PD7/26	Mouse	Ventana Roche
CK8/18	B22.1 + B23.1	Mouse	Ventana Roche
CD21	2G9	Mouse	Ventana Roche
IgA	Polyclonal	Rabbit	Ventana Roche
IgG	Polyclonal	Rabbit	Ventana Roche
IgM	Polyclonal	Rabbit	Ventana Roche



Supplementary Figure 1: Severity of LELs in pSS patients treated with abatacept.

LELs are classified in three stages⁹ as stained for CD20 + CK8/18. Stage 1: LEL affecting less than 50% of the epithelium of the striated duct (partial LEL); Stage 2: LEL affecting between 50% and 100% of the epithelium of the striated duct (developed LEL); Stage 3: LEL with fully circumferential affected epithelium without lumen (occluded LEL). Y-axis indicates the total number of patients before (open circles) of after (closed circles) treatment, while X-axis the presence of different stages of LELs. Of note patients can have various stages of LELs at the same time.



Supplementary Figure 2: Network of follicular dendritic cells in parotid glands of pSS patients treated with abatacept

A) The proportion (in percentages) of foci containing networks of follicular dendritic cells (FDCs) per patient as visualized by CD21 staining. Boxes represent the interquartile range divided by the median with Tukey-style whiskers. Of the pSS patients, 87% (13/15) showed a CD21⁺ FDC network within at least one focus, and 73% (11/15) after treatment. **B)** Relative area of CD21 staining, measured by Aperio ImageScope. **C)** Example of a CD21⁺ FDC network with a morphologically recognizable germinal center. **D)** Example of a CD21⁺ FDC network without a morphologically recognizable germinal center.



CHAPTER 9

General discussion

Large parts of this chapter are derived from “The role of salivary gland histopathology in primary Sjögren’s syndrome: promises and pitfalls”.

F.G.M. Kroese¹

E.A. Haacke^{1,2}

M. Bombardieri³

Department of ¹Rheumatology & Clinical Immunology, ²Pathology and Medical Biology, University of Groningen, University Medical Center Groningen, the Netherlands, ³Centre for Experimental Medicine and Rheumatology, William Harvey Research Institute, Queen Mary University of London, UK.

Clin Exp Rheumatol. 2018;36 Suppl 112(3):222-33

INTRODUCTION

The formation of lymphomononuclear cell infiltrates organizing as periductal infiltrates in the salivary glands of patients with primary Sjögren's syndrome (pSS) is one of the hallmarks of the disease. The clinical role of salivary gland histopathology has been confined to the clinical classification and diagnosis of pSS whereby according to the ACR-EULAR criteria a positive histopathology finding is a requirement for the diagnosis of pSS in the absence of either anti-Ro/SSA. In recent years, further understanding of the heterogeneity of the immune cell infiltration and organization within the salivary glands of pSS patients and its correlation with clinical manifestations of the disease has led to propose salivary gland histopathology as a novel tool able to identify patients at higher risk of developing more severe extraglandular manifestations and lymphoma. Furthermore, recent clinical developments in ongoing randomized clinical trials with novel biologicals in pSS have focused on salivary glands histopathology to inform on patients stratification based on target validation, proof of drug efficacy and mechanisms of response/resistance to therapy.

In **this chapter** the promises and the future prospective of salivary gland histopathology in pSS patients are discussed. Following a brief introduction on the formation of the periductal inflammatory infiltrates in the salivary gland tissue of pSS patients, the focus in **this chapter** will be on three critical aspects of salivary gland histopathology that are of important clinical relevance in patients with pSS:

- 1) The performance of histopathology as a diagnostic tool discussing the focus score, lymphoepithelial lesions (LELs) and relative decrease of IgA⁺ plasma cells.
- 2) Salivary gland histopathology as predictor of disease severity and lymphomagenesis in pSS patients with special emphasis on the role of germinal centers.
- 3) The emerging role of salivary gland histopathology in evaluating clinical response in clinical trials.

Formation of the periductal lymphoid infiltrate

The salivary glands of pSS patients are characterized by chronic inflammation as witnessed by the presence of lymphocytic infiltrates (or lymphocytic foci) located around the striated ducts (Figure 1A). These so-called periductal foci can be seen in both minor and major salivary glands and are present in most pSS patients. The foci are mainly composed of T- and B-lymphocytes with few other mononuclear cells, including macrophages, myeloid and plasmacytoid dendritic cells, and follicular dendritic cells.¹ They may develop to organized ectopic lymphoid structures resembling secondary lymphoid organs with segregated T- and B-cell areas, and high endothelial venules (HEVs).² These structures contain all components to carry out effectively immune responses. This is reflected by the presence

of germinal centers (GCs) in the B-cell areas of the organized periductal infiltrate in roughly a quarter of the pSS patients³ and the presence of (IgG) plasma blasts and plasma cells at the border of the infiltrate.² Initially, (activated) lymphocytes and (IgG expressing) plasma blasts are thought to be attracted towards the salivary gland tissue by the combined action of pro-inflammatory cytokines and chemokines. The triggers for this early event are not known, but viruses might well be implicated.⁴

A major pro-inflammatory chemokine likely involved in the early formation of the periductal infiltrate is the chemokine CXCL10 (IP-10) which is highly expressed by the ductal epithelium.^{5,6} Increased levels of CXCL10 are found in saliva, tears and serum from pSS patients. Early pSS patients express the highest levels of CXCL10 in their saliva, emphasizing the importance of this chemokine in the initial phases of the disease.^{7,8} CXCL10 binds to its receptor CXCR3, which is highly expressed by CD4⁺ Th1-cells.⁹ Several other cells, including (activated and memory) B-cells, IgG secreting plasmablasts and some plasmacytoid dendritic cells express the CXCR3 receptor and can also be attracted to the salivary glands.¹⁰ The relatively unorganized infiltrates may transform towards more organized ectopic lymphoid structures. Triggers essential for this transition in human salivary glands are only poorly understood, but a role for lymphoid tissue inducer cells and Th17-cells have been suggested.¹¹⁻¹³ The lymphoid tissue inducer cells and Th17-cells produce cytokines such as lymphotoxin β , RANKL, IL-17 and IL-22 which, in turn, promote production of the homeostatic lymphoid chemokines CXCL13, CCL19, CCL21 and CXCL12 by stromal and other cells.^{2,12,13} All these chemokines (protein and mRNA) are strongly upregulated in salivary glands of pSS patients.¹⁴⁻¹⁷ Collectively they are involved in attraction of naïve and memory T- and B-lymphocytes, plasmablasts, and other immune cells to the inflamed sites, and formation and maintenance of the organized lymphoid structures.² Prolonged activation of the glands leads to development of follicular dendritic cell (FDC) networks and segregation of the T- and B-cells.¹⁸ The FDCs, which characteristically express the long isoform of CD21 (complement receptor 2), as well as other stromal cells produce CXCL13 and are instrumental in the formation of B-cell rich areas, due to the binding of this chemokine to its receptor CXCR5. In conjunction with CXCL12, CXCL13 also supports formation and function of GCs.^{15,19,20} This important role of CXCL13 in pSS histopathogenesis is illustrated by the fact that elevated levels of this chemokine are detected in the saliva and blood of pSS patients with the highest saliva levels seen in patients with xerostomia.²¹ Furthermore, high expression levels of CXCL13 in the labial gland biopsy are associated with higher number of periductal foci and higher disease activity.²² This might indicate that with progression of the disease, as indicated by more severe inflammatory lesions in the glandular tissue, the number of infiltrating B-lymphocytes increases.¹ CXCL12 is also produced in healthy salivary glands and is important for migration and survival of (largely IgA⁺) plasma cells in the proximity of the acini.^{23,24} In pSS patients the production of CXCL12 by acinar and ductal cells is strongly enhanced.^{15,16} CXCL12 forms, together with IL-6 and APRIL, survival niches for long-lived plasma cells within the salivary gland tissue.²⁵ Thus, the initial infiltrate, which is rather unorganized,

evolves under the influence of homeostatic, lymphoid chemokines towards ectopic lymphoid structures characterized by segregated T- and B-cell areas (with FDC networks), in which GCs may develop. Whether progression of the disease in individual pSS patients is always associated with these sequential stages of histopathology remains to be shown.

Focus score and its diagnostic role

The presence of foci is thus a hallmark of the disease. For this reason histopathological analysis of the salivary gland is an important item in diagnosis and classification. A biopsy can be taken from either the labial or the parotid salivary gland. Although in most centers a labial gland biopsy is taken, the parotid gland biopsy is a good alternative and is a well-tolerated and safe procedure in experienced hands (chapter 2).^{26,27} For diagnosis and classification of pSS the presence of focal lymphocytic sialadenitis (FLS) in glandular biopsies (either labial or parotid) is assessed. The term FLS refers to the histopathological pattern of the presence of one or more foci in the biopsies, while the tissue surrounding the foci is composed mainly of unaffected parenchyma.²⁸ A focus is defined as an aggregate of ≥ 50 lymphocytes and the focus score (FS) is the total number of foci per 4mm^2 salivary gland tissue.^{29,30} In both labial and parotid gland a FS of ≥ 1 is considered as a positive biopsy and used for the classification of pSS. With a high FS of about 10, the foci become confluent and an arbitrary maximal score of 12 is given.^{30,31}

The importance of the calculation of the FS in the salivary gland biopsies is reflected by the prominent place of the biopsy in the current ACR-EULAR classification criteria. In these criteria a positive biopsy (i.e. $\text{FS} \geq 1$ per 4mm^2) accounts for 3 points, similar to the presence of anti-SSA antibodies. In these criteria, 1 point is attributed to either reduced saliva production or reduced tear production (or ocular damage). A total of 4 or more points in suspected pSS patients (i.e. patients with at least one symptom of ocular or oral dryness or positive ESSDAI (European League Against Rheumatism Sjögren's Syndrome Disease Activity Index)) leads to the classification of pSS.^{32,33} Thus, for fulfillment of the criteria a positive biopsy and/or presence of anti-SSA antibodies is required. For a correct assessment of the FS, analysis of a glandular surface area of at least 8mm^2 is recommended.³⁴ The specificity and diagnostic accuracy of the biopsy can be increased by multiple cutting levels, especially for pSS patients with a FS of 1.0 to 1.9.³⁵ For the diagnosis of pSS, the sensitivity and specificity of the parotid gland biopsy and labial gland biopsy are comparable. The sensitivity of the labial gland biopsy ranges from 64% to 94% and specificity from 61% to 100%. The parotid gland biopsy has a sensitivity of 78% and specificity of 86%.^{36,37}

Not all pSS patients have a positive salivary gland biopsy. In 18-40% of the pSS patients the labial gland biopsy is negative, i.e. have a $\text{FS} < 1.0$.³⁷⁻³⁹ These patients might be at risk to be misclassified as non-pSS according to the ACR-EULAR criteria. The clinical diagnosis based upon expert opinion is important in these cases. It is not known whether foci are

evenly spread throughout the salivary glands, and there is always a risk for sampling errors, in particular in patients with a low number of foci. Multiple sectioning levels in an inconclusive biopsy might reduce the possibility of a falsely negative biopsy.³⁴ Foci can also be found in healthy individuals: 6-9% of the healthy individuals have a FS of > 1.0 in a labial gland biopsy and 5% in a parotid gland biopsy.^{37,40,41} In addition to the FS, two scoring systems for salivary glands are in use for diagnosis and classification of pSS (see Table 1). These scoring systems are also based on the presence of foci. Grading according to Tarpley takes the destruction of acinar tissue and fibrosis into account and Chisholm and Mason also take the presence of diffuse infiltrates into account, when the FS is lower than 1.^{29,42} Since all three scoring systems are in use, it is important to avoid any confusion, to indicate which scoring system has been used for the evaluation of the tissue.

Table 1: Grading systems for salivary gland biopsies of Chisholm/Mason and Tarpley.^{29,42}

Chisholm/Mason		Tarpley	
Grade	Lymphocytes per 4 mm ² of salivary gland tissue	Grade	Description
0	Absent	0	Normal
1	Slight infiltrate	1	1 or 2 aggregates [#] (minimal infiltration)
2	Moderate infiltrate or less than one focus [*]	2	>3 aggregates [#]
3	One focus [*]	3	Diffuse infiltrate with partial destruction of acinar tissue with or without fibrosis
4	More than one focus [*]	4	Diffuse infiltrate with or without fibrosis destroying the lobular architecture completely

^{*}Focus: a cluster of 50 or more lymphocytes and histiocytes.

[#]Aggregate: approximately 50 cells (lymphocytes, plasma cells, or histiocytes)

Limitations of the focus score

The FS (and the other scoring systems based upon the number of foci) is a robust classification tool in defining biopsies as positive or negative, but it has certain shortcomings. Although the definition of the FS should not give rise *per se* to significant issues with interpretation, in reality failure to apply the FS or its miscalculation in clinical diagnostic setting is rather the norm. Vivino et al. reported that a second expert evaluation of 58 labial salivary glands re-analysed by a single center led to revision of the initial diagnosis in a staggering 53% of the patients.⁴³ Problems in assessing the FS also arise when other histopathological patterns besides focal lymphocytic sialadenitis, such as non-specific chronic sialadenitis, sclerosing chronic sialadenitis are present.²⁸ With increasing age of healthy individuals, acinar atrophy, fibrosis and increase of fat cells are commonly observed in the labial salivary gland tissue.^{44,45} These age-associated changes result to a reduced acinar capacity and may consequently lead to a decrease in saliva production. Compared

to healthy controls, labial gland biopsies of pSS patients exhibit more acinar atrophy and fibrotic changes.^{46,47} This is likely the result of the sustained chronic inflammation. There is no consensus whether there is an increase in the amount of adipose tissue in labial gland biopsies of pSS patients compared to age-matched healthy controls. The study of Skarstein et al.⁴⁸ reported a higher occurrence of fat infiltration in labial gland biopsies in pSS patients compared to non-pSS controls. In contrast, Leehan et al.⁴⁹ showed that the increased area of fat tissue in the labial gland biopsy is not specifically associated with pSS but is a selective feature of aging. For the calculation of the FS, Fisher et al.³⁴ recommended to evaluate the whole section of the gland, including, fibrotic areas tissue, atrophic areas and adipose tissue. When fibrotic and atrophic changes in the biopsies progress, the inflammation is slowly extinguished leading to a “burnt-out” biopsy, even resulting in a negative FS.⁵⁰ How many patients finally evolve to this stage is not known. Generally speaking, the FS is thought to be rather stable and only progresses slowly over time.^{50,51} In the study of Shiboski et al. repeated biopsies with a 2 to 3 year time interval were taken in 498 participants (Sjögren patients and non-SS sicca patients) from the SICCA-cohort. In these patients the result of the labial gland biopsy changed in 7% of the patients from FS-negative to FS-positive, in 11% of the patients from positive to negative and in 82% of the patients the FS remained unchanged.⁵²

An important drawback of the FS is that it is only based upon the number of foci and does not include the size of these foci. For a better estimation of the level of inflammation in the salivary gland biopsy, the area of infiltrate can be evaluated.^{34,53} This gives a more precise indication of how much glandular tissue is involved in the inflammation. Likely, such an approach is also more sensitive to change, in case sequential biopsies are taken for evaluation of treatment effects, or for follow-up of disease progression. This is especially important when foci are confluent and should strictly be considered as a single focus. Measurement of the area of infiltrate can be done with a regular HE stain or after immunohistological staining for CD45 (staining all leucocytes) (chapter 7a).^{34,53} Currently, there is no cut-off level for the classification/diagnostic use of the area of infiltrate, but in clinical trials with pre- and post-treatment biopsies measurement of the infiltrated area can give important information (chapter 7a).⁵³

Other histopathological markers besides focus score

In addition to periductal infiltrates there are also other histopathological features in the glands that are associated with pSS and therefore might be indicative for this disease. Besides FS, lymphoepithelial lesions (LELs) and a relative decrease of IgA⁺ plasma cells, appear to be characteristic for pSS.⁵⁴⁻⁵⁷ Both features can aid in assessment of the salivary gland biopsies for the diagnosis of pSS, especially when the FS in the biopsy is <1. LELs are striated ducts, which are infiltrated by lymphocytes with concurrent hyperplasia of the epithelial cells (Figure 1B).⁵⁸ LELs can be found both in labial and in parotid glands, albeit

that they seem to be more pronounced within the parotid gland tissue.³⁷ These structures are always associated with periductal infiltrates and solitary LELs are not present. In pSS patients LELs are present in 58%-93% of the parotid gland biopsy compared to 33%-86% of the labial gland biopsies (chapter 4 and 5).^{58,59}

The sensitivity and specificity of LELs in the diagnosis of pSS is not known. The current hypothesis in development of LELs is that the infiltrated lymphocytes cause the hyperplasia of the epithelium (chapter 5).^{56,59} This hyperplasia can ultimately result in complete occlusion of the striated duct. Based upon the proportion of the hyperplastic epithelium we proposed a classification system for the severity of the LELs: stage 1: a partial LEL (affecting <50% of the epithelium), stage 2: developed LEL (affecting 50% -100% of the epithelium), stage 3: occluded LEL (fully circumferentially affected epithelium without lumen) (chapter 5 and 7a).⁵³ The infiltrating lymphocytes comprise both B- and T-cells. With progression of the severity of the LELs the relative number of B-cells within the lesions increase, suggesting an important role for B-cells in epithelial proliferation (chapter 5).⁵⁸ The vast majority of the B-cells within the LELs of pSS patients express FcRL4 (chapter 4).⁵⁹ Fewer FcRL4⁺ B-cells are located outside the LELs, but still within the foci and the intensity of FcRL4 expression decreases outside the LEL. The FcRL4⁺ B-cells represent a small subset of highly proliferative mucosal memory B-cells.^{60,61} Most non-Hodgkin lymphomas associated with pSS are (salivary gland) mucosa-associated lymphoid tissue (MALT) B-cell lymphomas and 93%-97% of these MALT lymphomas express FcRL4 (chapter 4).^{59,62} We have shown that B-cells in the LELs are also targeted with rituximab treatment (chapter 7a).^{53,63} This results into normalization of the ductal epithelium, which strongly argues that factors derived from the FcRL4⁺ B-cells are responsible for the epithelial hyperplasia (chapters 4 and 5). Although LELs are characteristic for pSS, they are not specific for the disease as for example patients with an HIV infection may also harbor cystic LELs within their salivary glandular tissue.⁶⁴

Besides LELs the salivary gland of pSS patients also show a relative decrease in IgA⁺ plasma cells, and a relative increase in IgG⁺ and IgM⁺ plasma cells compared to control individuals (Figure 1C).⁵⁵ This relative IgA⁺ plasma cell decrease is largely due to a marked increase in numbers of IgG⁺ and in to a lower extent also IgM⁺ plasma cells.^{25,55} The absolute number of IgA⁺ plasma cells remains more or less constant in pSS. The IgG⁺ and IgM⁺ plasma cells are mostly located in the periphery of the foci and unaffected parenchyma. The diagnostic threshold of <70% IgA was set by Bodeutsch et al. based upon labial gland biopsies pSS patients compared to the control groups consisting of healthy controls, keratoconjunctivitis sicca patients and RA patients.⁵⁴ In the biopsies of pSS patients the relative decrease of <70% IgA has a specificity of 95.4% and a sensitivity of 100%.⁵⁵ Several studies showed that a relative decrease of <70% IgA⁺ plasma cells (and consequently increase in IgG⁺ and IgM⁺ plasma cells) was more sensitive and more disease specific than the FS.^{54,57,65} Even without the presence of foci a decrease of <70% IgA⁺ plasma cells

is possible.⁵⁷ These robust data indicate that the combination of FS and <70% IgA can increase the accuracy of the biopsies as indicative for the diagnosis of pSS or not.⁵⁷

According to the ACR-EULAR classification criteria the salivary gland biopsy has to fulfill the criterion of FS \geq 1 to be considered positive.^{32,33} In daily clinical practice, however, an evaluation of the salivary gland biopsy for the presence of LELs and <70% IgA⁺ plasma cells besides the FS may greatly aid in the correct diagnosis of pSS. Both markers show high specificity and sensitivity in the labial and parotid gland biopsy (Haacke et al, manuscript in preparation). For instance, if a biopsy with FS<1 but LELs and a decrease of >70% IgA⁺ plasma cells are present, it is reasonable to interpret the biopsy as suggestive for pSS. Vice versa, if a biopsy has a FS just above 1 and lacks these additional features, the clinician should be aware that there might be a risk of a falsely positive biopsy.

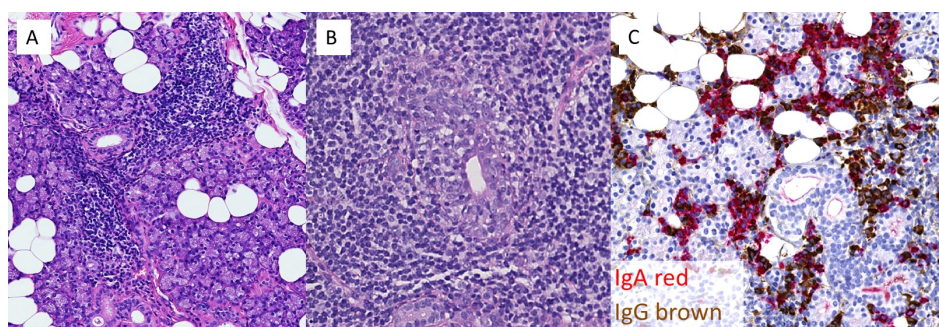


Figure 1: Histopathological changes in parotid gland biopsies of pSS patients

The examples are all from parotid gland tissue. **A)** Periductal focus surrounded by unaffected parenchyma. **B)** Centrally located duct forming a lymphoepithelial lesion within a focus. **C)** Dual staining for IgA and IgG expressing plasma cells, showing a decrease of <70% IgA expressing plasma cells.

Salivary gland histopathology as predictor of disease severity and lymphomagenesis: the case for and against ectopic GCs

The appreciation of the high heterogeneity of the degree of immune cell infiltration in the salivary glands of pSS patients ranging from sparse T-cells to highly organized B-cell-rich follicles has prompted the investigation of whether salivary gland histopathology could be associated with disease severity and predict disease evolution including lymphomagenesis. Approximately 5-10% of patients with pSS will develop a non-Hodgkin B-cell lymphoma, most commonly MALT lymphomas which predominantly arises in parotid glands as a low grade lymphoproliferative disorder, but can evolve into more aggressive large B-cell lymphomas.⁶⁶ Malignant B-cell clones originate from precursors already infiltrating the pSS salivary glands during the polyclonal phase of the local humoral response and are progressively enriched during the progression from lymphoepithelial lesions to MALT

lymphomas.^{59,67} Of interest, malignant B-cells often display Ig variable heavy (IgVH) gene rearrangement observed in rheumatoid factor producing B-cells suggesting that lymphomagenesis in pSS is an (auto)antigen-driven process taking place within the salivary gland tissue.^{68,69}

Antigen-driven B-cell selection normally takes place in GCs within secondary lymphoid organs but there is definitive evidence that also ectopic GCs in the salivary glands of pSS allow affinity maturation of GC B-cells with somatic Ig gene hypermutation.⁷⁰ This somatic hypermutation is not limited to GCs, but can occur at extrafollicular sites such as the T zone-red pulp border.^{71,72} Somatic hypermutation, but also Ig isotype class switching, is dependent on the enzyme activation-induced cytidine deaminase (AID) encoded by the AICDA gene which is expressed by GCs in the pSS salivary glands.^{73,74} Of interest, AICDA mRNA expression in MALT lymphomas is strongly associated with the process of aberrant somatic hypermutation whereby off-target mutations in important genes regulating B-cell proliferations promote genetic instability and malignancy.⁷⁵ Thus, there is a immunological rationale whereby GCs might represent key early pathogenic players in the process of B-cell lymphomagenesis and their histopathological detection in the salivary glands might help in predicting patients at increased risk of lymphomagenesis; however, conflicting evidence on this topic has emerged in the last 10 years. These studies are discussed below in chronological order of publication.

In a first report in a small retrospective cohort of 8 pSS patients with MALT lymphoma and matched parotid and labial salivary gland biopsies the prevalence of GCs in labial salivary gland tissue prior (average 3.3 years) to lymphoma was reported to be significantly higher (75% vs 33%) in SS patients who later developed MALT lymphomas.⁷³ In this work, GCs were defined by the presence of CD21+ FDC networks containing AID+ GC B-cells.

In a retrospective-prospective study of a large Swedish cohort of 174 pSS minor salivary gland biopsies Theander et al⁷⁶ reported the presence of ectopic GCs, determined using haematoxylin and eosin as focal lymphocytic foci with features indicative of lymphoid organization such as a densely packed dark zone and a light zone, in 32% of the patients. Linkage with the national cancer registry identified 7 pSS patients with NHL with a median time lapse between salivary gland biopsy and NHL diagnosis of 8 years. Similar to the previous report⁷³, the prevalence of GCs in pSS patients who later developed lymphoma was significantly increased (86%). The relative risk of developing NHL in pSS patients with GC formation calculated using Cox regression analysis and Kaplan Meier statistics/log rank test was 15.4-fold higher compared to the GC negative pSS subset with a negative predictive value of 99%. Additionally, the presence of GC correlated with anti-SSA/SSB autoantibodies, lymphadenopathy and peripheral neuropathy as defined in the relevant ESSDAI domains.⁷⁶

These promising data were not confirmed by Johnsen et al⁷⁷ who conducted a retrospective nationwide search in the Cancer Registry of Norway and identified 21 patients with lymphoma (~50% with salivary gland MALT lymphomas) including 12 with

previous, concomitant or subsequent matching labial salivary glands tissue blocks. These tissue blocks were analyzed for GCs and compared with 28 labial salivary gland biopsies from patients with pSS without lymphoma matched for sex and age. GCs were defined by hematoxylin and eosin staining plus immunohistochemistry for IgD/CD21 and IgD/CD38. Although pSS patients with lymphoma displayed a significantly higher FS, no significant difference in the prevalence of GCs was observed. Somewhat surprisingly, in this study ectopic GCs were more frequent in pSS without than with lymphoma (46% vs 33%), a result which was also mirrored by a higher prevalence of CD21⁺ FDC networks (71% vs 58%).

In a large Greek cohort the presence of GC in the labial salivary gland biopsy were not an independent risk factor for NHL development.⁷⁸ This cohort comprised 92 pSS patients with NHL (79% MALT lymphoma) and 381 pSS patient without lymphoma. Of the 92 pSS patients with NHL, 49 minor salivary gland biopsies were available and 11 (22%) showed GC. In the pSS patients without lymphoma 12/101 (12%) showed GC in the minor salivary gland biopsy ($p=0.15$). In the biopsies of the pSS patients who did develop NHL a FS >1.6, Tarpley score ≥ 3 and the presence of monoclonality in the tissue were significantly more frequently observed. The manner in which GCs were assessed in the biopsies was not given in the article.

Similar negative results were reported in the University of Groningen Medical Center cohort where 11 labial salivary gland biopsies taken at diagnosis were available from patients who later developed a MALT lymphoma (median time lapse 4 years) (chapter 6a).⁷⁹ A population of 22 pSS patients with no lymphoma was taken as control. In this cohort, GC identification was based on hematoxylin and eosin plus staining for Bcl-6, a marker of GC B-cells. No difference in the prevalence of GC was observed (18% in both groups), although pre-lymphomatous LEL were observed in 7 out of 11 of the GC+ pSS subset prior to lymphoma (chapter 6a).

In a recent multicenter French study of 115 minor salivary gland biopsies with 8 identified cases of subsequent NHL (median time lapse 51 months), Sène et al reported a significant increase in the prevalence of GCs comparing pSS patients with and without subsequent NHL (37.5% vs 15% with an incidence of GCs of 16.5% in the total pSS cohort).⁸⁰ In this study the definition of the GC was based on hematoxylin and eosin staining together with presence of FDC and B-cells with low activity of Bcl-2 and high activity of Bcl-6. Of relevance, after Cox multiple regression analysis, but not in univariate analysis, the presence of ectopic GCs in the salivary glands remained an independent positive predictor of lymphoma with a conferred increase hazard ratio of 7.8. Within this study

half of the pSS patients developing NHL were male, and all pSS patients who developed NHL, had a monoclonal gammopathy (MG). MG is a known risk factor for NHL and in the general pSS patients population the presence of MG is 4-22⁸⁰⁻⁸² Most important, MG is, just as the presence of GCs in the salivary gland biopsy, associated with higher disease activity.^{82,83} As, both GCs and MG are associated with higher disease status, there is no clear indication that presence of *ectopic* GCs is a prerequisite for MALT lymphoma development (chapter 6b).

In addition to the above studies, indirect evidence of the potential clinical relevance of GCs on lymphomagenesis has been provided by Carubbi et al⁸⁴ who showed that GC+ pSS patients displayed increased prevalence of several clinical and laboratory risk factors previously associated with lymphoma including salivary gland swelling, hypergammaglobulinemia, RF positivity. Additionally, they reported that pSS patients with GC had a higher prevalence of a salivary gland FS >3, which is of significant interest considering that a FS ≥ 3 has been reported in multivariable linear regression analysis as an independent risk factor for lymphomagenesis in pSS patients based on a meta-analysis by Risselada et al.⁸⁵

Reconciling conflicting data on ectopic GCs in pSS: the need for longitudinal studies and consensus on standardization

As emerged from the studies reviewed above, salivary gland histopathology, with particular reference to the identification of ectopic GCs, has potential clinical utility in the management of pSS by identifying patients with an increased risk of severe clinical manifestations with high disease activity and possibly lymphoma. A critical review of the evident pitfalls of existing studies would help in further progressing the field thus paving the way for more conclusive studies. At least two major criticisms should be made regarding existing data; those related to study design and those related to the identification of GCs. Regarding the former, the major limitation is the retrospective nature of these studies, potentially introducing selection bias, particularly in the control population. Additionally, considering the relatively low prevalence of lymphoma in pSS, all the previous studies have largely underpowered cohorts with only a handful of cases with lymphoma available for analysis. Further confusion is dependent on the inclusion of different subtypes of NHL in the different studies, from selected populations of MALT- lymphoma to a mix of different lymphoproliferative malignancies underlined by diverse pathogenic mechanisms. Furthermore, high variability in the follow up time from labial biopsies to diagnosis of NHL, ranging from medians of few months to several years further complicates the comparative analysis in different studies. On top of the above limitations which are somewhat intrinsic to the complexity of studying a low prevalence clinical manifestation in a relatively low prevalence disease such as pSS, there are technical aspects related to the identification of GCs which could be overcome with a consensus on standardization of the protocols used to define what an ectopic GC is. This aspect should move away from the identification of GCs in secondary lymphoid organs such as tonsils or lymph node as ectopic GCs in pSS salivary do not necessarily reflect the same physiopathological mechanisms.

As indicated above, virtually all existing studies on GCs in pSS salivary glands have used a different definition of GCs resulting in highly variable incidences of GCs in the different cohorts. Simple hematoxylin and eosin staining has intrinsic limitations as a clear separation of dark and light zone is frequently absent in ectopic GCs. Furthermore, LEL can sometimes

be mistakenly identified as GCs (**chapters 3a and 3b**). Addition of immunohistochemistry for the identification of GCs is certainly of help, however there is no consensus on the markers required. Double staining for CD3/CD20 followed by CD21 can help identifying follicles with T/B-cell segregation with differentiation of FDC networks; however, CD21 staining can potentially overestimate the prevalence of GCs as the non-long isoform of CD21 is also expressed by B-cells. More specific staining for GC B-cells such as Bcl-6 and AID display variable degrees of sensitivities and risk falling in the opposite direction of underestimating GC prevalence. In a recent study we compared Bcl-6 and CD21 stainings in the parotid- and labial gland biopsies. This study showed that the number of foci containing CD21⁺ FDC-networks was significantly higher than foci harboring Bcl-6⁺ cell clusters. The foci with CD21⁺ FDC-networks only showed Bcl-6⁺ cell clusters in 18% (9/50) of the labial gland and 32% (22/69) of the parotid gland biopsies. This indicates that CD21 as surrogate marker for GCs overestimates the number of GCs and that Bcl-6 is a more suitable marker for identification of GCs in salivary gland biopsies of pSS patients (**chapter 3c**). Additionally, there are other critical aspects which need to be considered and cannot be critically evaluated in the present studies. GCs are “skip lesions” which are variably present in adjacent minor salivary glands, thus a minimal number of individual biopsies should be taken in order to cover minimal total area of 8mm², as we recently suggested.³⁴ Additionally, including multiple cutting levels would maximize the accuracy of the analysis.³⁵ All these factors combined advocate for consensus guidelines to standardize the assessment of ectopic germinal centre-like structures in salivary gland tissue of pSS-patients (**chapters 3a and 3b**).^{86,87} Furthermore, design of prospective multicenter studies with centralised review of labial salivary gland biopsies would be required to provide definitive evidence in support of the use of salivary gland histopathology in general and ectopic GCs in particular as clinically meaningful predictors of disease progression to inform management of pSS patients.

Role of salivary glands biopsies in clinical trials

Since xerostomia is one of the major complaints of pSS patients and salivary glands are a primary target of the autoimmune process, the histopathological changes in these glands are of utmost importance for evaluating (new) treatment options. Currently, most clinical trials take the change in ESSDAI scores as primary endpoint, implying that pre- and post-treatment biopsies are not required.^{88,89} Nevertheless, post-treatment biopsy evaluation may give important information about efficacy of the treatment, mode of action of the compound, effect on the glandular tissue and the pathogenic mechanism of the disease (**chapter 7a and 8**).

The inclusion of pSS patients in clinical trials is usually based upon the latest classification criteria for pSS. Hence also patients without a salivary gland biopsy, or with a “negative” biopsy (i.e. FS<1.0) may enter these trials. In these negative biopsies, in which lymphoid infiltrates may even be completely absent, the possible effect of treatment on the

lymphocytic inflammation cannot be assessed in their post-treatment biopsies. Only few clinical trials used a positive salivary gland biopsy as additional inclusion criterion (**chapter 7a and 8**).^{90,91} The disadvantage is that fewer pSS patients qualify for inclusion into the study and that there might be a patient bias.

Although repeated biopsies can be taken from both minor and major salivary glands, taking biopsies from the parotid glands has certain advantages (**chapter 2**). The major advantage of parotid glands over labial glands is that post-treatment biopsies can repeatedly be taken from the same gland as the initial (diagnostic) biopsy to evaluate treatment efficacy, while in case of labial salivary biopsies for every post-treatment assessment a new series of glands has to be removed for histopathologic review.^{37,92} Also disease recurrence or progression can be monitored. Another advantage of the parotid biopsy is that histopathological results can be directly correlated with other clinical and laboratory findings from the same gland such as parotid salivary flow, composition of the saliva and ultrasound (**chapter 2**).^{27,93} Fisher et al³⁴ published consensus guidelines for assessing salivary gland biopsies in clinical trials (Table 2). The evaluation of the biopsies encompasses the same aspects as for diagnostic biopsies and includes FS, percentage of CD45⁺ infiltrate presence of GCs and LELs. In this guideline CD21 is proposed to assess GCs, but as mentioned before, new data indicate that Bcl-6 is the most suitable marker for GC identification (**chapter 3c**). Furthermore, features like fibrosis, atrophy, fat infiltration and sialadenitis patterns besides FLS, should be reported. In addition to these general aspects, specific analysis should be performed, depending upon the drug used for treatment.

Response of salivary gland biopsies to biological DMARDs therapy

There are no approved biological DMARDs yet for the treatment of pSS, but there are a number of trials that have been performed or are currently running. In Table 3 the major findings have been summarized of the trials that also analyzed the effect of treatment on the salivary gland biopsy. Timing of the post treatment biopsies varies between the different trials and the histopathological items that were assessed are diverse. Obviously there is a need for standardization, in order to allow a proper comparison between the various studies. Most biologicals tested in pSS patients target the B-cells or signaling pathways leading to the formation, activation and expansion of (auto-reactive) B-cells.

BAFF (BLyS) plays an important role in the pathogenesis of pSS and elevated levels are present in the salivary glands.⁹⁴ Belimumab blocks the binding of soluble BAFF (BLyS) to its receptors on B-cells. In this manner the survival of (autoreactive) B-cells, their maturation and differentiation towards immunoglobulin secreting plasma cells are thought to be hampered.^{94,95} The efficacy of belimumab was first shown in an open label (BELISS) study of Mariette et al⁹⁶ in which 18/30 (60%) of the pSS patients responded based upon the SSRI-30 (Sjögren's Syndrome Responder Index-30) and 15/30 (50%) upon ESSDAI ≥ 3 points

at week 28. Seror et al⁹⁷ showed in a sub-study of 15 pSS patients of the BELISS trial that after 28 weeks of belimumab treatment the FS in the post-treatment labial gland biopsies tended to decline with a significant decrease in the Chisholm grading (see table 1). Furthermore, belimumab decreased the proportion of BAFF-positive cells and the B/T-cell ratio in the foci. Although this study was rather small, belimumab did seem to alter the composition of the infiltrates in the glandular tissue and a clinical response in ESSDAI of ≥ 3 was seen in 6/15 (40%) of pSS patients. In biopsies taken after continuous treatment up to 52 weeks, no significant difference in the FS was seen compared to baseline levels. Although FS and salivary function did not change after 52 weeks of treatment, the clinical response as measured by ESSDAI, continued to be lower than baseline levels.⁹⁸

Abatacept (CTLA4-Ig), which blocks the CD28-mediated co-stimulation of T-cells, has shown efficacy with respect to the ESSDAI in a phase II trial of pSS.⁹¹ Treatment with abatacept resulted in a significant decline in ESSDAI, whereas unstimulated and stimulated whole saliva flow did not increase. Abatacept treatment did not alter FS or the number of B-cells and T-cells in the parotid gland or the labial gland biopsy (chapter 8).^{99,100} The amount of CD45⁺ infiltrate and number or severity of LELs did also not change in the parotid gland biopsy. However, the number of GCs declined, and there was an increase in the number of IgM⁺ plasma cells.¹⁰⁰ Likely this reduction of GC activity is the consequence of a reduced CD28-mediated activation of T_H-cells (chapter 8).¹⁰¹ In the labial gland biopsy, Adler et al found decreased numbers of Foxp3⁺ regulatory T-cells in the foci after abatacept treatment.⁹⁹

Rituximab is directed to CD20 and treatment of pSS patients leads to a near complete depletion of B-cells in the blood at 12 weeks. Rituximab is also able to affect the glandular infiltrates in both labial and parotid glands, as reflected by lower FS or reduced surface area of CD45⁺ staining (chapter 7a).^{53,63,102-106} This effect is the direct result of a decline in B-cell numbers within the infiltrate, since T-cell numbers were unaffected. In addition there is a decrease in the number of GCs, within the infiltrates.^{53,102} Not only B-cells that constitute the infiltrate, but also intra-epithelial (FcRL4⁺) B-cells within the LELs were depleted by rituximab (chapters 4 and 7a).⁵⁹ This depletion of the intra-epithelial B-cells of the striated ducts was associated with a normalization/restoration of the ductal epithelium,^{53,63} which illustrates the importance of the interaction between intra-epithelial B-cells and formation of LELs (chapter 4 and 7a). These changes in parotid gland tissue after rituximab treatment, in particular the reduction in infiltrate size and normalization of LELs, is partially reflected in the glandular function. Three studies reported that the salivary flow increased after rituximab treatment^{53,63,90,102} Other clinical studies showed no change in the salivary function upon rituximab treatment.^{105,107-110} All together these studies indicate that the salivary gland function (measured by whole salivary flow) did not further deteriorate but remained stable or even improved after rituximab treatment.

Table 2: Guidelines for assessing salivary gland biopsies in general and for in clinical trials.

Table from publication of Fisher et al.³⁴

1	The minimum number of minor salivary glands is suggested to be four (six if small), and should be surgically separated
2	The minimum surface area of gland sections examined should be 8 mm ²
3	If the first cutting level is inconclusive, or in the context of a clinical trial, consideration should be given to including two additional cutting levels at 200 µm intervals (typical focus diameter is <50 µm) in order to increase the surface area
4	Care should be given to preparation of paraffin blocks, with smaller glands set higher to allow midspecimen sampling during cutting
5	Histological examination should determine whether there is FLS present. Attribution of FLS, or possible FLS, should be followed by calculation of a focus score
6	The extent (absent, mild, moderate, severe) of atrophy, fibrosis, duct dilatation and non-specific chronic sialadenitis, in addition to the presence or absence of FLS, should be reported
7	Calculation of the focus score should include the whole of the glandular surface area in the denominator, to avoid introduction of bias
8	The presence or absence of germinal centre-like structures and lymphoepithelial lesions should be reported

Guidance relevant to clinical trials

1	The focus score should be recorded, and the area of individual foci should also be summed and divided by glandular area to give a more quantitative indication of the extent of glandular infiltration
2	Once FLS has been confirmed, all foci should be included in the focus score and in area of foci calculations, even when adjacent to abnormal acini or ducts, to avoid introduction of bias
3	Staining for CD3, CD20 and CD21 should be included, and the presence of germinal centre-like structures should be reported as the proportion of foci with both T/B-cell segregation and follicular dendritic cell networks. Consideration should be given to reporting the mean B/T-cell ratio in foci
4	Scoring should be undertaken by two trained observers who have reviewed a reference slide set, and with reporting of intraobserver and interobserver variability
5	Samples should be scored blind to subject and order
6	High-resolution image morphometry of each sample should be stored
7	Given the stable or slowly progressive nature of the histological features, baseline biopsies may be substituted with prior biopsies to reduce the number of biopsies required. However, given the limited evidence available, these should have been acquired no longer than 1 year prior to baseline
8	The optimal period of time for rebiopsy has not been established and will depend on the agent employed.

Biopsies for stratification of patients

The various histopathological features might also be used for patient stratification for treatment, and precision medicine. For example, we showed ([chapter 7a](#)) that high absolute number of B-cells in the baseline parotid gland biopsy predicts better responsiveness of patients with pSS to rituximab treatment.⁵³ Response to rituximab was defined as a decline in ESSDAI of ≥ 3 points in this study, which is considered a clinically meaningful improvement.¹¹³ This response to rituximab seems to be in contrast with studies of Cornec et al^{104,114} which showed that pSS patients with a high proportion of B-cells and higher FS in the labial salivary gland predicted the absence of a clinical response to rituximab. In these studies responders were defined by the SSRI-30, a composite endpoint.¹¹⁵ As discussed extensively,^{116,117} differences in assessing B-cells in sections (numbers versus proportions) and differences in how clinical response were measured (ESSDAI versus SSRI-30), may contribute to explain the apparent differences in outcome ([chapter 7b](#)).

For belimumab, Seror et al⁹⁷ showed that low numbers of NK-cells, mainly located in the periphery of the foci of the labial gland biopsy are associated with a better response to treatment. In this study response was also defined as an decrease in ESSDAI of ≥ 3 points. Remarkably, the baseline number of BAFF⁺ cells in the biopsy could not predict response to belimumab.

Even when treatment with (biological) DMARDs leads to (complete) resolution of the inflammation of the glandular tissue, it is questionable whether this will result in a salivary gland that is fully restored and saliva production that has been returned to normal. The inflammation in the glandular tissue is likely to cause irreversible damage in the form of fibrosis and loss of acinar cells leading to sustained reduced saliva production^{46,47} Furthermore, in pSS patients the salivary gland stem cells responsible for the production of new epithelial and acinar cells are decreased in number and functional ability and exhausted as compared to healthy controls.¹¹⁸ This implies that after resolution of the inflammation, the gland cannot fully restore to the level of healthy individuals, and consequently saliva production might still be suboptimal.

In summary, in clinical trials with pSS patients, repeated biopsies give important information about treatment efficacy, the mode of action of the drug and the pathogenic mechanism of the inflammation within the salivary gland tissue. Treatment with biologicals such as rituximab and belimumab appear to have a positive effect on the salivary glands with at least stabilization of the salivary flow. Results from studies combining these two biologicals are eagerly awaited. Further studies for stratification of patients and studies to evaluate glandular function when the salivary infiltrates are fully diminished are needed.

Table 3: Overview of studies assessing histopathological salivary gland tissue before and after treatment with biologicals in pSS patients

Biological	Target	Trial	Study design	Number biopsies
Etanercept	TNF- α	Zandbelt ¹¹¹	Open label	N=10 Etanercept
Abatacept	CD28-mediated co-stimulation	Adler ⁹⁹	Open label	N=10 Abatacept
		Haacke, ^{59,100} Verstappen ¹⁰¹	Open label	N=15 Abatacept (Verstappen N=14)
Infliximab	TNF- α	Mariette ¹¹²	RDBPCT	N=57 (Infliximab + controls)
Rituximab	CD20 ⁺ B-cells	Delli ⁵³ Haacke ⁵⁹	RDBPCT	N=16 RTX, (Haacke N=18) N=9 placebo
		Ciccia ¹⁰³	Open label	N=10 RTX
		Cornec ¹⁰⁴	Open label and RDBPCT	N=14 low dose RTX (open label) N=17 high dose RTX (RDBPCT) N=14 placebo (RDBPCT)
		Pijpe ⁶³	Open label	N= 5 RTX
		Pers ¹⁰⁶	Open label	N= 15 RTX
		Devauchelle-Pensec ¹⁰⁹	Open label	N=16 RTX
		Carubbi ¹⁰²	Open label	N=19 RTX N=22 DMARDs
Belimumab	BAFF/BlyS	Seror ⁹⁷	Open label	N=15 Belimumab
		De Vita ⁹⁸	Open label	N=12 Belimumab

Abbreviations: TNF- α : tumor necrosis factor- α , BAFF: B-cell activating factor, BlyS: B-lymphocyte stimulator, RDBPCT: randomized double-blind placebo controlled trial, RTX: rituximab, DMARDs: disease modifying anti-rheumatic drugs, FS: focus score, GCs: germinal centers, IgA / IgG / IgM: IgA / IgG / IgM expressing plasma cells, HE: hematoxylin and eosin, LELs: lymphoepithelial lesions, \uparrow : increased, \downarrow : decreased, =: no significant change.

Gland	Time of biopsy	Histopathological evaluation
Labial	Baseline + week 12	FS = , %IgA =
Labial	Baseline + week 28	Foci/mm ² =, Number of foci ↓, CD20 =, CD3 =, CD4 =, CD8 =, Foxp3+ regulatory T-cells ↓, IgA =, IgG =, IgM =, fibrosis =, atrophy =
Parotid	Baseline + week 24	FS =, CD45 =, GCs (HE) ↓, LELs (HE) =, CD20 =, CD3 =, IgA =, IgG =, IgM ↑, CD21 =, FcRL4+ B-cells =, ICOS ↓, IL21+CD4+ cells =
Labial	Baseline + week 10	FS =
Parotid	Baseline + week 12	FS =, CD45 ↓, GCs (HE) ↓, LELs (HE) ↓, CD20 ↓, CD3 =, FcRL4+ B-cells ↓
Labial	Baseline + week 48	Chisholm grading =to↓, IL22+ infiltrating cells ↓, IL22+ myoepithelial cells ↓
Labial	Low dose RTX: baseline + week 12 High dose RTX and placebo: baseline + week 24	Low dose RTX week 12: proportion B-cells ↓, high dose RTX week 24: proportion B-cells =. Note: patients with persistent blood B-cell depletion at week 24: ↓ or = of tissue B-cells. Patients with blood B-cell repopulation before week 24: ↑ proportion of tissue B-cells at week 24. ¹⁰⁴
Parotid	Baseline + week 12	%acinar parenchyma =, %lymphocytic infiltrate ↓, %fat =, germinal centres ↓, LELs ↓, proliferation of acinar parenchyma (%Ki-67) ↓, B:T lymphocyte ratio in the infiltrate ↓
Labial	Baseline + 4 months (N=15), 12 months (N=3), 24 months (N=2)	B-cells ↓ (repopulation at 24 months), CD3 =, CD4 =, CD8 =
Labial	Baseline + week 12	FS =, B-cells ↓
Labial	Baseline + week 120	RTX: FS ↓, GCs (CD21) ↓, CXCR4+ and CXCR5+ cells in the mononuclear cell infiltrate ↓
Labial	Baseline + week 28	Chisholm grading ↓, FS =to↓, B-cell/T-cell ratio in the foci ↓, % BAFF-positive cells in foci ↓, NK infiltrate inside and outside the foci =
Labial	Baseline + week 52	FS =

Concluding remarks

There is little doubt that salivary gland histopathology is a cornerstone of the diagnostic algorithm in pSS, although the accuracy of the evaluation of FLS and FS calculations could be significantly improved by standardization. Besides solely focusing on the FS, adding the histopathological markers LELs and a relative decrease of $\leq 70\%$ IgA expressing plasma cells in the routine evaluation of the salivary gland biopsy may contribute to the correct diagnosis of pSS. Standardization of the identification of GCs in the glandular biopsies is essential to further evaluate the relevance of these structures. Larger, international, prospective studies, should provide more insights in clinical and laboratory characteristics of pSS patients with GCs in their salivary gland biopsy and whether their disease progression differs (e.g. towards lymphoma development) from patients without GCs in the biopsy. Furthermore, detailed studies, incorporating the histopathological parameters LELs and a relative decrease of $\leq 70\%$ IgA expressing plasma cells in the diagnosis of pSS are needed to establish the additional value of these markers besides the FS.

Currently, the University Medical Center of Groningen follows pSS patients for 10 years within the so-called REgistry of Sjögren syndrome in UMCG - LongiTudinal (RESULT) cohort. These patients are subjected to a full diagnostic work-up including a salivary gland biopsy in which, amongst others, the FS, proportion of CD45 infiltrate, presence of GCs, LELs and ratio between IgA and IgG expressing plasma cells are assessed. This RESULT cohort of pSS patients might provide insights in the correlation of these histopathological parameters of the salivary gland biopsy taken at time of pSS-diagnosis with a wide variety of biomarkers in blood, saliva and tears, salivary gland ultrasonography and clinical outcome during the progression of the disease.

Besides the glandular histopathology, the involvement of the salivary glands in pSS can be examined by salivary gland ultrasonography (SGUS). This is a well-tolerated non-invasive procedure which can be performed repeatedly. The SGUS evaluates the parotid and submandibular gland and are graded by the Hocevar score. Five domains are incorporated in the Hocevar scoring system: clearness of salivary gland borders, presence of hyperechogenic reflections, presence of hypoechogenic areas, the homogeneity of the gland, and the parenchymal echogeneity.¹¹⁹ The SGUS is considered positive if the Hocevar score is ≥ 15 .¹²⁰ The absolute agreement between SGUS and the salivary gland biopsy is good,¹²⁰ and studies incorporating the SGUS in the ACR-EULAR criteria are promising.^{121,122} Of note, a negative SGUS showed a positive labial biopsy in 26% of patients and 22% of patients with a positive SGUS had a negative parotid gland biopsy.¹²⁰ It is, however, currently not fully elucidated how the echographic images correspond with the histopathology of the glandular biopsies. Although SGUS is a valuable diagnostic instrument, especially in the follow-up of pSS patients, it is not likely to replace the biopsy soon. The SGUS is currently not specific enough to differentiate salivary gland changes

related to pSS from changes occurring in other auto-immune diseases such as sarcoidosis, amyloidosis and IgG4 related disease.^{123,124} Furthermore, the diagnosis of a (developing) salivary gland MALT-lymphoma cannot be made based upon SGUS.

The combination of salivary gland histopathology with molecular biology will provide interesting data in the future. With the use of spatial transcriptomics the expression levels of different genes in different areas in the salivary gland biopsies can be determined. This will allow to visualize, amongst the other endless possibilities, the differences in gene expression of epithelial cells from ducts with LELs and ducts without LELs, differences in gene expression of foci in different stages of organization and the effect of treatment on gene expression in different cells of the biopsy. Currently pubmed.com gives no hits for the terms “spatial transcriptomics” combined with “Sjögren’s syndrome”, indicating that the initial work on the gene expression profile of salivary gland biopsies from healthy controls, sicca non-pSS patients and pSS patients has yet to be performed and published.

Finally, with the new era of biological therapies coming to fruition in pSS, although currently still limited to the clinical trial phase, this thesis showed that salivary gland histopathology may assist in patient stratification regarding efficacy of the treatment, mode of action of the drug and unraveling immunopathological mechanism of pSS.

REFERENCES

1. Christodoulou MI, Kapsogeorgou EK, Moutsopoulos HM. Characteristics of the minor salivary gland infiltrates in Sjögren's syndrome. *J Autoimmun* 2010;34:400-07.
2. Bombardieri M, Lewis M, Pitzalis C. Ectopic lymphoid neogenesis in rheumatic autoimmune diseases. *Nat Rev Rheumatol* 2017;13:141-54.
3. Risselada AP, Looije MF, Kruize AA, et al. The role of ectopic germinal centers in the immunopathology of primary Sjögren's syndrome: a systematic review. *Semin Arthritis Rheum* 2013;42:368-76.
4. Kivity S, Arango MT, Ehrenfeld M, et al. Infection and autoimmunity in Sjogren's syndrome: A clinical study and comprehensive review. *J Autoimmun* 2014;51:17-22.
5. Kroese FGM, Abdulahad WH, Haacke EA, et al. B-cell hyperactivity in primary Sjögren's syndrome. *Expert Rev Clin Immunol* 2014;10:483-99.
6. Ogawa N, Ping L, Zhenjun L, et al. Involvement of the interferon-gamma-induced T cell-attracting chemokines, interferon-gamma-inducible 10-kd protein (CXCL10) and monokine induced by interferon-gamma (CXCL9), in the salivary gland lesions of patients with Sjögren's syndrome. *Arthritis Rheum* 2002;46:2730-41.
7. Hernández-Molina G, Michel-Peregrina M, Hernández-Ramírez DF, et al. Chemokine saliva levels in patients with primary Sjögren's syndrome, associated Sjögren's syndrome, pre-clinical Sjögren's syndrome and systemic autoimmune diseases. *Rheumatology (Oxford)* 2015;50:1288-92.
8. Lee YJ, Scofield RH, Hyon JY, et al. Salivary chemokine levels in patients with primary Sjogren's syndrome. *Rheumatology* 2010;49:1747-52.
9. Mitsias DI, Tzioufas AG, Veiopoulos C, et al. The Th1/Th2 cytokine balance changes with the progress of the immunopathological lesion of Sjogren's syndrome. *Clin Exp Immunol* 2002;128:562-68.
10. Muehlinghaus G, Cigliano L, Huehn S, et al. Regulation of CXCR3 and CXCR4 expression during terminal differentiation of memory B cells into plasma cells. *Blood*. 2005;105:3965-71.
11. Lin X, Rui K, Deng J, et al. Th17 cells play a critical role in the development of experimental Sjögren's syndrome. *Ann Rheum Dis* 2015;74:1302-10.
12. Randall TD, Mebius RE. The development and function of mucosal lymphoid tissues: a balancing act with micro-organisms. *Mucosal Immunol* 2014;7:455-66.
13. Van de Pavert SA, Mebius RE. New insights into the development of lymphoid tissues. *Nat Rev Immunol* 2010;10:664-74.
14. Amft N, Curnow SJ, Scheel-Toellner D, et al. Ectopic expression of the B cell-attracting chemokine BCA-1 (CXCL13) on endothelial cells and within lymphoid follicles contributes to the establishment of germinal center-like structures in Sjögren's syndrome. *Arthritis Rheum* 2001;44:2633-41.
15. Barone F, Bombardieri M, Manzo A, et al. Association of CXCL13 and CCL21 expression with the progressive organization of lymphoid-like structures in Sjögren's syndrome. *Arthritis Rheum* 2005;52:1773-84.
16. Salomonsson S, Larsson P, Tengné P, et al. Expression of the B cell-attracting chemokine CXCL13 in the target organ and autoantibody production in ectopic lymphoid tissue in the chronic inflammatory disease Sjögren's syndrome. *Scand J Immunol* 2002;55:336-42.
17. Xanthou G, Polihronis M, Tzioufas AG, et al. "Lymphoid" chemokine messenger RNA expression by epithelial cells in the chronic inflammatory lesion of the salivary glands of Sjogren's syndrome patients: Possible participation in lymphoid structure formation. *Arthritis Rheum* 2001;44:408-18.
18. Gommerman JL, Browning JL. Lymphotoxin/light, lymphoid microenvironments and autoimmune disease. *Nat Rev Immunol* 2003;3:642-55.
19. Allen CDC, Ansel KM, Low C, et al. Germinal center dark and light zone organization is mediated by CXCR4 and CXCR5. *Nat Immunol* 2004;5:943-52.
20. Jonsson MV, Skarstein K. Follicular dendritic cells

- confirm lymphoid organization in the minor salivary glands of primary Sjögren's syndrome. *J Oral Pathol Med* 2008;37:515-21.
21. Kramer JM, Klimatcheva E, Rothstein TL. CXCL13 is elevated in Sjögren's syndrome in mice and humans and is implicated in disease pathogenesis. *J Leukoc Biol* 2013;94:1079-89.
 22. Lee K-E, Kang J-H, Yim Y-R, et al. Predictive significance of CCL21 and CXCL13 levels in the minor salivary glands of patients with Sjögren's syndrome. *Clin Exp Rheumatol* 2017;35:234-40.
 23. Chu VT, Berek C. The establishment of the plasma cell survival niche in the bone marrow. *Immunol Rev* 2013;251:177-88.
 24. Hiepe F, Dörner T, Hauser AE, et al. Long-lived autoreactive plasma cells drive persistent autoimmune inflammation. *Nat Rev Rheumatol* 2011;7:170-78.
 25. Szyzsko EA, Brokstad KA, Oijordsbakken G, et al. Salivary glands of primary Sjögren's syndrome patients express factors vital for plasma cell survival. *Arthritis Res Ther* 2011;13:R2.
 26. Marx RE, Hartman KS, Rethman KV. A prospective study comparing incisional labial to incisional parotid biopsies in the detection and confirmation of sarcoidosis, Sjögren's disease, sialosis and lymphoma. *J Rheumatol* 1988;15:621-29.
 27. Spijkervet FKL, Haacke E, Kroese FGM, Bootsma H, Vissink A. Parotid Gland Biopsy, the Alternative Way to Diagnose Sjögren Syndrome. *Rheum Dis Clin North Am* 2016;42:485-99.
 28. Daniels TE, Cox D, Shiboski CH, et al. Associations between salivary gland histopathologic diagnoses and phenotypic features of Sjögren's syndrome among 1,726 registry participants. *Arthritis Rheum* 2011;63:2021-30.
 29. Chisholm DM, Mason DK. Labial salivary gland biopsy in Sjögren's disease. *J Clin Pathol* 1968;21:656-60.
 30. Greenspan JS, Daniels TE, Talal N, et al. The histopathology of Sjögren's syndrome in labial salivary gland biopsies. *Oral Surg Oral Med Oral Pathol* 1974;37:217-29.
 31. Daniels TE. Labial salivary gland biopsy in Sjögren's syndrome. Assessment as a diagnostic criterion in 362 suspected cases. *Arthritis Rheum* 1984;27:147-56.
 32. Shiboski CH, Shiboski SC, Seror R, et al. 2016 American College of Rheumatology/European League Against Rheumatism Classification Criteria for Primary Sjögren's Syndrome: A Consensus and Data-Driven Methodology Involving Three International Patient Cohorts. *Arthritis Rheumatol* 2017;69:35-45.
 33. Shiboski CH, Shiboski SC, Seror R, et al. 2016 American College of Rheumatology/European League Against Rheumatism classification criteria for primary Sjögren's syndrome. *Ann Rheum Dis* 2017;76:9-16.
 34. Fisher BA, Jonsson R, Daniels T, et al. Standardisation of labial salivary gland histopathology in clinical trials in primary Sjögren's syndrome. *Ann Rheum Dis* 2017;76:1161-68.
 35. Morbini P, Manzo A, Caporali R, et al. Multilevel examination of minor salivary gland biopsy for Sjögren's syndrome significantly improves diagnostic performance of AECG classification criteria. *Arthritis Res Ther* 2005;7:R343.
 36. Guellec D, Cornec D, Jousse-Joulin S, et al. Diagnostic value of labial minor salivary gland biopsy for Sjögren's syndrome: a systematic review. *Autoimmun Rev* 2013;12:416-20.
 37. Pijpe J, Kalk WWI, van der Wal JE, et al. Parotid gland biopsy compared with labial biopsy in the diagnosis of patients with primary Sjögren's syndrome. *Rheumatology (Oxford)* 2007;46:335-41.
 38. Vitali C, Moutsopoulos HM, Bombardieri S. The European Community Study Group on diagnostic criteria for Sjögren's syndrome. Sensitivity and specificity of tests for ocular and oral involvement in Sjögren's syndrome. *Ann Rheum Dis* 1994;53:637-47.
 39. Vitali C, Tavoni A, Simi U, et al. Parotid sialography and minor salivary gland biopsy in the diagnosis of Sjögren's syndrome. A comparative study of 84 patients. *J Rheumatol* 1988;15:262-67.
 40. Lindahl G, Hedfors E. Focal lymphocytic infiltrates of salivary glands are not confined to Sjögren's syndrome. *Scand J Rheumatol Suppl* 1986;61:52-55.
 41. Radfar L, Kleiner DE, Fox PC, et al. Prevalence and

- clinical significance of lymphocytic foci in minor salivary glands of healthy volunteers. *Arthritis Rheum* 2002;47:520-24.
42. Tarpley TM, Anderson LG, White CL. Minor salivary gland involvement in Sjögren's syndrome. *Oral Surgery, Oral Med Oral Pathol* 1974;37:64-74.
 43. Vivino FB, Gala I, Hermann GA. Change in final diagnosis on second evaluation of labial minor salivary gland biopsies. *J Rheumatol* 2002;29:938-44.
 44. Scott J. Qualitative and quantitative observations on the histology of human labial salivary glands obtained post mortem. *J Biol Buccale*. 1980;8:187-200.
 45. Vered M, Buchner A, Boldon P, et al. Age-related histomorphometric changes in labial salivary glands with special reference to the acinar component. *Exp Gerontol* 2000;35:1075-84.
 46. Leehan KM, Pezant NP, Rasmussen A, et al. Minor salivary gland fibrosis in Sjögren's syndrome is elevated, associated with focus score and not solely a consequence of aging. *Clin Exp Rheumatol* 2018;36:80-88.
 47. Llamas-Gutierrez FJ, Reyes E, Martínez B, et al. Histopathological environment besides the focus score in Sjögren's syndrome. *Int J Rheum Dis* 2014;17:898-03.
 48. Skarstein K, Aqrawi LA, Øijordsbakken G, et al. Adipose tissue is prominent in salivary glands of Sjögren's syndrome patients and appears to influence the microenvironment in these organs. *Autoimmunity* 2016;49:338-46.
 49. Leehan KM, Pezant NP, Rasmussen A, et al. Fatty infiltration of the minor salivary glands is a selective feature of aging but not Sjögren's syndrome. *Autoimmunity* 2017;50:451-57.
 50. Fisher BA, Brown RM, Bowman SJ, et al. A review of salivary gland histopathology in primary Sjögren's syndrome with a focus on its potential as a clinical trials biomarker. *Ann Rheum Dis* 2015;74:1645-50.
 51. Kapsogeorgou EK, Christodoulou MI, Panagiotakos DB, et al. Minor salivary gland inflammatory lesions in Sjögren syndrome: do they evolve? *J Rheumatol* 2013;40:1566-71.
 52. Shiboski CH, Baer AN, Shiboski SC, et al. Natural History and Predictors of Progression to Sjögren's Syndrome Among Participants of the Sjögren's International Collaborative Clinical Alliance Registry. *Arthritis Care Res (Hoboken)* 2018;70:284-94.
 53. Delli K, Haacke EA, Kroese FGM, et al. Towards personalised treatment in primary Sjögren's syndrome: baseline parotid histopathology predicts responsiveness to rituximab treatment. *Ann Rheum Dis*. 2016;75:1933-38.
 54. Bodeutsch C, Kater L, Kruze AA. Quantitative immunohistologic criteria are superior to the lymphocytic focus score criterion for the diagnosis of Sjögren's syndrome. *Arthritis Rheum*. 1992;35:1075-87.
 55. de Wilde PC, Kater L, Baak JP, et al. Quantitative immunohistologic criteria are superior to the lymphocytic focus score criterion for the diagnosis of Sjögren's syndrome. *Arthritis Rheum* 1989;32:1214-20.
 56. Ihrler S, Zietz C, Sendelhofert A, et al. Lymphoepithelial duct lesions in Sjögren-type sialadenitis. *Virchows Arch* 1999;434:315-23.
 57. Zandbelt MM, Wentink JRM, de Wilde PCM, et al. The synergistic value of focus score and IgA% score of sublabial salivary gland biopsy for the accuracy of the diagnosis of Sjögren's syndrome: a 10-year comparison. *Rheumatology (Oxford)* 2002;41:819-23.
 58. van Ginkel MS, Haacke EA, Bootsma H, et al. Presence of intraepithelial B-lymphocytes is associated with the formation of lymphoepithelial lesions in salivary glands of primary Sjögren's syndrome patients. *Clin Exp Rheumatol* 201;37:42-48.
 59. Haacke EA, Bootsma H, Spijkervet FKL, et al. FcRL4 + B-cells in salivary glands of primary Sjögren's syndrome patients. *J Autoimmu*. 2017;81:90-98.
 60. Ehrhardt GR, Hsu JT, Gartland L, et al. Expression of the immunoregulatory molecule FcRH4 defines a distinctive tissue-based population of memory B cells. *J Exp Med* 2005;202:783-91.
 61. Falini B, Tiaci E, Pucciarini A, et al. Expression of the IRTA1 receptor identifies intraepithelial and subepithelial marginal zone B cells of the mucosa-associated lymphoid tissue (MALT).

- Blood 2003;102:3684-92.
62. Falini B, Agostinelli C, Bigerna B, et al. IRTA1 is selectively expressed in nodal and extranodal marginal zone lymphomas. *Histopathology* 2012;61:930-41.
 63. Pijpe J, Meijer JM, Bootsma H, et al. Clinical and histologic evidence of salivary gland restoration supports the efficacy of rituximab treatment in Sjögren's syndrome. *Arthritis Rheum* 2009;60:3251-56.
 64. Ihrler S, Adam P, Guntinas-Lichius O, et al. Pattern recognition in the differential diagnosis of salivary lymphoepithelial lesions. *Pathologie* 2009;30:432-41.
 65. Salomonsson S, Rozell BL, Heimburger M, et al. Minor salivary gland immunohistology in the diagnosis of primary Sjögren's syndrome. *J Oral Pathol Med* 2008;38:282-88.
 66. Royer B, Cazals-Hatem D, Sibilia J, et al. Lymphomas in patients with Sjogren's syndrome are marginal zone B-cell neoplasms, arise in diverse extranodal and nodal sites, and are not associated with viruses. *Blood* 1997;90:766-75.
 67. Gasparotto D, De Vita S, De Re V, et al. Extrasalivary lymphoma development in Sjögren's syndrome: Clonal evolution from parotid gland lymphoproliferation and role of local triggering. *Arthritis Rheum* 2003;48:3181-86.
 68. Bende RJ, Aarts WM, Riedl RG, et al. Among B cell non-Hodgkin's lymphomas, MALT lymphomas express a unique antibody repertoire with frequent rheumatoid factor reactivity. *J Exp Med* 2005;201:1229-41.
 69. Martin T, Weber JC, Levallois H, et al. Salivary gland lymphomas in patients with Sjögren's syndrome may frequently develop from rheumatoid factor B cells. *Arthritis Rheum* 2000;43:908-16.
 70. Stott DI, Hiepe F, Hummel M, et al. Antigen-driven clonal proliferation of B cells within the target tissue of an autoimmune disease. The salivary glands of patients with Sjögren's syndrome. *J Clin Invest* 1998;102:938-46.
 71. William J, Euler C, Christensen S, et al. Evolution of autoantibody responses via somatic hypermutation outside of germinal centers. *Science* 2002;297:2066-70.
 72. Di Niro R, Lee S-J, Vander Heiden JA, et al. Salmonella Infection Drives Promiscuous B Cell Activation Followed by Extrafollicular Affinity Maturation. *Immunity* 2015;43:120-31.
 73. Bombardieri M, Barone F, Humby F, et al. Activation-Induced Cytidine Deaminase Expression in Follicular Dendritic Cell Networks and Interfollicular Large B Cells Supports Functionality of Ectopic Lymphoid Neogenesis in Autoimmune Sialoadenitis and MALT Lymphoma in Sjogren's Syndrome. *J Immunol* 2007;179:4929-38.
 74. Muramatsu M, Kinoshita K, Fagarasan S, et al. Class switch recombination and hypermutation require activation-induced cytidine deaminase (AID), a potential RNA editing enzyme. *Cell* 2000;102:553-63.
 75. Deutsch AJA, Agielsreiter A, Staber PB, et al. MALT lymphoma and extranodal diffuse large B-cell lymphoma are targeted by aberrant somatic hypermutation. *Blood* 2007;109:3500-04.
 76. Theander E, Vasaitis L, Baecklund E, et al. Lymphoid organisation in labial salivary gland biopsies is a possible predictor for the development of malignant lymphoma in primary Sjögren ' s syndrome. *Ann Rheum Dis* 2011;161:1363-68.
 77. Johnsen SJ, Berget E, Jonsson MV, et al. Evaluation of germinal center-like structures and B cell clonality in patients with primary Sjögren syndrome with and without lymphoma. *J Rheumatol* 2014;41:2214-22.
 78. Fragkioudaki S, Mavragani CP, Moutsopoulos HM. Predicting the risk for lymphoma development in Sjogren syndrome: An easy tool for clinical use. *Medicine (Baltimore)* 2016;95:e3766.
 79. Haacke EA, van der Vegt B, Vissink A, et al. Germinal centres in diagnostic labial gland biopsies of patients with primary Sjögren's syndrome are not predictive for parotid MALT lymphoma development. *Ann Rheum Dis* 2017;76:1781-84.
 80. Sène D, Ismael S, Forien M, et al. Ectopic germinal centre-like structures in minor salivary gland biopsy predict lymphoma occurrence in patients with primary Sjögren syndrome. *Arthritis*

- Rheumatol 2018;70:1481-88.
81. Baimpa E, Dahabreh IJ, Voulgarelis M, et al. Hematologic manifestations and predictors of lymphoma development in primary Sjögren syndrome: clinical and pathophysiologic aspects. *Medicine (Baltimore)* 2009;88:284-93.
82. Brito-Zerón P, Kostov B, Fraile G, et al. Characterization and risk estimate of cancer in patients with primary Sjögren syndrome. *J Hematol Oncol* 2017;10:90.
83. Yang Y, Chen L, Jia Y, et al. Monoclonal gammopathy in rheumatic diseases. *Clin Rheumatol* 2018;37:1751-62.
84. Carubbi F, Alunno A, Cipriani P, et al. Is minor salivary gland biopsy more than a diagnostic tool in primary Sjögren's syndrome? Association between clinical, histopathological, and molecular features: a retrospective study. *Semin Arthritis Rheum* 2014;44:314-24.
85. Risselada AP, Kruize AA, Goldschmeding R, et al. The prognostic value of routinely performed minor salivary gland assessments in primary Sjögren's syndrome. *Ann Rheum Dis* 2014;73:1537-40.
86. Delli K, Haacke EA, Ihrler S, et al. Need for consensus guidelines to standardise the assessment of germinal centres and other histopathological parameters in salivary gland tissue of patients with primary Sjögren's syndrome. *Ann Rheum Dis* 2016;75:e32.
87. Hillen MR, Barone F, Radstake TR, et al. Towards standardisation of histopathological assessments of germinal centres and lymphoid structures in primary Sjögren's syndrome. *Ann Rheum Dis* 2016;75:e31.
88. Nocturne G, Cornec D, Seror R, et al. Use of Biologics in Sjögren's Syndrome. *Rheum Dis Clin North Am* 2016;42:407-17.
89. Sambataro D, Sambataro G, Dal Bosco Y, et al. Present and future of biologic drugs in primary Sjögren's syndrome. *Expert Opin Biol Ther* 2017;17:63-75.
90. Meijer JM, Meiners PM, Vissink A, et al. Effectiveness of rituximab treatment in primary Sjögren's syndrome: a randomized, double-blind, placebo-controlled trial. *Arthritis Rheum* 2010;62:960-68.
91. Meiners PM, Vissink A, Kroese FGM, et al. Abatacept treatment reduces disease activity in early primary Sjögren's syndrome (open-label proof of concept ASAP study). *Ann Rheum Dis* 2014;73:1393-96.
92. Pijpe J, van Imhoff GW, Vissink A, et al. Changes in salivary gland immunohistology and function after rituximab monotherapy in a patient with Sjögren's syndrome and associated MALT lymphoma. *Ann Rheum Dis* 2005;64:958-60.
93. Mossel E, Delli K, van Nimwegen JF, et al. The parotid gland connection: ultrasound and biopsies in primary Sjögren's syndrome. *Ann Rheum Dis* 2018 Jul;77:e38.
94. Room J, Kalled SL, Cutler AH, et al. Association of BAFF/BLyS overexpression and altered B cell differentiation with Sjögren's syndrome. *J Clin Invest* 2002;109:59-68.
95. Schneider P, MacKay F, Steiner V, et al. BAFF, a novel ligand of the tumor necrosis factor family, stimulates B cell growth. *J Exp Med* 1999;189:1747-56.
96. Mariette X, Seror R, Quartuccio L, et al. Efficacy and safety of belimumab in primary Sjögren's syndrome: results of the BELISS open-label phase II study. *Ann Rheum Dis* 2015;74:526-31.
97. Seror R, Nocturne G, Lazure T, et al. Low numbers of blood and salivary natural killer cells are associated with a better response to belimumab in primary Sjögren's syndrome: results of the BELISS study. *Arthritis Res Ther* 2015;17:241.
98. De Vita S, Quartuccio L, Seror R, et al. Efficacy and safety of belimumab given for 12 months in primary Sjögren's syndrome: the BELISS open-label phase II study. *Rheumatology (Oxford)* 2015;54:2249-56.
99. Adler S, Korner M, Forger F, Huscher D, Caversaccio M-DD, Villiger PM. Evaluation of histological, serological and clinical changes in response to abatacept treatment of primary Sjögren's syndrome: A pilot study. *Arthritis Care Res (Hoboken)*. 2013;65(11):1862-1868.
100. Haacke EA, van der Vegt B, Meiners PM, et al. Abatacept treatment of patients with primary Sjögren's syndrome results in a decrease of germinal centres in salivary gland tissue. *Clin Exp*

- Rheumatol 2017;35(2):317-20.
101. Verstappen GM, Meiners PM, Corneth OBJ, et al. Attenuation of Follicular Helper T Cell-Dependent B Cell Hyperactivity by Abatacept Treatment in Primary Sjögren's Syndrome. *Arthritis Rheumatol* 2017;69:1850-61.
 102. Carubbi F, Cipriani P, Marrelli A, et al. Efficacy and safety of rituximab treatment in early primary Sjögren's syndrome: a prospective, multi-center, follow-up study. *Arthritis Res Ther* 2013;15:R172.
 103. Ciccia F, Giardina A, Rizzo A, et al. Rituximab modulates the expression of IL-22 in the salivary glands of patients with primary Sjögren's syndrome. *Ann Rheum Dis* 2013;72:782-83.
 104. Cornec D, Costa S, Devauchelle-Pensec V, et al. Blood and salivary-gland BAFF-driven B-cell hyperactivity is associated to rituximab inefficacy in primary Sjögren's syndrome. *J Autoimmun*. 2016;67:102-10.
 105. Devauchelle-Pensec V, Pennec Y, Morvan J, et al. Improvement of Sjögren's syndrome after two infusions of rituximab (anti-CD20). *Arthritis Rheum* 2007;57:310-17.
 106. Pers J-O, Devauchelle V, Daridon C, et al. BAFF-modulated repopulation of B lymphocytes in the blood and salivary glands of rituximab-treated patients with Sjögren's syndrome. *Arthritis Rheum* 2007;56:1464-77.
 107. Bowman SJ, Everett CC, O'Dwyer JL, et al. Randomized Controlled Trial of Rituximab and Cost-Effectiveness Analysis in Treating Fatigue and Oral Dryness in Primary Sjögren's Syndrome. *Arthritis Rheumatol* 2017;69:1440-50.
 108. Dass S, Bowman SJ, Vital EM, et al. Reduction of fatigue in Sjögren syndrome with rituximab: results of a randomised, double-blind, placebo-controlled pilot study. *Ann Rheum Dis* 2008;67:1541-44.
 109. Devauchelle-Pensec V, Mariette X, Jousse-Joulin S, et al. Treatment of Primary Sjögren Syndrome With Rituximab. *Ann Intern Med* 2014;160:233-42.
 110. St Clair EW, Levesque MC, Prak ETL, et al. Rituximab therapy for primary Sjögren's syndrome: an open-label clinical trial and mechanistic analysis. *Arthritis Rheum* 2013;65:1097-06.
 111. Zandbelt MM, de Wilde P, van Damme P, et al. Etanercept in the treatment of patients with primary Sjögren's syndrome: a pilot study. *J Rheumatol* 2004;31:96-01.
 112. Mariette X, Ravaut P, Steinfeld S, et al. Inefficacy of infliximab in primary Sjögren's syndrome: Results of the randomized, controlled trial of remicade in primary Sjögren's syndrome (TRIPSS). *Arthritis Rheum* 2004;50:1270-76.
 113. Seror R, Bootsma H, Saraux A, et al. Defining disease activity states and clinically meaningful improvement in primary Sjögren's syndrome with EULAR primary Sjögren's syndrome disease activity (ESSDAI) and patient-reported indexes (ESSPRI). *Ann Rheum Dis* 2016;75:382-89.
 114. Cornec D, Jousse-Joulin S, Costa S, et al. High-grade salivary-gland involvement, assessed by histology or ultrasonography, is associated with a poor response to a single rituximab course in primary Sjögren's syndrome: data from the TEARS randomized trial. *PLoS One* 2016;11:e0162787.
 115. Cornec D, Devauchelle-Pensec V, Mariette X, et al. Development of the Sjögren's Syndrome Responder Index, a data-driven composite endpoint for assessing treatment efficacy. *Rheumatology (Oxford)* 2015;54:1699-08.
 116. Cornec D, Costa S, Devauchelle-Pensec V, et al. Do high numbers of salivary gland-infiltrating B cells predict better or worse outcomes after rituximab in patients with primary Sjögren's syndrome? *Ann Rheum Dis* 2016;75:e33.
 117. Delli K, Haacke EA, Kroese FGM, et al. In primary Sjögren's syndrome high absolute numbers and proportions of B cells in parotid glands predict responsiveness to rituximab as defined by ESSDAI, but not by SSRI. *Ann Rheum Dis* 2016;75:e34.
 118. Pringle S, Wang X, Verstappen GMPJ, et al. Salivary Gland Stem Cells Age Prematurely in Primary Sjögren's syndrome. *Arthritis Rheumatol* 2019 Jan;7:133-42.
 119. Hočevár A, Ambrožič A, Rozman B, et al. Ultrasonographic changes of major salivary glands in primary Sjögren's syndrome. Diagnostic value of a novel scoring system. *Rheumatology* 2005;44:768-72.

120. Mossel E, Delli K, van Nimwegen JF, et al. Ultrasonography of major salivary glands compared with parotid and labial gland biopsy and classification criteria in patients with clinically suspected primary Sjögren's syndrome. *Ann Rheum Dis* 2017;76:1883-89.
121. Van Nimwegen JF, Mossel E, van Ginkel MS, et al. Addition of salivary gland ultrasound increases the feasibility of the ACR-EULAR classification criteria in primary Sjögren's syndrome [abstract]. *Clin Exp Rheumatol*. 2018;36(3):Suppl.112.
122. Cornec D, Jousse-Joulin S, Pers J-O, et al. Contribution of salivary gland ultrasonography to the diagnosis of Sjögren's syndrome: Toward new diagnostic criteria? *Arthritis Rheum* 2013;65:216-25.
123. Narayan AK, Baer A, Fradin J. Sonographic findings of IgG4-related disease of the salivary glands: Case report and review of the literature. *J Clin Ultrasound* 2018;46:73-77.
124. Law ST, Jafarzadeh SR, Govender P, et al. Comparison of Ultrasound Features of Major Salivary Glands in Sarcoidosis, Amyloidosis, and Sjögren's Syndrome. *Arthritis Care Res (Hoboken)* Epub ahead of print.



CHAPTER 10

Summary

SUMMARY

Sjögren's syndrome is a systemic autoimmune disease primarily affecting the salivary and lacrimal glands. The chronic inflammatory process in these glands is involved in the characteristic complaints of dry mouth and dry eyes. Many other organ systems, such as lung, kidneys and skin can be affected as well. For the diagnosis of pSS, a salivary gland biopsy is often taken. This biopsy takes a prominent place in the current American College of Rheumatology – European League against Rheumatism (ACR-EULAR) classification criteria. In these criteria a glandular biopsy is considered positive if the focus score (FS), calculated as the number of foci per 4 mm² glandular parenchyma, is ≥ 1 . The presence of lymphoepithelial lesions (LELs) and a relative decrease of $\leq 70\%$ IgA expressing plasma cells are other characteristic histopathological features of the glandular tissue, although they are not taken into account in the ACR-EULAR criteria. Furthermore, germinal centers (GCs) can be found in the salivary tissue of about a quarter of the pSS patients and is associated with more severe and active disease. In most centres a labial salivary gland biopsy is taken, but a parotid salivary gland biopsy can be used as an alternative. Besides its use in diagnosis and classification of pSS, salivary gland biopsies are increasingly used as an outcome measure in clinical trials. Pre-treatment and post-treatment biopsies give new insights in the pathogenesis of the disease. Although the importance of the salivary gland biopsy is recognized, the accurate assessment of these biopsies requires a standardized histopathological evaluation.

The cause of pSS is currently not fully known. It is thought that an initial trigger (e.g., a viral infection) leads to a breach of tolerance resulting in an inflammatory response in the salivary/lacrimal glands. The early inflammatory response in the salivary gland is dominated by T-cells followed by the influx of B-cells. Besides T- and B-cells, also other non-lymphoid cells are attracted to the inflamed salivary glands. Finally, all components for the formation of ectopic lymphoid are present even allowing the local generation of germinal centres. In 5-10% of the pSS patients, the hyperactivity of B-cells is reflected by the development of malignant non-Hodgkin's lymphomas (NHL). These lymphomas mostly occur in the parotid gland and are predominantly of the mucosa-associated lymphoid tissue (MALT) type.

Treatment of pSS is primarily symptomatic, relieving dryness complaints. With the emergence of disease-modifying anti-rheumatic drugs (DMARDs), treatment options have been extended. These DMARDs aim not only to relieve symptoms, but also to provide a (long lasting) systemic effect. Since not all pSS patients benefit from treatment with the same DMARD, it is crucial to find biomarkers to identify patients which will profit from treatment. This personalized medicine might aid in relieving pSS related complaints and preventing further disease progression. In this thesis the value of salivary gland histopathology in pSS patients for diagnosis and stratification, and as an outcome measure in treatment studies was described.

Thesis part 1: Salivary gland histopathology

In chapter 2 the applicability of the parotid gland biopsy is compared to the labial gland biopsy as well as that the surgical procedures for both biopsies are described. The current surgical procedure of a biopsy from the superficial lobe of the parotid gland has no reports of development of sialoceles or fistula. After this biopsy procedure, no permanent complications were observed and the level of post-operative pain is comparable to that of the labial gland biopsy. The histopathological evaluation of the biopsies is similar, and the diagnostic sensitivity and specificity of the biopsies are comparable. The parotid gland biopsy has certain advantages over the labial gland biopsy. It is possible to take more than once biopsies from the same gland. In this manner, disease progression can be monitored and treatment efficacy can be assessed. Furthermore, parotid gland biopsies make a direct comparison with other diagnostic results such as salivary flow, salivary scintigraphy and salivary gland ultrasound possible. Also, in the parotid gland biopsy an early, clinically not suspected, MALT lymphoma is fairly regular found in contrast to the labial gland biopsy.

In chapter 3a, we described that the manner in which GCs are histologically assessed differs greatly amongst studies. Detection of GCs is in need of a clear histological definition. Correct assessment of these structures is clinically relevant as the presence of GCs is linked to higher disease activity. In haematoxylin-eosin (H&E) stained sections, the presence of GCs may be overlooked due to small size or LELs may incorrectly be classified as GCs. Therefore, in chapters 3a and 3b we argue to stain for the transcription factor B-cell lymphoma (Bcl)-6 for the easy and proper identification of germinal centres in salivary glands of pSS patients. This transcription factor is expressed at high levels by germinal centre B-cells. In the study described in chapter 3c, we subsequently show that Bcl6 is indeed the most appropriated marker for correctly identifying GCs. On the contrary, assessment of GCs with CD21 leads to an overestimation of the number of GCs.

Thesis part 2: Germinal centres and MALT lymphoma in biopsies of primary Sjögren's syndrome patients

In the study described in chapter 4, the presence of FcRL4 expressing B-cells in the labial gland biopsies, parotid gland biopsies, and parotid gland MALT lymphoma of pSS patients was examined. First, we showed that almost all (97%) of the pSS associated parotid MALT lymphomas express FcRL4. FcRL4 expressing B-cells were also found in the salivary gland tissue of non-lymphoma pSS patients. Importantly, virtually all B-cells located between the epithelial cells of the striated ducts express FcRL4⁺, whereas only a small fraction of the periductal B-cells express this protein. Second, the study showed that these FcRL4⁺ B-cells are highly proliferative, are in close association with LELs. Third, their numbers are significantly higher in the parotid gland tissue compared to labial gland tissue. Their enrichment in the parotid glands may explain why MALT lymphomas in pSS patients

preferentially develop at this specific location. Last, this population of FcRL4⁺ B-cells can be targeted by rituximab which leads to restoration of the glandular striated ducts as demonstrated by the reduction and the severity of LELs after rituximab treatment.

In chapter 5 it is described that there is an association between presence of intraepithelial B-cells and formation of LELs in salivary gland tissue of pSS patients. In simultaneously taken labial and parotid gland biopsies, the presence and severity of LELs, and the number of B- and T-cells within the striated ducts were assessed. Within the striated ducts of non-SS sicca patients, T-cells were found, but B-cells (and LELs) were completely absent. In contrast, B-cells were found in the striated ducts of pSS patients, even in a low proportion of ducts without hyperplasia. When LELs are present, B-cells are usually present and they were concentrated in the areas of epithelial hyperplasia. The B-cell/T-cell ratio increased significantly with higher severity of LELs. These results are indicative for a cross-talk between B-cells and ductal epithelial cells in salivary gland tissue of pSS patients, leading to LEL formation.

In chapter 6a, a study is described in which retrospectively pre-lymphoma biopsies of pSS MALT lymphoma patients were compared with a matched control group with a long lymphoma free follow-up. Presence of GCs in biopsies, taken for the initial diagnosis of pSS, did not differ between these groups. Also the percentage of pre-lymphoma biopsies containing GCs was similar to the percentage of salivary gland biopsies with GCs of the general pSS population. Therefore, it was concluded that the presence of GCs in the labial gland biopsy of pSS patients is not predictive for parotid MALT lymphoma development. In chapter 6b, it was further argued that presence of GCs in labial gland biopsies is a reflection of high disease activity (EULAR Sjögren's Syndrome Disease Activity Index: ESSDAI) and not a prerequisite for MALT lymphoma development because many pSS patients with GCs in the salivary gland biopsy will not develop malignant lymphomas. Another indication of high disease activity is a monoclonal gammopathy. In 4-22% of pSS patients, a monoclonal gammopathy is present. Moreover, monoclonal gammopathy is a known risk factor for lymphoma development. Finally, disease activity in pSS patients varies over time, possibly influencing the change of finding GCs in the salivary gland biopsy.

Thesis part 3: Histopathological changes after biological treatment

In chapter 7a, the histopathological changes in parotid gland biopsies of pSS patients after treatment with rituximab are presented. After rituximab treatment, the total number of lymphocytes (CD45⁺), the number of B-cells, severity and number/mm² of LELs and GCs / mm² in the parotid gland parenchyma declined as compared to the placebo treated group. The number of T-cells/mm² parotid gland parenchyma did, however, not change. Besides the number of LELs, the severity of LELs was also reduced. This indicates that elimination of B-cells from the parotid gland allows striated ducts to restore. Furthermore, comparing the pre-treatment characteristics of clinical responders (defined as decrease in ESSDAI

≥ 3 points) with non-responders, the median number of CD20⁺ B-cells/mm² parenchyma at baseline was significantly higher in responders. In other words, the baseline number of B-cells/mm² may serve as an indicator of the response to rituximab treatment. This allows for identification of patients who can benefit from rituximab treatment (personalized treatment). In the study described in chapter 7b, the proportion of B-cells (B-cell/B- + T-cell ratio) was calculated instead of the number of B-cells/mm² parotid gland parenchyma. The results showed that clinical responders (ESSDAI ≥ 3 points) also had a significantly higher B-cell proportion than non-responders. In other words, B-cell proportions presumably also predict responsiveness to rituximab treatment. Using the SSRI (Sjögren's Syndrome Response Index) instead of the ESSDAI, the number of baseline B-cells/mm² did not differ between responders and non-responders.

In chapter 8, we showed that treatment of pSS patients with abatacept results in a decrease of the number of GCs/mm² parotid gland parenchyma and in an increase in the number of IgM positive plasma cells/mm² parotid gland. The FS, LELs/ mm², area of lymphocytic (CD45⁺) infiltrate, amount of CD21⁺ networks of FDCs, and numbers of CD3⁺ T-cells or CD20⁺ B-cells did not change. The reduction of GCs in parotid gland tissue of pSS patients is probably due to inhibition of local T-cell dependent B-cell activation and a diminished generation of (activated) follicular helper T-cells. The increase of (short-lived) IgM positive plasma cells might occur in a T-cell independent manner. The numbers of IgA and IgG expressing plasma cells did not change after abatacept treatment.

To conclude, salivary gland biopsies play an important role in the diagnosis and classification of pSS as well as in predicting disease severity, assessing treatment efficacy and stratification of patients. More accurate, standardized and preferably digitized analyses of salivary gland histopathology in treatment studies could aid in understanding the pathophysiology of pSS.





APPENDIX

Nederlandse samenvatting
Dankwoord
Curriculum vitae
List of publications



APPENDIX

Nederlandse samenvatting



NEDERLANDSE SAMENVATTING

Het primaire syndroom van Sjögren (pSS) is een systemische auto-immuunziekte waarbij vooral de speekselklieren en traanklieren worden aangetast met een droog gevoel van de mond en ogen als gevolg. Een andere veel voorkomende klacht is moeheid. Daarnaast kunnen in tal van andere orgaansystemen klachten ontstaan, zoals in de longen, nieren en huid.

Het chronische ontstekingsinfiltraat in de speekselklieren is betrokken bij de karakteristieke droogheidsklachten van de mond en ogen. In de speekselklieren zijn de ontstekingsinfiltraten gelokaliseerd rondom de afvoergangen. Een dergelijk ontstekingsinfiltraat wordt een focale lymfocyttaire sialoadenitis genoemd. Hierbij zijn er meerdere foci (groepen van ≥ 50 lymfocyten) aanwezig. De infiltratie van deze lymfocyten in het epitheel van de afvoergangen leidt tot hyperplasie van dit epitheel en vorming van lymfo-epitheliale laesies (LELs).

Voor de diagnose van pSS wordt vaak een speekselklierbiopt genomen. Dit biopt neemt een belangrijke positie in binnen de American College of Rheumatology – European League against Rheumatism (ACR-EULAR) classificatie criteria. In deze criteria wordt een speekselklierbiopt als positief beschouwd wanneer de focusscore (FS), welke wordt berekend door het aantal foci per 4 mm² speekselklierparenchym, groter of gelijk is aan 1. De aanwezigheid van LELs en een relatieve afname van $\leq 70\%$ IgA positieve plasmacellen in het speekselklierweefsel zijn andere karakteristieke histopathologische kenmerken van pSS. Deze laatste twee kenmerken zijn momenteel niet geïncorporeerd in de ACR-EULAR classificatie criteria. Daarnaast worden kiemcentra (KC) gevonden in het speekselklierweefsel van ongeveer een kwart van de pSS patiënten. De aanwezigheid van KC is geassocieerd met een ernstiger en actievere ziektestatus van pSS. In de meeste ziekenhuizen wordt een biopt van de lipspeekselklieren genomen. Een biopt van de glandula parotis (oorspeekselklier) vormt een goed alternatief. Naast de rol van het speekselklierbiopt in de diagnose en classificatie van pSS patiënten kunnen speekselklierbiopten worden gebruikt als (secundaire) uitkomstmaat in klinische studies. Het vergelijken van biopten voor en na de behandeling geeft nieuwe inzichten in de pathogenese van de ziekte.

Het belang van speekselklierbiopten wordt erkend, maar de histopathologische beoordeling van de biopten behoeft standaardisatie. Ondanks dat de definitie van de FS helder is, blijkt de manier waarop de FS wordt beoordeeld te verschillen tussen laboratoria. Een gevolg hiervan is dat de interpretatie of een speekselklierbiopt als positief of negatief moet worden beschouwd, kan verschillen.

De oorzaak van pSS is momenteel niet precies bekend. Er wordt gedacht dat een initiële trigger (zoals bijvoorbeeld een virale infectie) kan leiden tot een verlies van immunologische tolerantie resulterend in een ontstekingsreactie in de speekselklieren en traanklieren. De beginnende ontstekingsreactie in de speekselklieren wordt gedomineerd

door T-cellen, gevolgd door een influx van B-cellen. Naast deze T-cellen en B-cellen worden ook andere non-lymfoïde cellen aangetrokken naar de ontstoken klier. Uiteindelijk zijn alle componenten in de speekselklier aanwezig voor de vorming van ectopische KC. Bij pSS zijn de B-cellen hyperactief. Deze hyperactiviteit van B-cellen leidt in 5-10% van de pSS patiënten tot de ontwikkeling van een maligne non-Hodgkin's lymfoom (NHL). Deze lymfomen komen met name voor in de parotis en zijn overwegend van het slijmvlies-geassocieerd lymfoïde weefsel (MALT) subtype.

De behandeling van pSS is momenteel nog steeds primair symptomatisch. Met de komst van 'disease-modifying anti-rheumatic drugs' (ziekteverloop beïnvloedende geneesmiddelen tegen reuma) of DMARDs komen er meer behandelopties. Met name biologische DMARDs worden steeds meer ontwikkeld. DMARDs zijn niet alleen gericht op het verlichten van de symptomen, maar tevens om een langdurig systemisch effect te bewerkstelligen. Aangezien niet alle pSS patiënten baat hebben bij behandeling met dezelfde DMARD is het van groot belang om biomarkers te vinden om patiënten te kunnen identificeren die baat hebben bij behandeling. Deze zogenaamde gepersonaliseerde geneeskunde kan helpen in het verlichten van pSS gerelateerde klachten en bij het voorkomen van verdere ziekteprogressie.

In dit proefschrift wordt de waarde van de histopathologie van speekselklierbipten bij pSS patiënten voor 1) de diagnose, 2) stratificatie van patiënten en 3) uitkomstmaat bij klinische studies beschreven.

Deel 1: Histopathologie van het speekselklierbipt

In het review van **hoofdstuk 2** wordt het parotisbipt vergeleken met het lipbipt en worden de chirurgische procedures voor het nemen van beide bipten beschreven. In de meeste ziekenhuizen wordt een lipbipt genomen. Het parotisbipt vormt echter een goed alternatief. Na het nemen van het parotisbipt zijn, in tegenstelling tot na het nemen van een lipbipt, geen permanente complicaties (sensibiliteitsstoornissen) gedocumenteerd. De door de patiënt ervaren postoperatieve pijn bij een parotisbipt is vergelijkbaar met de postoperatieve pijn van het lipbipt. De histopathologische evaluatie en de specificiteit van beide speekselklierbipten zijn gelijk. Het parotisbipt heeft echter enkele voordelen ten opzichte van het lipbipt. Van de glandula parotis kunnen herhaalde bipten uit dezelfde speekselklier worden genomen, terwijl in geval van een bipt van de lipspeekselklieren telkens nieuwe speekselkliertjes uit de lip moeten worden verwijderd. Hierdoor kan, bij een parotisbipt, het ziekteverloop nauwkeuriger worden gemonitord en de effectiviteit van behandelingen worden onderzocht. Tevens maakt het parotisbipt het mogelijk om een directe vergelijking met andere diagnostische testen van dezelfde speekselklier te maken, zoals speekselvloed, speekselklierscintigrafie en echografie van de speekselklier. Als laatste, in het parotisbipt wordt met enige regelmaat een MALT lymfoom aangetroffen, zonder dat hiervoor een klinische verdenking was. Dit in tegenstelling tot het lipbipt.

In **hoofdstuk 3a** wordt beschreven dat de histopathologische manier waarmee KC worden aangetoond in de speekselklierbiopten sterk verschilt tussen studies. Helaas worden ook incorrecte methodes toegepast, waardoor de betrouwbaarheid en vergelijkbaarheid van studies wordt verlaagd. Voor de detectie van KC is er zodoende internationaal behoefte aan een duidelijke histopathologische definitie. De correcte beoordeling van deze structuren is klinisch relevant aangezien de aanwezigheid van KC is geassocieerd met een hogere ziekteactiviteit. In coupes van speekselklierbiopten gekleurd met haematoxyline-eosine (HE) kan de aanwezigheid van kleine KC gemakkelijk worden gemist en kunnen LELs foutief geïnterpreteerd worden als KC. Daarom wordt in **hoofdstuk 3a** en **3b** beargumenteerd om naast de standaard HE kleuring tevens te kleuren voor de transcriptiefactor B-cel lymfoom -6 (Bcl-6). De transcriptiefactor Bcl-6 komt sterk tot expressie in kiemcentrum B-cellen. Kleuring met Bcl-6 zorgt voor een makkelijke en juiste identificatie van KC in de speekselklieren van pSS patiënten. In de studie beschreven in **hoofdstuk 3c** wordt bevestigd dat Bcl-6 de meest geschikte marker is voor het correct identificeren van KC. Tevens wordt in dit hoofdstuk aangetoond dat identificatie van KC door middel van een CD21 kleuring leidt tot een overschatting van het aantal KC. Dit komt omdat CD21 niet alleen op kiemcentrum B-cellen tot expressie gebracht wordt, maar ook door folliculair dendritische cellen. Een netwerk van deze folliculair dendritische cellen kan in de foci aanwezig zijn zonder dat er daadwerkelijk sprake is van een (Bcl6⁺) KC.

Deel 2: Kiemcentra en MALT lymfomen in speekselklierbiopten van patiënten met het primaire syndroom van Sjögren

MALT lymfomen in het algemeen brengen het eiwit FcRL4 tot expressie, net als een klein aantal B-cellen die geassocieerd zijn met slijmvliezen. Om die reden hebben we onderzocht of dergelijke B-cellen ook aanwezig zijn in de MALT lymfomen in de glandula parotis van pSS patiënten. Daarnaast bekeken we of deze FcRL4⁺ B-cellen aanwezig waren in de speekselklierbiopten van pSS patiënten. In de in **hoofdstuk 4** beschreven studie wordt de aanwezigheid van FcRL4⁺ B-cellen in zowel het parotis MALT lymfoom als parotisbiopt en lipbiopt van pSS patiënten bevestigd. Als eerste lieten we zien dat bijna alle (97%) van de pSS geassocieerde MALT lymfomen FcRL4 tot expressie brengen. FcRL4⁺ B-cellen werden ook gevonden in het speekselklierweefsel van pSS patiënten zonder lymfoom. Hierbij lagen vrijwel alle FcRL4⁺ B-cellen tussen de epitheliale cellen van de uitvoergangen die LELs vormen. Slechts een kleine fractie van de B-cellen in de periductale foci bracht dit eiwit tot expressie. De studie toonde aan dat FcRL4⁺ B-cellen een hoge delingsactiviteit hebben en sterk geassocieerd zijn met LELs in het speekselklierweefsel. Omdat MALT lymfomen bij pSS ook FcRL4 tot expressie brengen en vrijwel altijd geassocieerd zijn met LELs, zou het goed kunnen dat de MALT lymfomen afkomstig zijn van deze FcRL4⁺ B-cellen. Het aantal FcRL4⁺ B-cellen in het parotisklierweefsel is significant hoger dan het aantal FcRL4⁺ B-cellen in het lipbiopt. Deze verrijking in het parotisklierweefsel kan verklaren

waarom MALT lymfomen in pSS patiënten zich bij voorkeur ontwikkelen in de glandula parotis. De populatie FcRL4⁺ B-cellen reageert op behandeling met rituximab waardoor de uitvoergangen in het klierweefsel kunnen herstellen. Dit herstel is zichtbaar in de reductie van het aantal LELs en de afname van de ernst van de LELs na rituximab behandeling.

In **hoofdstuk 5** wordt de associatie tussen B-cellen die in het epitheel liggen van de uitvoergangen en de formatie van LELs in het speekselklierweefsel van pSS patiënten beschreven. In gelijktijdig genomen biopten van de lipspeekselklieren en de glandula parotis werd de aanwezigheid van LELs, de ernst van de LELs en het aantal T- en B-cellen in de dwarsgestreepte ducten onderzocht. Dit werd onderzocht in zowel gezonde controles, patiënten met sicca klachten die niet volledig aan de diagnose pSS voldoen (non-SS sicca patiënten) en pSS patiënten. In de uitvoergangen van non-SS sicca patiënten werden wel T-cellen gevonden, maar geen B-cellen en ook geen LELs. In tegenstelling daarmee werden er wel B-cellen gevonden in de uitvoergangen van pSS patiënten, zelfs in een gering aantal ducten zonder proliferatie van het epitheel. Als er LELs aanwezig waren in het biopt, dan waren er meestal ook B-cellen aanwezig in de uitvoergangen, met name in de gebieden waar proliferatie van de epitheelcellen van de uitvoergangen is. De B/T-cel ratio werd significant hoger (meer B-cellen) met de ernst van de LELs. Deze resultaten geven een indicatie dat er een 'crosstalk' bestaat tussen intra-epitheliale B-cellen en de epitheelcellen van de uitvoergangen in het speekselklierweefsel van pSS patiënten. Deze crosstalk kan leiden tot de formatie van LELs.

Eerder werd er gepubliceerd dat KC in het lipbiopt een risicofactor zijn voor het ontwikkelen van lymfomen bij pSS patiënten. Zodoende wordt in **hoofdstuk 6a** een retrospectieve studie gepresenteerd waarin pre-lymfoom lipbiopten van pSS MALT lymfoom patiënten werden vergeleken met lipbiopten van een gematchte controle groep van pSS patiënten met een lange lymfoomvrije follow-up. De aanwezigheid van KC in de lipbiopten, welke waren genomen voor de initiële diagnose van pSS, verschilde niet tussen deze twee groepen. Het percentage van de pre-lymfoom lipbiopten waarin KC werden gevonden was tevens vergelijkbaar met het percentage van lipbiopten met KC in de algemene populatie pSS patiënten. Daarom werd geconcludeerd dat de aanwezigheid van KC in de lipbiopten van pSS patiënten niet voorspellend is of er in de toekomst een MALT lymfoom zal ontwikkelen. In **hoofdstuk 6b** wordt vervolgens beargumenteerd dat de aanwezigheid van KC in de lipbiopten een reflectie is van een hoge ziekteactiviteit (EULAR Sjögren's Syndrome Disease Activity Index: ESSDAI) en niet per se leidt tot het ontwikkelen van een MALT-lymfoom. Ongeveer een kwart van de pSS patiënten heeft KC in het lipbiopt. Dit percentage is veel hoger dan het percentage patiënten (5-10%) dat een maligne lymfoom ontwikkeld. Als laatste, de ziekteactiviteit in pSS patiënten varieert met de tijd, waardoor de kans op het vinden van een KC in het speekselklierbiopt wordt beïnvloed. De ziekte kan (tijdelijk) opvlammen waarbij de ziekteactiviteit hoog is. De kans op het vinden van KC in het speekselklierbiopt kan op zo'n moment hoger zijn.

Deel 3: histopathologische veranderingen na behandeling met biologicals.

Hyperactiviteit van B-cellen speelt een belangrijke rol in pSS. Het uitschakelen van B-cellen door middel van rituximab vormt gezien deze hyperactiviteit een logische behandelstap bij pSS patiënten. Rituximab grijpt aan op het eiwit CD20 dat op B-cellen zit. De binding van rituximab aan dit eiwit resulteert in de celdood van de B-cellen. In **hoofdstuk 7a** worden de histopathologische veranderingen in het parotisbiopt van pSS patiënten na behandeling met rituximab gepresenteerd. Na behandeling met rituximab neemt het totaal aantal van lymfocyten (CD45⁺), het aantal B-cellen/mm², en de ernst en het aantal LELs/mm² en KC/mm² in het parotisparenchym af in vergelijking met de placebo groep. Het aantal T-cellen/mm² parotisparenchym veranderde echter niet. Naast het aantal LELs nam ook de ernst van de LELs af. Dit impliceert dat de uitvoergangen in de glandula parotis herstellen na eliminatie van de B-cellen door rituximab. Verder was aantal CD20⁺ B-cellen/mm² parotisparenchym voor de behandeling (baseline) significant hoger in responders op rituximab in vergelijking met non-responders. Een responder is gedefinieerd als een afname in ESSDAI ≥ 3 punten. Met andere woorden, het aantal aanwezige B-cellen/mm² parotisweefsel, voorafgaand aan de behandeling, kan fungeren als indicator voor de respons op rituximab behandeling. Dit geeft mogelijkheden om te identificeren welke pSS patiënten baat hebben bij een behandeling met rituximab en welke patiënten niet. In de studie beschreven in **hoofdstuk 7b** wordt de proportie van B-cellen (B-cellen/ B-cellen + T-cellen ratio) berekend in plaats van het aantal B-cellen/mm² parotisparenchym. De resultaten toonden dat de klinische responders tevens significant hogere B-cel proporties hadden in vergelijking met de placebogroep. Met andere woorden, ook B-cel proporties kunnen mogelijk worden gebruikt om de respons op rituximab te voorspellen. Het gebruik van de SSRI (Sjögren's Syndrome Response Index) in plaats van de ESSDAI, om responders van niet-responders te onderscheiden, resulteerde in een vergelijkbaar aantal B-cellen/mm² parenchym bij responders en non-responders. Het gebruik van verschillende meetmethoden (SSRI of ESSDAI) om de respons op een behandeling te meten kan zodoende leiden tot verschillen in uitkomsten.

Abatacept is een biologische DMARD welke de T-cel activatie remt. In **hoofdstuk 8** laten we zien dat de behandeling van pSS patiënten met abatacept resulteert in een afname van het aantal KC/mm² parotisparenchym. Daarnaast was er een stijging zichtbaar in het aantal IgM⁺ plasmacellen/mm² parotisparenchym. De focusscore, het aantal LELs/mm², de oppervlakte van het lymfocyttaire (CD45⁺) infiltraat, het aantal CD21⁺ netwerken van folliculair dendritische cellen en het aantal van T-cellen en B-cellen veranderde niet. De afname van KC in het parotisweefsel na behandeling kan komen door de inhibitie van T-cel afhankelijke B-cel activatie (welke nodig is voor KC vorming). De toename in (kortlevende) IgM⁺ plasmacellen kan voortvloeien uit een T-cel onafhankelijke activatie van de B-cellen. De aantallen van IgA⁺ en IgG⁺ plasmacellen veranderde niet na behandeling met abatacept, aangezien deze cellen voor het grootste gedeelte langlevend zijn.

Samenvattend, speekselklierbiopten spelen een belangrijke rol in het diagnosticeren en classificeren van pSS patiënten. Speekselklierbiopten zijn bruikbaar in het voorspellen van de ernst van de ziekte, het beoordelen van de effectiviteit van de gegeven behandeling en de stratificatie van pSS patiënten. Preciezere gestandaardiseerde en bij voorkeur gedigitaliseerde analyses van het speekselklierbiopt in behandelstudies kunnen tevens bijdragen aan het ontrafelen van de pathofysiologie van pSS.



APPENDIX

Dankwoord

DANKWOORD

"It takes a village to create a thesis."

Zonder een heel team van inspirerende, enthousiaste en gedreven mensen zou dit proefschrift nog steeds niet af zijn, laat staan ooit tot stand zijn gekomen. Hiervoor wil ik graag een aantal mensen persoonlijk bedanken.

Allereerst wil ik alle patiënten bedanken die betrokken zijn geweest bij de onderzoeken gepresenteerd in dit proefschrift.

Veel dank ben ik verschuldigd aan mijn promotoren, die mij de kans hebben gegeven om dit promotietraject te volgen. Jullie hebben gezorgd voor een goede begeleiding, waarbij ruimte werd geboden onderzoek te verrichten waarbij histopathologie een belangrijke rol speelt.

Beste Prof. dr. F.G.M. Kroese, beste Frans. Bedankt dat jij mijn eerste promotor wilde zijn. Jaren geleden ontmoette ik je als student-assistent bij de practica histologie en celbiologie. Tijdens mijn opleiding tot patholoog kwam ik opnieuw bij jou terecht voor mijn promotieonderzoek. Jouw ADHD-achtige enthousiasme en eindeloze stroom aan nieuwe ideeën is ongeëvenaard. Voeg hierbij een ongelooflijke portie kennis over immunologie en het syndroom van Sjögren en er kunnen volgens mij nog wel honderd proefschriften worden geschreven. Jouw kunst om een aller-aller-laatste versie van een manuscript toch nog van nieuw commentaar en xx-aantal nieuwe verbeterpunten te voorzien blijft uiterst fascinerend. Het stimuleren van zelf nadenken en zelf richting geven aan het onderzoek heb ik altijd als een positieve eigenschap in jou gewaardeerd.

Prof. dr. H. Bootsma, beste Hendrika. Jij hebt de bijzondere gave om op een natuurlijke manier mensen te verbinden. Op congressen beweeg jij je soepel van de ene naar de andere onderzoeksgroep om wetenschappelijk bij te te praten en om het Sjögren Expertisecentrum van het UMCG op de kaart te zetten. Jij bent niet bang om het gesprek aan te gaan en dat is een van de vele eigenschappen die ik in jou waardeer. Ik hoop dat onze wegen elkaar nog vaak zullen kruisen in de toekomst.

Prof. dr. A. Vissink, beste Arjan. Binnen een paar dagen had jij gegarandeerd een manuscript of hoofdstuk nagekeken. Geen enkele spel-, of typefout ontging jouw kritische blik en met het grootste gemak werden er her en der nog wat woorden geschrapt. Jouw positieve instelling, je enthousiasme en jouw "het kan wel" hebben mij vele malen een glimlach op het gezicht gebracht tijdens dit promotietraject.

Dr. B. van der Vegt, beste Bert. Na honderden parotis,- en lipbiopten samen beoordeeld te hebben, durf ik te stellen dat wij het best gekalibreerde stel pathologen van Sjögren-biopten zijn. Jouw praktische insteek met een vleugje droge humor hebben mij veel geholpen in het onderzoek. Bedankt voor alle uren aan de microscoop samen.

Prof. dr. Ph. Kluin, beste Philip. Bij het opstarten van mijn promotieonderzoek hebben wij veel MALT lymfomen samen bekeken. Jouw expertise in lymfomen, jouw precisie en kennis van verschillende manieren om histologische coupes te scoren hebben mij gedurende het gehele onderzoek geholpen. Jij inspireerde mij altijd om meer te willen leren met de onvergetelijke uitspraak: "basiskennis Erlin, basiskennis!". Dank je wel dat je mij zoveel geleerd en geholpen hebt.

De leden van de beoordelingscommissie, Prof. dr. C.J.M. van Noesel, Prof. dr. N.A. Bos en Prof. dr. N. de Vries, wil ik bedanken voor het beoordelen van het uiteindelijke manuscript in deze bijzondere en drukke tijden.

Mijn paranimfen, drs. H.D. Hoving, lieve Hilde. Wat waren wij groen als gras toen wij aan ons promotieonderzoek en opleiding begonnen. Naast het elkaar helpen met coupes kleuren op het lab, elkaar moed inspreken dat het echt allemaal wel goed komt, het bespreken van vele frustratie-momenten, hebben we ook veel lol gehad. Jij weet de schoonheid van dingen in het leven te waarderen; van "chirurgisch" gemaakte kokosnoottassen met Thaise inspiratie tot chillen op een kleedje in jouw achtertuin. Ik ben dankbaar voor jouw vriendschap.

Dr. P.M. Meiners, lieve Petra. Jij bent de allereerste gepromoveerde vrouwelijke kaakchirurg opgeleid in Groningen. Een beter voorbeeld kan ik me niet wensen. Als geen ander begreep jij wat het doen van onderzoek naast een opleiding en naast het moederschap betekende. Vele malen heb jij mij ondersteund als ik het even niet meer wist. Samen delen we een liefde voor Japan en (te) veel kletsen. Dank je wel voor jouw vriendschap.

Prof. dr. H. Hollema, Dr. W.F.A. den Dunnen en Dr. G. Kats, beste Harry, Wilfred en Gursah, mijn opleiders pathologie in het UMC Groningen. Bedankt dat jullie het mogelijk hebben gemaakt om naast mijn opleiding tot patholoog promotieonderzoek te doen. Dankzij jullie is uiteindelijk zowel mijn opleiding tot patholoog als mijn promotieonderzoek tot een goed einde gebracht.

Alle collega's en mede-onderzoekers van het Sjögren-team wil ik bedanken voor de fijne samenwerking. Beste Prof. dr. F.K.L. Spijkervet, beste Fred, zonder de door jouw genomen speekselklierbiopten zou dit proefschrift een stuk dunner zijn. Dank aan al mij mede (voormalige) PhDs en postdocs, beste Gwenny, Jolien, Konstantina, Sarah, Esther, Robin, Marthe, Taco, Xiaoyan, Uzma, Rada en Jacolien. Bedankt voor jullie hulp en expertise. Jullie brachten allemaal kennis op verschillende terreinen mee en van jullie allemaal heb ik veel geleerd. Daarnaast bedankt voor alle gezellige en leuke momenten samen. Beste Annie en Silvia, jullie labhulp en input voor verbetering van technieken was van grote waarde. Beste Greetje, Dr. A.J. Stel, beste Alja, Dr. E Brouwer, beste Liesbeth en Dr. S. Arends, beste Suzanne, dank voor jullie steun bij de klinische onderzoeken.

Mijn dank gaat tevens uit naar de pathologen in het UMCG, beste Prof. W. Timens, Prof. A. Suurmeijer, Dr. A. Diepstra, Dr. G.F.H. Diercks, Drs. J.J. Doff, Dr. E.W. Duiker, Dr. B.M. van Hemel, Dr. M. van den Heuvel, Drs. A. Karrenbeld, Prof. A.S.H. Gouw, Drs. S. Rosati, Drs. M.H. Schoots, Dr. A. Timmer en Drs. N. Werner en alle (voormalige) AIOS pathologie, beste Mieke, Evert, Jan-Lukas, Timco, Nicolle, Karin, Marcel, Rowie, Marjolein, Atefeh, Karen, Callista, Melvin, Astrid, Indy, Claire, Marloes, Girste en vele anderen. Dank voor al jullie steun en gezelligheid. En ja, loempia-vrijdag mis ik nog steeds.

Veel dank aan alle collega's van het pathologie-lab in het UMCG, beste Edwin, Manuela, Annelies, Carina, Karine, Jelle, Marleen, Tom, Henk, Ploni, Karen, Lilo, Claudia, Dicky, Monica, Kim, Fiona, Erik, Maaïke, Anita en Marco. Dank voor het snijden en kleuren van duizenden coupes. Jullie inspanning is enorm geweest. Beste Marian, dank voor jouw hulp bij het handmatig kleuren en scannen van vele coupes. Eentonige werk is een stuk leuker in goed gezelschap. Beste Ellen, dank je wel voor de kaarten die je stuurde en dat je altijd tijd had voor een praatje. Het ga je goed.

Lieve Papa, bedankt voor al jouw liefde en steun. Vele uren heb jij op de kinderen gepast zodat ik nog even 's avonds kon werken. En ondanks dat ik allang volwassen ben vraag jij nog altijd bezorgd of ik wel goed op mezelf pas. Het komt goed pap. Lieve Marnix, lief broertje, eindelijk kun je in alle rust lezen wat ik nou al die jaren heb gedaan. Zal ik, in navolging van papa, vragen of je dit boek leest voor mijn verjaardag? Ondanks onze vele verschillen weet ik dat jij er altijd voor mij zult zijn. Dank hiervoor. Lieve tantes, lieve Astrid en Ylene, jullie hebben mij altijd liefdevol ondersteund en geholpen. Jullie levenservaring en luisterend oor maken het gemis van een moeder iets minder erg.

Aan mijn lieve vriendinnen, lieve Marianne en Inge, straks heb ik zeeën van tijd voor jullie! De meidenweekenden met jullie en de kids vind ik altijd heerlijk. Heerlijk theeleuten en genieten.

Lieve Marcel, wij zijn elkaars verdiende loon. Dank je wel voor alle ruimte die jij mij hebt gegeven om het onderzoek af te ronden. Jij laat mij vrij in mijn doen en laten en begrijpt dat ik mijn eigen passies volg. Je warmte en liefde zijn voor mij altijd een veilige haven om naar thuis te komen. Ik kijk uit naar onze gezamenlijke toekomst in 1 huis.

Lieve Yuki, lieve Jesse en lieve Baby-girl, jullie geven mijn leven de mooiste kleuren van de regenboog. Ik ben dankbaar dat ik jullie moeder mag zijn en al jullie warme kusjes en knuffels mag ontvangen.



APPENDIX

Curriculum vitae

CURRICULUM VITAE



Engel Astrid (Erlin) Haacke was born on August 2nd 1983 in Almelo, The Netherlands. After finishing secondary school in 2001 at the “Het Erasmus” in Almelo she started the study of Medical Biology at the University of Groningen. After completing her Bachelor of Medical Biology and Behavioural and Neurosciences, she switched in 2004 to the study of Medicine, also at the University of Groningen. After obtaining her medical degree (MD) in 2010, she started her pathology residency at the department of Pathology and Medical Biology at the University Medical Center Groningen. This work was combined with her work as a PhD candidate under the guidance of Prof. dr. FGM Kroese, Prof. dr. H Bootsma, Prof. dr. A Vissink and Dr. B van der Vegt. In 2020 she finished her training as a pathologist and started working as a locum pathologist at the department of pathology at Gelre Ziekenhuizen at Apeldoorn. From July 2020 she will continue her career as a pathologist at Pathologie Friesland with special emphasis on gastrointestinal pathology, dermatopathology and urogenital pathology.



APPENDIX

List of publications

LIST OF PUBLICATIONS

- Verstappen GM, Ice JA, Bootsma H, Pringle S, **Haacke EA**, de Lange K, van der Vries GB, Hickey P, Vissink A, Spijkervet FKL, Lessard CJ, Kroese FGM. Gene Expression Profiling of Epithelium-Associated FcRL4⁺ B-Cells in primary Sjögren's syndrome reveals a pathogenic signature. *J Autoimmun.* 2020 [Epub ahead of print].
- van Nimwegen JF, Mossel E, van Zuiden GS, Wijnsma RF, Delli K, Stel AJ, van der Vegt B, **Haacke EA**, Olie L, Los LI, Verstappen GM, Pringle SA, Spijkervet FKL, Kroese FGM, Vissink A, Arends S, Bootsma H. Abatacept treatment for patients with early active primary Sjögren's syndrome: a single-centre, randomised, double-blind, placebo-controlled, phase 3 trial (ASAP-III study). *The Lancet Rheumatology.* 2020;2:e153-e163.
- Bende RJ, Janssen J, Beentjes A, Wormhoudt TAM, Wagner K, **Haacke EA**, Kroese FGM, Guikema JE, van Noesel CJM. Salivary gland MALT lymphomas of Sjögren's syndrome patients in majority express rheumatoid factors affinity-selected for IgG. *Arthritis Rheumatol.* 2020 [Epub ahead of print].
- Nakshbandi U, **Haacke EA**, Bootsma H, Vissink A, Spijkervet FKL, van der Vegt B, Kroese FGM. Bcl6 for identification of germinal centres in salivary gland biopsies in primary Sjögren's syndrome. *Oral Dis.* 2020;26:707-710.
- van Ginkel MS, **Haacke EA**, Bootsma H, Arends S, van Nimwegen JF, Verstappen GM, Spijkervet FKL, Vissink A, van der Vegt B, Kroese FGM. Presence of intraepithelial B-lymphocytes is associated with the formation of lymphoepithelial lesions in salivary glands of primary Sjögren's syndrome patients. *Clin Exp Rheumatol.* 2019; Suppl 118(3):42-48.
- Graver JC, Boots AMH, **Haacke EA**, Diepstra A, Brouwer E, Sandovici M. Massive B-Cell infiltration and organization into artery tertiary lymphoid organs in the aorta of large vessel giant cell arteritis. *Front Immunol.* 2019;10:83.
- Haacke EA**, van der Vegt B, Vissink A, Spijkervet FKL, Bootsma H, Kroese FGM. Germinal centers in diagnostic biopsies of patients with primary Sjögren's syndrome are not a risk factor for non-Hodgkin's lymphoma but a reflection of high disease activity: comment on the article by Sène et al. *Arthritis Rheumatol.* 2019;71:170-171.
- Mossel E, Delli K, Arends S, **Haacke EA**, van der Vegt B, van Nimwegen JF, Stel AJ, Spijkervet FKL, Vissink A, Kroese FGM, Bootsma H. Can ultrasound of the major salivary glands assess histopathological changes induced by treatment with rituximab in primary Sjögren's syndrome? *Ann Rheum Dis.* 2019;78:e27.
- Kroese FGM, **Haacke EA**, Bombardieri M. The role of salivary gland histopathology in primary Sjögren's syndrome: promises and pitfalls. *Clin Exp Rheumatol.* 2018;Suppl 112:222-233.Review.
- Verstappen GM, Nakshbandi U, Mossel E, **Haacke EA**, van der Vegt B, Vissink A, Bootsma H, Kroese FGM. Is the T follicular regulatory: follicular helper T cell ratio in blood a biomarker for ectopic lymphoid structure formation in Sjögren's syndrome? Comment on the article by Fonseca et al. *Arthritis Rheumatol.* 2018;70:1354-55.
- van Nimwegen JF, van Ginkel MS, Arends S, **Haacke EA**, van der Vegt B, Sillevius Smitt-Kamminga N, Spijkervet FKL, Kroese FGM, Stel AJ, Brouwer E, Vissink A, Bootsma H. Validation of the ACR-EULAR criteria for primary Sjögren's syndrome in a Dutch prospective diagnostic cohort. *Rheumatology.* 2018;57:818-25.
- Mossel E, Delli K, van Nimwegen JF, Stel AJ, **Haacke EA**, Kroese FGM, Spijkervet FKL, Vissink A, Arends S, Bootsma H. The parotid gland connection: ultrasound and biopsies in primary Sjögren's syndrome. *Ann Rheum Dis.* 2018;77:e38.
- Haacke EA**, van der Vegt B, Vissink A, Spijkervet FKL, Bootsma H, Kroese FGM. Standardisation of the detection of germinal centres in salivary gland biopsies of patients with primary Sjögren's syndrome is needed to assess their clinical relevance. *Ann Rheum Dis.* 2018;77:e32.
- Haacke EA**, van der Vegt B, Vissink A, Spijkervet FKL, Bootsma H, Kroese FGM. Germinal centres in

- diagnostic labial gland biopsies of patients with primary Sjögren's syndrome are not predictive for parotid MALT lymphoma development. *Ann Rheum Dis*. 2017;76:1781-84.
- Haacke EA**, Bootsma H, Spijkervet FK, Visser A, Vissink A, Kluin PM, Kroese FG. FcRL4⁺ B-cells in salivary glands of primary Sjögren's syndrome patients. *J Autoimmun*. 2017;81:90-98.
- Verstappen GM, Kroese FGM, Meinders PM, Corneth OB, Huitema MC, **Haacke EA**, Vegt van der B, Arends S, Vissink A, Bootsma H, Abdulahad WH. B-cell depletion therapy normalizes circulating follicular Th cells in Primary Sjögren's Syndrome. *Journal of Rheumatology* 2017;44:49-58.
- Fisher BA, Jonsson R, Daniels T, Bombardieri M, Brown RM, Morgan P, Bombardieri S, Ng WF, Tzioufas AG, Vitali C, Shirlaw P, **Haacke E**, Costa S, Bootsma H, Devauchelle-Pensec V, Radstake TR, Mariette X, Richards A, Stack R, Bowman S, Barone F, on behalf of the Sjogren's histopathology workshop group. Standardisation of labial gland histopathology in clinical trials in primary Sjögren's syndrome. *Ann Rheum Dis*. 2017;76:1161-68.
- Haacke EA**, van der Vegt B, Meiners PM, Vissink A, Spijkervet FKL, Bootsma H, Kroese FG. Abatacept treatment in p Sjögren's syndrome results in a decrease of germinal centers in salivary gland biopsies. *Clin Exp Rheum*. 2017;35:317-20.
- Delli K, **Haacke EA**, Ihrler S, van der Vegt B, Vissink A, Bootsma H, Spijkervet FK, Kroese FG. Need for consensus guidelines to standardise the assessment of germinal centres and other histopathological parameters in salivary gland tissue of patients with primary Sjögren's syndrome. *Ann Rheum Dis*. 2016;75:e32.
- Delli K, **Haacke EA**, Kroese FG, Pollard RP, Ihrler S, van der Vegt B, Vissink A, Bootsma H, Spijkervet FK. In primary Sjögren's syndrome high absolute numbers and proportions of B cells in parotid glands predict responsiveness to rituximab as defined by ESSDAI, but not by SSRI. *Ann Rheum Dis*. 2016;75:e34.
- Haacke EA**, Delli K, Kroese FGM, Pollard RP, Ihrler S, van der Vegt B, Vissink A, Bootsma H, Spijkervet FKL. Towards personalized treatment in primary Sjögren's syndrome: baseline parotid histopathology predicts responsiveness to rituximab treatment. *Ann Rheum Dis*. 2016;75:1933-38.
- Spijkervet FKL, **Haacke EA**, Kroese FGM, Bootsma H, Vissink A. Parotid gland biopsy, the alternative way to diagnose Sjögren Syndrome. *Rheum Dis Clin N Am*. 2016;42:485-99.
- HR Bouma, H Bootsma, JF van Nimwegen, **EA Haacke**, FKL Spijkervet, A Vissink, FGM Kroese. Sjögren's syndrome in the elderly. *Curr Aging Sci*. 2015;8:202-13. Review.
- Kroese FG, Abdulahad WH, **Haacke E**, Bos NA, Vissink A, Bootsma H. B-cell hyperactivity in primary Sjögren's syndrome. *Expert Rev Clin Immunol*. 2014 Apr;10:483-99.
- Hamza N, Bootsma H, Yuvaraj S, Spijkervet FK, **Haacke EA**, Pollard RP, Visser A, Vissink A, Kallenberg CG, Kroese FG, Bos NA. Persistence of immunoglobulin-producing cells in parotid salivary glands of patients with primary Sjögren's syndrome after B cell depletion therapy. *Ann Rheum Dis*. 2012;71:1881-87.

